



Turun yliopisto
University of Turku

SAFETY AND OUTCOME OF CORONARY INTERVENTIONS WITH SPECIAL REFERENCE TO ANTICOAGULATION AND STENT TYPE

Antti-Pekka Annala

University of Turku

Faculty of Medicine
Department of Cardiology and Cardiovascular Medicine
Doctoral Programme of Clinical Investigation
Heart Center, Turku University Hospital, Turku, Finland

Division of Internal Medicine, Department of Cardiology, Seinäjoki Central Hospital, Seinäjoki, Finland
Heart Center, Satakunta Central Hospital, Pori, Finland

Supervised by

Professor Juhani Airaksinen, MD, PhD
Heart Center, Turku University Hospital
University of Turku
Turku, Finland

Docent Pasi Karjalainen
Heart Center
Satakunta Central Hospital
Pori, Finland

Reviewed by

Docent Kari Ylitalo
Department of Cardiology
Oulu University Hospital and
University of Oulu
Oulu, Finland

Docent Olli Anttonen
Department of Medicine
Päijät-Häme Central Hospital
Lahti, Finland

Opponent

Professor Kjell Nikus, MD, PhD
School of Medicine
University of Tampere
Tampere, Finland

The originality of this thesis has been checked in accordance with the University of Turku quality assurance system using the Turnitin OriginalityCheck service.

ISBN 978-951-29-6248-8 (PRINT)

ISBN 978-951-29-6249-5 (PDF)

ISSN 0355-9483

Painosalama Oy - Turku, Finland 2015

To my family

ABSTRACT

Antti-Pekka Annala

SAFETY AND OUTCOME OF CORONARY INTERVENTIONS WITH SPECIAL REFERENCE TO ANTICOAGULATION AND STENT TYPE

University of Turku, Faculty of Medicine, Department of Cardiology and Cardiovascular Medicine, Doctoral Programme of Clinical Investigation, Heart Center, Turku University Hospital, Turku, Finland. Division of Internal Medicine, Department of Cardiology, Seinäjoki Central Hospital, Seinäjoki, Finland. Heart Center, Satakunta Central Hospital, Pori, Finland. *Annales Universitatis Turkuensis, Painosalama Oy, Turku, Finland 2015.*

Antithrombotic therapy during and after coronary procedures always entails the challenging establishment of a balance between bleeding and thrombotic complications. It has been generally recommended to patients on long-term warfarin therapy to discontinue warfarin a few days prior to elective coronary angiography or intervention to prevent bleeding complications. Bridging therapy with heparin is recommended for patients at an increased risk of thromboembolism who require the interruption of anticoagulation for elective surgery or an invasive procedure. In study I, consecutive patients on warfarin therapy referred for diagnostic coronary angiography were compared to control patients with a similar disease presentation without warfarin. The strategy of performing coronary angiography during uninterrupted therapeutic warfarin anticoagulation appeared to be a relatively safe alternative to bridging therapy, if the international normalized ratio level was not on a supratherapeutic level.

In-stent restenosis remains an important reason for failure of long-term success after a percutaneous coronary intervention (PCI). Drug-eluting stents (DES) reduce the problem of restenosis inherent to bare metal stents (BMS). However, a longer delay in arterial healing may extend the risk of stent thrombosis (ST) far beyond 30 days after the DES implantation. Early discontinuation of antiplatelet therapy has been the most important predisposing factor for ST. In study II, patients on long-term oral anticoagulant (OAC) underwent DES or BMS stenting with a median of 3.5 years' follow-up. The selective use of DESs with a short triple therapy seemed to be safe in OAC patients, since late STs were rare even without long clopidogrel treatment. Major bleeding and cardiac events were common in this patient group irrespective of stent type.

In order to help to predict the bleeding risk in patients on OAC, several different bleeding risk scorings have been developed. Risk scoring systems have also been used also in the setting of patients undergoing a PCI. In study III, the predictive value of an outpatient bleeding risk index (OBRI) to identify patients at high risk of bleeding was analysed. The bleeding risk seemed not to modify periprocedural or long-term treatment choices in patients on OAC after a percutaneous coronary intervention. Patients with a high OBRI often had major bleeding episodes, and the OBRI may be suitable for risk evaluation in this patient group.

Optical coherence tomography (OCT) is a novel technology for imaging intravascular coronary arteries. OCT is a light-based imaging modality that enables a 12–18 μm tissue axial resolution to visualize plaques in the vessel, possible dissections and thrombi as well as, stent strut appositions and coverage, and to measure the vessel lumen and lesions. In study IV, 30 days after titanium-nitride-oxide (TITANOX)-coated stent implantation, the binary stent strut coverage was satisfactory and the prevalence of malapposed struts was low as evaluated by OCT.

Long-term clinical events in patients treated with (TITANOX)-coated bio-active stents (BAS) and paclitaxel-eluting stents (PES) in routine clinical practice were examined in study V. At the 3-year follow-up, BAS resulted in better long-term outcome when compared with PES with an infrequent need for target vessel revascularization.

Keywords: anticoagulation, restenosis, thrombosis, bleeding, optical coherence tomography, titanium

TIIVISTELMÄ

Antti-Pekka Annala

SEPELVALTIMOIDEN PALLOLAAJENNUSHOIDON TURVALLISUUSJATULOKSET VERENOHENNUSHOIDON AIKANA JA ERI STENTTITYYPEILLÄ

Sydänkeskus, Turun yliopistollinen keskussairaala, Kardiologia ja kardiovaskulaarilääketiede, Kliininen Tohtoriohjelma, Turun yliopisto. Sisätautien yksikkö, Sydänosasto, Seinäjoen keskussairaala, Seinäjoki. Sydänkeskus, Satakunnan keskussairaala, Pori. *Annales Universitatis Turkuensis*, Painosalama Oy, Turku, Finland 2015.

Hyytymisenestolääkkeiden käyttö sepelvaltimotoimenpiteiden yhteydessä ja niiden jälkeen on haastavaa tasapainottelua vuotojen ja hyytymien aiheuttamien komplikaatioiden välillä. Aikaisemmin on suositeltu verenhennushoidon lopettamista muutama päivä ennen suunniteltua sepelvaltimotoimenpidettä. Potilailla, joilla on korkea tukosriski, on suositeltu hepariinin käyttöä ns. siltahoitona verenhennuslääkehoidon tauon aikana. Tutkimuksessa todettiin, että sepelvaltimoiden varjoainekuvaus voidaan tehdä varsin turvallisesti ilman hepariini siltahoitoa keskeytymättömän verenhennushoidon aikana, jos verenhennustaso on suositellulla hoitoalueella.

Lääkeainestenteillä on pystytty vähentämään metallistenteille yleistä suonen uudelleenahautumista sepelvaltimon pallolaaennuksella hoidetussa kohdassa. Lääkeaineen hidastaessa stentatun suonen alueen parantumista riski hyytymän kehittymiseen lääkeverkon sisälle on suurentunut, ja riski voi jatkua merkittävästi kauemmin kuin 30 vuorokautta. Tehokkaalla hyytymisenestolääkityksellä pyritään estämään stentinsisäisten hyytymien kehittyminen. Aikainen hyytymisenestolääkityksen lopettaminen on todettu tämän ongelman merkittävimmäksi riskitekijäksi. Tutkimuksessa osoitettiin verenhennuspotilailla 3,5 vuoden seurannassa vähän myöhäisiä stentitrombeja, vaikka käytettiin lääkeainestenttejä ja lyhyttä klopidogreelihoitoa hyytymien estossa. Kuitenkin pallolaaennetuilla verenhennuspotilailla todettiin paljon verenvuoto – ja muita komplikaatioita.

Lukuisia pisteytyksiä on kehitetty verenhennuspotilaan vuotoriskin arvioimiseksi. Samoja pisteytyksiä on käytetty myös pallolaaennuspotilaan vuotoriskin arviointiin. Tutkimuksessa tarkasteltiin outpatient bleeding risk index (OBRI) -pisteytyksen kykyä löytää korkean vuotoriskin pallolaaennuspotilaat. Korkeat OBRI-pisteet saaneilla potilailla esiintyi enemmän vuotoja, mikä viittaa OBRI-pisteytyksen käyttökelpoisuuteen tässä potilasjoukossa.

Valokerroskuvaus on uusi tekniikka, jolla voidaan kuvata sepelvaltimoa suonen sisältä. Valokerroskuvauksella voidaan erottaa kudoksia 12–18 mikrometrin tarkkuudella. Sillä kuvautuvat hyvin suonen sisäpinnan plakit, mahdolliset seinämän repeämät ja hyytymät sekä stentin asettuminen suonen seinämää vasten ja stentin peittyminen suonen parantuessa. Myös suonen koon ja kohteiden tarkka mittaus on mahdollista. Titaani-typppioksidilla (TITANOX) päällystettyjen stenttien todettiin valokerroskuvauksella arvioituna pääsääntöisesti peittyneen kudoksella jo 30 vuorokauden kuluttua pallolaaennuksesta. Myös stentin asettuminen suonen seinämään oli hyvä.

Tutkimuksessa todettiin kolmen vuoden seurannassa TITANOX-päällysteisellä stentillä hoidetuilla potilailla merkittävästi vähemmän sydänkomplikaatioita paklitakseli-päällysteisillä lääkestenteillä hoidettuihin potilaisiin verrattuna. Uusintatoimenpiteitä tarvittiin enemmän lääkestenteillä hoidetuilla potilailla.

Avainsanat: antikoagulaatio, restenoosi, tromboosi, verenvuoto valokerroskuvaus, titaani

TABLE OF CONTENTS

ABBREVIATIONS	9
LIST OF ORIGINAL PUBLICATIONS	10
1. INTRODUCTION	11
2. REVIEW OF THE LITERATURE.....	14
2.1 Techniques of coronary angiography and percutaneous coronary intervention ...	14
2.1.1 Access site	14
2.1.2 Percutaneous coronary intervention	15
2.1.2.1 Percutaneous transluminal coronary angioplasty.....	15
2.1.2.2 Stenting	15
2.1.2.3 Other techniques	16
2.2 Coronary artery stents.....	18
2.2.1 Bare metal stent.....	18
2.2.2 Bioactive stents	18
2.2.3 Drug eluting stents	20
2.2.3.1 First-generation DESs.....	20
2.2.3.2 Second-generation durable polymer DESs	20
2.2.3.3 DESs with a biodegradable polymer.....	22
2.2.3.4 DESs with no polymer	23
2.2.4 Bioabsorbable stents.....	23
2.2.5 Other stent designs	24
2.3 Antithrombotic therapy during a percutaneous coronary intervention.....	25
2.3.1 Acetylsalicylic acid.....	25
2.3.2 Thienopyridine derivatives.....	26
2.3.2.1 Clopidogrel	26
2.3.2.2 Prasugrel	27
2.3.2.3 Ticagrelor.....	28
2.3.3 Unfractionated heparin.....	29
2.3.4 Low-molecular-weight heparin	29
2.3.5 Glycoprotein IIb/IIIa inhibitors.....	30
2.3.6 Direct thrombin inhibitors.....	30
2.4 Complications of percutaneous coronary intervention.....	31
2.4.1 Restenosis.....	31
2.4.1.1 Treatment of restenosis	33
2.4.2 Stent thrombosis.....	34
2.4.2.1 Risk factors of stent thrombosis	35
2.4.2.2 Stent thrombosis with different stents.....	35
2.4.3 Bleeding complications	36

2.4.3.1 Bleeding risk index	37
2.4.4 Other complications	38
2.5 Coronary angiography and percutaneous coronary intervention during long-term anticoagulation therapy.....	38
2.5.1 Uninterrupted vs interrupted anticoagulation.....	38
2.5.2 Management of long-term anticoagulation therapy after percutaneous coronary intervention	40
2.5.3 Novel anticoagulants	41
2.6 Optical coherence tomography.....	42
2.6.1 Technique	42
2.6.2 OCT versus IVUS	42
2.6.3 Use in clinical practice	43
2.6.4 Vascular healing in OCT	44
3. AIMS OF THE STUDY.....	45
4. MATERIALS AND METHODS.....	46
4.1 Study design and subjects.....	46
4.2 Methods	47
4.2.1 Coronary angiography and percutaneous coronary intervention	47
4.2.2 Outpatient bleeding risk index	47
4.2.3 OCT.....	47
4.2.4 End point definitions	48
4.2.5 Clinical data and follow-up.....	49
4.2.6 Statistical analyses.....	50
5. RESULTS.....	53
5.1 The safety and feasibility of diagnostic coronary angiography during uninterrupted warfarin therapy (I)	53
5.2 The long-term safety of drug-eluting stents and bare metal stents in patients on warfarin treatment (II).....	54
5.3 The value of an outpatient bleeding risk index (OBRI) in predicting bleeding events and prognosis during long-term follow-up after PCI and the impact of OBRI on treatment choices (III).....	55
5.4 The extent of neointimal coverage of stent struts by optical coherence tomography (OCT) at 30 days following the implantation of BASs in an unselected non-diabetic population (IV)	57
5.5 Long-term clinical outcome in patients treated with titanium-nitride- oxide-coated stents and paclitaxel-eluting stents (V).....	57
6. DISCUSSION	60
6.1 The safety and feasibility of diagnostic coronary angiography during uninterrupted warfarin therapy (I).....	60

6.2 Comparison of the long-term safety of drug-eluting stents and bare metal stents in patients on warfarin treatment (II).....	61
6.3 The value of an outpatient bleeding risk index (OBRI) in predicting bleeding events and prognosis during long-term follow-up after PCI and its influence on contemporary treatment choices (III).....	63
6.4 The neointimal coverage of stent struts following the implantation of BASs (IV).....	64
6.5 Long-term clinical outcome in patients treated with titanium-nitride-oxide-coated stents and paclitaxel-eluting stents (V).....	65
6.6 Possible limitations of the study.....	66
7. CONCLUSION	67
8. ACKNOWLEDGEMENTS	68
9. REFERENCES	69
ORIGINAL PUBLICATIONS.....	85

ABBREVIATIONS

AC	anticoagulation
ACS	acute coronary syndrome
AF	atrial fibrillation
BAS	bio-active stent
BMS	bare metal stent
BT	bridging therapy
CABG	coronary artery bypass grafting
DAPT	dual antiplatelet therapy
DEB	drug-eluting balloon
DES	drug-eluting stent
EES	everolimus-eluting stent
GP	glycoprotein
INR	international normalized ratio
ISR	in-stent restenosis
IVUS	intravascular ultrasound
LMWH	low-molecular-weight heparin
LST	late stent thrombosis
MACCE	major adverse cardiac and cerebrovascular event
MACE	major adverse cardiac event
MI	myocardial infarction
NIH	neointimal hyperplasia
NSTEMI	non-ST-elevation myocardial infarction
NOAC	novel oral anticoagulant
OAC	oral anticoagulation
OCT	optical coherence tomography
OBRI	outpatient bleeding risk index
PCI	percutaneous coronary intervention
PES	paclitaxel-eluting stent
PTCA	percutaneous transluminal coronary angioplasty
SES	sirolimus-eluting stent
ST	stent thrombosis
STEMI	ST-elevation myocardial infarction
TITANOX	titanium nitride oxide
TLR	target lesion revascularization
TVR	target vessel revascularization
UAC	uninterrupted anticoagulation
UFH	unfractionated heparin

LIST OF ORIGINAL PUBLICATIONS

This thesis is based on the following original publications, which are referred to in the text by their Roman numerals.

- I. Annala Antti-Pekka, Karjalainen Pasi P, Porela Pekka, Nyman Kai, Ylitalo Antti, Airaksinen KE Juhani. Safety of diagnostic coronary angiography during uninterrupted therapeutic warfarin treatment. *Am J Cardiol* 2008;102(4):386-90.
- II. Antti-Pekka Annala, Pasi P. Karjalainen, Fausto Biancari, Matti Niemelä, Antti Ylitalo, Saira Vikman, Pekka Porela, K.E. Juhani Airaksinen. Long-term safety of drug-eluting stents in patients on warfarin treatment. *Ann Med* 2012; 44:271-278.
- III. K.E. Juhani Airaksinen, Hanna Suurmunne, Pekka Porela, Matti Niemelä, Saira Vikman, Marja Puurunen, Antti-Pekka Annala, Fausto Biancari, Pasi P. Karjalainen. Usefulness of Outpatient Bleeding Risk Index to Predict Bleeding Complications in Patients With Long-term Oral Anticoagulation Undergoing Coronary Stenting. *Am J Cardiol* 2010; 106:106-179.
- IV. Antti-Pekka Annala, Tuomas Lehtinen, Tuomas O. Kiviniemi, Antti Ylitalo, Wail Nammas, Pasi P. Karjalainen. Vascular Healing Early After Titanium-Nitride-Oxide-Coated Stent Implantation Assessed by Optical Coherence Tomography. *J Invasive Cardiol* 2013; 25(4):186-189.
- V. Pasi P. Karjalainen, Antti-Pekka Annala, Antti Ylitalo, Tero Vahlberg, K.E. Juhani Airaksinen. Long-Term clinical outcome with titanium-nitride-oxide-coated stents and paclitaxel-eluting stents for coronary revascularization in an unselected population. *Int J Cardiol* 2010; 144(1):42-6.

The original communications have been reproduced with the permission of the copyright holders.

1. INTRODUCTION

A sense of “strangling and anxiety” in the chest was termed by Heberden as “angina pectoris” as early as in 1772 (Grech 2003a). Most often, the aetiology for this common syndrome is atheromatous coronary artery disease. The majority of coronary artery disease patients manage with noninvasive therapy including good medical treatment and life style changes. The invasive strategy of treating coronary artery disease consists of two possibilities, coronary artery bypass grafting (CABG) performed by cardiac surgeons or catheter-attached devices implanted by cardiologists - or, in some cases, both strategies combined. The first CABG was performed in 1964 (Head et al. 2013). Although Dotter and Judkins first proposed prosthetic devices to maintain the luminal integrity as early as in 1964 (Dotter et al. 1964), percutaneous transluminal coronary angioplasty (PTCA) or “balloon angioplasty” was introduced for the first time by a Swiss radiologist, Andreas Grüntzig in 1977 (Grüntzig et al. 1979).

An acute vessel closure is a common complication (6.8%-13.6%) after balloon angioplasty (Cowley et al. 1984). It is caused by thrombus formation, a coronary spasm or medial dissection of the coronary artery wall (Sutton et al. 1994). More aggressive antithrombotic therapy and implantation of an intracoronary stent to move intimal and medial flaps away from the lumen and to prevent elastic recoil diminished the rate of abrupt vessel closure markedly (Colombo et al. 1995). In 1987, the first clinical report on coronary artery stenting was published by Sigwart and colleagues (Sigwart et al. 1987). In the early-stent era, stents were predominantly used as so-called bailout devices for emergency vessel closure (Serruys et al. 1993). The expanded use of stents in routine elective coronary interventions raised the need for repeated revascularizations driven by in-stent restenosis (ISR). An angiographic ISR rate of 5%-35% after bare metal stent (BMS) implantation was reported (Stone et al. 2005). In order to reduce the ISR, active polymer-coated stents that eluted pharmacological agents directly into the vessel wall were developed. In the first-generation drug-eluting stents (DES), a stainless steel platform stent was coated with a mixture of sirolimus (Cypher®) or paclitaxel (Taxus®) agent and a durable polymer. The performance of these DESs in reducing the incidence of restenosis and, hence, also repeat revascularizations was shown in numerous studies (Morice et al. 2002, Moses et al. 2003, Schofer et al. 2003, Schampaert et al. 2004, Ardissino et al. 2004, Grube et al. 2003, Colombo et al. 2003, Tanabe et al. 2003, Stone et al. 2004b, Dawkins et al. 2005). However, the incidence of late and very late definite stent thrombosis (ST) appeared increased (Virmani et al. 2004), and they were associated with the discontinuation of clopidogrel therapy (Jensen et al. 2007). Incomplete neointimal coverage, the lack of a functioning endothelium and hypersensitivity reactions from the polymer were thought to increase the risk of late ST (Daemen et al. 2007, Nakazawa et al. 2008, Joner et al. 2006). The safety concern related to the first-generation DESs led the industry to develop second-generation DESs with bio-compatible and biodegradable polymers. Several studies have shown the superiority of newer-generation DESs over

first-generation DESs in regard to safety issues, with comparable efficacy in reducing ISR (Räber et al. 2011). Completely absorbable stents, bioresorbable vascular scaffolds, have the potential advantage of reducing chronic inflammation in the vessel wall as well as improved vasomotion and adaptive shear stress (Patel et al. 2013). Both bioabsorbable stent types, drug-eluting and with no drug have been developed. The long-term results of bioresorbable scaffolds will be shown in the near future.

Some studies have suggested that titanium features better biocompatibility when compared with stainless steel, carbon, gold or other surface-coating materials. Titanium offers low toxic ion release, which might reduce tissue reaction and inflammation (Steinemann 1996 and 1998). The safety of the titanium-nitride-oxide (TITANOX)-coated stent has been shown in several reports on real-life unselected populations (Moschovitis et al. 2010, Karjalainen et al. 2006, Mosseri et al. 2005 and 2006), as well as in the challenging subgroup of patients with diabetes and acute myocardial infarction (Valdés et al. 2012, Karjalainen et al. 2012, Tuomainen et al. 2013). The aim of the TITANOX-coated stent work in the current thesis was to compare the long-term outcomes in patients with TITANOX-coated bio-active stents (BAS) and paclitaxel-eluting stents (PES) in routine clinical practice.

Antithrombotic therapy in coronary artery disease patients during and after coronary procedures always entails a balancing between bleeding and thrombotic complications. It is especially challenging in patients with acute coronary syndrome (ACS) when potent antithrombotic drugs are needed, or in patients with a high risk of bleeding. More than 5% of patients undergoing a percutaneous coronary intervention (PCI) are estimated to be on long-term oral anticoagulation (OAC) therapy because of other underlying medical conditions such as atrial fibrillation (AF), mechanical valves and a recent or recurrent history of deep venous thrombosis or pulmonary embolism (Helft et al. 2006). It has been generally recommended to patients on long-term warfarin therapy to discontinue warfarin a few days prior to elective coronary angiography or intervention to prevent bleeding complications (Popma et al. 2001). Bridging therapy with heparin is recommended for patients at an increased risk of thromboembolism who require the interruption of anticoagulation for elective surgery or an invasive procedure (Airaksinen et al. 2010a). In order to facilitate the prediction of the bleeding risk in patients on OAC, several different bleeding risk scorings have been developed. Risk scoring systems have also been used in the setting of patients undergoing a PCI. In the current thesis, the aims of the studies on patients on long-term OAC and undergoing coronary procedures were to examine the safety of the uninterrupted oral anticoagulation (UAC) strategy in coronary angiography, and to evaluate the performance of the outpatient bleeding risk index (OBRI)-scoring in predicting bleeding complications in PCIs performed on patients on OAC. Furthermore, one aim was to study the long-term safety of a short triple therapy (warfarin, aspirin and clopidogrel) after DES implantation in OAC patients. At the time when the current thesis was being planned, novel oral anticoagulants were not

in routine use and the focus of the thesis is therefore on warfarin treatment and coronary interventions.

Optical coherence tomography (OCT) is a technology originally used in ophthalmology. In cardiology, it is a novel technology for imaging intravascular coronary arteries. OCT is a light-based imaging modality that provides an axial resolution of 12-18 μm , as opposed to the 150-200 μm achieved with intravascular ultrasound (IVUS) (Lowe et al. 2011). This unique tissue axial resolution enables the precise measurement of the vessel lumen and lesions, in addition to the visualization of plaques in the vessel as well as possible dissections and thrombi and evaluation of stent strut apposition and coverage. By assessing the incomplete neointimal coverage of the stent struts, the risk of ST can be estimated indirectly. At the time when the study on OCT after TITANOX-coated stent implantation included in the current thesis was being carried out, there was scarce, if any, data available concerning early findings after stent implantation using OCT.

2. REVIEW OF THE LITERATURE

2.1 Techniques of coronary angiography and percutaneous coronary intervention

2.1.1 Access site

The femoral artery access has been the standard for coronary angiography and PCI for decades. Major complications of transfemoral coronary angiography and PCI are haematoma, retroperitoneal haemorrhage, pseudoaneurysm, arterio-venous fistulae, arterial dissections, vessel rupture, infection, embolism and thrombosis (Samal et al. 2002). The transradial approach for coronary interventions was first introduced in 1995 (Kiemeneij et al. 1995). A learning curve exists for the radial approach, and this can affect procedure time and radiation dose, trending toward higher rates of procedural failures as demonstrated in some studies (Jolly et al. 2009). In a study of PCI and coronary angiography patients, body mass index, a history of CABG as well as the number of treated lesions and chronic total occlusions were associated with the highest patient radiation exposure, but the radial access site was associated comparable radiation exposure to that of the femoral approach (Delewi R et al. 2013).

Some earlier studies have found an unfavourable influence on neurologic complications associated with a transradial access for PCI (Hamon et al. 2008). In a large retrospective analysis by Ratib et al, the use of radial access for PCI was not associated with an increased risk of clinically detected neurologic complications (Ratib et al. 2013). In a meta-analysis of twelve randomized controlled trials with patients presenting with an ST-segment elevation myocardial infarction and undergoing primary PCI, the radial approach, in comparison to the femoral approach, was associated with a decreased risk of mortality and major bleeding, with a similar stroke risk (Karrowni et al. 2013). The most common complication of transradial access is asymptomatic artery occlusion, which rarely leads to clinical events due to the collateral perfusion of the hand. A forearm haematoma can cause compartment syndrome. Radial artery pseudoaneurysm, arteriovenous fistulae and nerve injury are rarely reported complications (Kanei et al. 2011). Coronary stenting with the radial approach has reportedly reduced the total hospital costs and yielded financial savings (Mann et al. 1998). However, the number of interventionists using transradial procedures has been limited in some countries, such as the United States (Rao et al. 2008).

The brachial artery is an alternative access site for coronary angiography and PCI. More frequent major access site complications have been reported after transbrachial and transfemoral PCI when compared to transradial PCI (Kiemeneij et al. 1997). When ipsilateral radial access is not available, catheterization using transulnar approach can also be considered (Kedev et al. 2013).

In the early years, when a femoral approach was chosen, manual or mechanical compression was needed to achieve haemostasis after femoral sheath removal. The patient needed to remain immobilized for up to 8 hours after a catheterization. The first vascular closure devices were introduced approximately 20 years ago. The various closure devices include sutures, sealants, clips and compression mechanisms (Tavris et al. 2012). Serious adverse events, including deaths, have been reported in association with the use of vascular closure devices. However, in a large registry study, better safety profiles were demonstrated for most of the frequently used vascular closure devices when compared to manual compression controls (Tavris et al. 2012).

2.1.2 Percutaneous coronary intervention

2.1.2.1 Percutaneous transluminal coronary angioplasty

Compared to modern standards, the early-era procedures and equipment of PTCA were bulky, and large guide catheters and balloon catheters easily traumatized the vessels. No guidewires were used. Only non-calcific, proximal, non-complex lesions could be treated, and PTCA was feasible in only 10% of all patients needing revascularization. By the mid-1980s, soft-tipped guide catheters, steerable guidewires, lower-profile balloon catheters with an increased tolerance to high inflation pressures, and the interventionists' improved experience enabled the treatment of more complex lesions in more acute situations (Grech 2003a). Because of need for repeated revascularization caused by acute vascular closure and a high rate of restenosis after a balloon angioplasty, the current European guideline recommends a balloon angioplasty only as a revascularization option when the implantation of a stent is technically not achievable, if the vessel is too small to be stented (<2.0 mm) or if the patient has critical stenosis but needs urgent surgery (Windecker et al. 2014).

2.1.2.2 Stenting

The introduction of intracoronary stents revolutionized the practice of interventional cardiology. The first clinical report on coronary artery stenting was published in 1987 (Sigwart et al. 1987). The first indication the U.S. Food and Drug Administration approved for the coronary stent was the emergency management of abrupt vessel closure in 1992. In the early-stent era, stents were predominantly used as so-called bailout devices for acute vessel closure (Serruys et al. 1993). The reports of the superiority of stenting over PTCA alone, reducing restenosis, repeated angioplasties and the need for emergency CABG, expanded the indications for elective stent deployment (Brophy et al. 2003, Serruys et al. 2004). However, stenting was not found to decrease the rates of death and MI when compared to PTCA (Al Suwaidi et al. 2004). To avoid ST, aggressive anticoagulation was used, which caused frequent arterial access site complications and major systemic bleeding. The development of new powerful antiplatelet drugs partly overcame this problem (Grech 2003a). The unacceptably high rate of restenosis after bare

metal stent (BMS) implantation led to the development of drug-eluting stents (DES). A great concern arose regarding the ST risk related to the first-generation DESs. The new-generation DESs with different pharmacological agents developed with a biodegradable polymer or polymer-free system appear to have further advanced the efficacy and safety in comparison to early-generation DESs and BMSs, including patients with diabetes, multivessel and left main disease, acute myocardial infarction, saphenous vein graft and restenotic lesions as well as chronic total occlusions. Current guidelines recommend the consideration of using the new-generation DESs in all clinical conditions and lesion subsets (Windecker et al. 2014).

2.1.2.3 Other techniques

The stent deployment to atherosclerotic plaques can be challenging, and lesion preparation with plaque modification is suggested. The cutting balloon is a specialized device initially developed in the pre-stent era to create a discrete longitudinal incision in the atherosclerotic target coronary segment. The cutting balloon has demonstrated no difference compared to a conventional balloon in terms of acute or long-term outcomes in randomized trials (Mauri et al. 2002). However, the cutting balloon is an alternative tool for complex lesion preparation before stenting, and for angioplasty in patients with in-stent restenosis (ISR) (Auer et al. 2003).

Another debulking technique, percutaneous coronary rotational atherectomy, was developed in the late 1980s. Percutaneous coronary rotational atherectomy increases the luminal diameter by debulking atherosclerotic plaques with the aid of an abrasive diamond-coated burr. It is used before stenting for patients with severely calcified lesions, undilatable lesions, chronic total occlusions and bifurcation lesions (Cavusoglu et al. 2004). The long-term benefits of percutaneous coronary rotational atherectomy have been questioned in several studies (Dill et al. 2000, Buchbinder et al. 2000, vom Dahl et al. 2002). However, the high risk of ISR has been largely eliminated by the use of DESs, and a reasonable procedural success rate and long-term outcome were achieved in a recent rota-DES study (Chiang MH et al. 2013).

Orbital atherectomy is a novel treatment option for debulking coronary plaques that has been in clinical use in connection with peripheral artery diseases for a few years. The orbital atherectomy device allows continuous blood flow through the lesion and creates smaller particle sizes than rotational atherectomy. In the ORBIT I trial with 50 patients, orbital atherectomy was associated with good procedural success and resulted in a low cumulative major adverse cardiac event (MACE) rate at 6 months (Parikh K et al. 2013).

Drug eluting balloons (DEB) are paclitaxel-coated balloons. The treatment of ISR is associated with a lower risk of MACE when compared to plain balloon angioplasty or the implantation of a Taxus liberte drug-eluting stent (Indermuehle et al. 2013). The benefit of using a DEB for de novo coronary lesions remains unclear. Some studies have found no superiority to current standard therapies stenting with BMS or DES (Fröhlich et al.

2013). In the setting of ST-elevation myocardial infarction (STEMI), DEB followed by BMS implantation showed angiographic inferiority to BMS or DES implantation after 6-month follow-up (Belkacemi et al. 2012). However, DEB for de novo lesions may be considered in patients with contraindications for a DES - for instance a high risk for of bleeding if long-term antithrombotic therapy is needed (Fröhlich et al. 2013).

Fractional flow reserve, coronary flow reserve, intravascular ultrasound (IVUS) and OCT are adjunctive diagnostic techniques in PCI. The fractional flow reserve is the current standard measurement for functionally evaluating the severity of borderline lesions (Windecker et al. 2014), including 40%-70% ISR seen in coronary angiography (Bech et al. 2001, Lopez-Palop et al. 2004, Hannawi et al. 2014). Epicardial and microvascular resistance is evaluated with coronary flow reserve, which in turns helps to determine the haemodynamic significance of coronary stenosis (Meuwissen et al. 2002, Kiviniemi 2008, Johnson NP et al. 2012). IVUS and a novel intravascular imaging modality, OCT, provide extended arterial wall imaging. They are important tools in estimating the severity of disease and therapy, including stent implantation (Shiele et al. 2003, Bezerra et al. 2009).

Numerous therapeutic devices in interventional cardiology have been invented to improve thrombus removal from the coronary in patients with ST-elevation myocardial infarction. Several mechanical thrombectomy devices have been developed, and their use during a PCI for STEMI seemed to yield benefit in the reduction of re-MIs and stroke (Navarese et al. 2013). In one study, thrombus aspiration during a primary PCI was associated with a significant reduction in mortality, especially in those with a short total ischaemic time (Noman et al. 2012). Furthermore, in the TAPAS study, thrombus aspiration before stenting seemed to improve the 1-year clinical outcome after a PCI for STEMI patients (Vlaar et al. 2008). However, in the recent large studies, routine manual thrombectomy did not reduce mortality as compared with PCI alone (Lagerqvist et al. 2014, Jolly et al. 2015).

The use of embolic distal protection devices during a PCI of saphenous vein grafts seems to reduce the rate of adverse events (Baim et al. 2002, Mauri et al. 2007). However, distal protection devices exhibit some challenges if the stenosis is located close to the distal anastomoses, for instance. Moreover, in up to a third of the cases, a transient impairment of epicardial flow after stenting is seen. Sometimes, in the case of unstable lesions, filter crossing of thrombotic lesions embolizes itself (Giampaolo et al. 2013). Current guidelines support the use of distal protection devices during a PCI of a saphenous vein graft when technically feasible (class I, level of evidence B) (Wijns et al. 2010).

Excimer laser coronary angioplasty has been used for coronary interventions for more than 20 years. The Spectranetics CVX-300 (Spectranetics, Colorado Springs, CO) Excimer laser coronary angioplasty system is composed of an excimer laser generator and pulsed xenon-chlorine laser catheters capable of delivering excimer energy, that has a lytic effect on the thrombus, in addition to its debulking effect on the atherosclerotic plaque beneath the thrombus (Shishikura et al. 2013). All available randomized trials

testing excimer laser coronary angioplasty versus balloon angioplasty have failed to demonstrate the superiority of a laser system in complex lesions, and it still has little role in present-day interventional cardiology (Badr et al. 2013).

2.2 Coronary artery stents

2.2.1 Bare metal stent

In 1993, the Palmaz-Schatz stent was approved by the United States Food and Drug Administration for the prevention of coronary restenosis after PTCA in selected patients. The BENESTENT study and the STRESS study showed the superiority of coronary stenting over PTCA in preventing restenosis and the need for revascularization (Serruys et al. 1994, Fischman et al. 1994), and the expansion of stenting began. However, the studies could not demonstrate any differences in the rates of death and MI between the stent groups and the balloon angioplasty group.

The first-generation bare metal stent, the PALMAZ-SCHATZ stent (Johnson and Johnson Interventional Systems, Warren, N.J.) was made of stainless steel and bulky and stiff struts, and the metal-to-artery ratio was high. Cobalt chromium (CoCr) appears to be more biocompatible material than stainless steel, and it has better radial strength (Sketch et al. 2005). This made it possible to manufacture stents with thinner struts with similar radiological visibility but easier deliverability to the lesion site in the coronary (Kereiakes et al. 2003). Strut thickness and the development of stent geometry and surface material have been shown to influence the restenosis rate with BMSs (Garasic et al. 2000, Babapulle et al. 2002).

2.2.2 Bioactive stents

The metals that have been used for various biomedical applications are titanium, 316 stainless steel, titanium oxide, titanium nitride, cobalt-chromium alloy and nitinol alloys (Huang et al. 2003, Shah et al. 1999). Stainless steel is used successfully in many biomedical applications. However, it has become corroded and releases Cr, Ni, Mn and Mo ions when the metal is placed in coronary vessels (Gutensohn et al. 2000). It is estimated that 5%–15% of the population are allergenic to nickel, chromium or molybdenum, which is a possible cause of ISR. A higher rate of restenosis is reported in patients with positive patch test reactions to nickel than in those with no nickel allergy (Köster et al. 2000). In the attempt to reduce the risk of ST and ISR of bare metal stents, various coatings have been used. Coatings such as platinum, phosphorylcholine and gold did not prove their effectiveness in clinical trials. (Kastrati et al. 2001, Park et al. 2002).

Some studies have suggested that titanium features better biocompatibility when compared with stainless steel, carbon, gold or other surface-coating materials. Titanium

offers low toxic ion release, which might reduce tissue reaction and inflammation (Steinemann 1996 and 1998). In an *in vitro* examination, titanium oxides were able to inhibit platelet aggregation and fibrin growth (Zhang et al. 1998). *In vivo* this was shown in a dog model by scanning electron microscopy titanium-coated carbon cylinders 14 days after the implantation of the cylinders in the ventral aorta of a dog (Zhang F et al. 1998). In a porcine model, titanium-nitride-oxide (TITANOX)-coating appeared to reduce neointimal hyperplasia when compared to uncoated stainless steel stents (Windecker et al. 2001). The addition of nitrogen to titanium oxide has been shown to lower platelet adhesion and fibrinogen absorption (Tsyganov I et al. 2005 and 2007). In a chemical elementary analysis, TITANOX-coated stents were found to have nitride-oxide molecules on the coating surface. The ion release characteristics were not examined. However, the stents appeared to have antiproliferative and antiaggregatory properties (Windecker et al. 2006). The safety of TITANOX-coated stent has been shown in several reports with real-life unselected populations (Moschovitis et al. 2010, Karjalainen et al. 2006, Mosseri et al. 2005 and 2006), as well as in the challenging subgroup of patients with diabetes and acute myocardial infarction (Valdés et al. 2012, Karjalainen et al. 2012, Tuomainen et al. 2013). In the EXTREME registry trial, Valdesuso et al. reported a good outcome 6-10 months after Titan-2® stent (Hexacath, Paris, France) implantation in small coronaries sized 2.0-2.75 mm (Valdesuso et al. 2010). However, in some studies, TITANOX-coated stents demonstrated no superiority over drug-eluting stents in view of clinical outcomes (Limacher et al. 2012, Pilgrim et al. 2011). The TITAN OPTIMAX® stent (Hexacath, Paris, France) is a novel TITANOX-coated stent that utilized a cobalt chromium stent platform.

The use of antiproliferative drugs in DESs has been associated with delayed or inhibited endothelialization and the occurrence of late stent thrombosis. In order to assist the endothelialization of struts, the Genous™ EPC capturing R stent™ (OrbusNeich Medical Technologies, Fort Lauderdale, FL, USA) was developed. This stent is built on a stainless steel scaffold and coated with a polysaccharide matrix, monoclonal anti-human CD34+ antibodies covalently attached to the surface. The antibody is specific to the surface antigens on bone marrow-derived endothelial progenitor cells, creating an imunoaffinity surface to attract the circulating endothelial progenitor cells, which are expected to develop into mature functional endothelium. Within 48 hours of stent implantation, the stent surface exhibited a rich endothelial cell population visualized by immunohistochemistry and scanning electron microscope in animal models (Kutryk et al. 2009). Several small-to-medium sized registry and postmarketing studies have demonstrated the good safety profile of endothelial progenitor cell capture stents (Aoki et al. 2005, Duckers et al. 2007). The Combo stent (OrbusNeich Medical, Inc, Ft Lauderdale, FL, USA) comprises the OrbusNeich R stent, with sirolimus added in a bioabsorbable polymer. In REMEDEE trial Combo stent was compared to PES, and after 9-month follow-up, the Combo stent was noninferior in regard to in-stent late lumen loss, with an acceptable safety profile (Haude M et al. 2013).

2.2.3 Drug eluting stents

2.2.3.1 First-generation DESs

Drug-eluting stents were primarily developed to reduce ISR formation and therefore minimize the risk of ISR, the major drawback of PCI with BMSs. In the early years of the 21st century, the first-generation DESs were developed. The pharmacological agent was eluted directly into the vessel wall from a durable polymer coating of the stent, and this site-specific delivery of the agent appeared promising in inhibiting neointimal hyperplasia (NIH) (Babapulle et al. 2002). In the CYPHER[®] stent (Cordis, Miami Lakes, Florida, USA) a stainless steel stent was coated with a durable polymer mixture of polyethylene-covinyl acetate and poly-n-butyl methacrylate, with sirolimus (rapamycin) as the pharmacologic agent to inhibit G1 cell cycle and prevent NIH. The stent was designed to release 80% of the drug with in 30 days of implantation (Moses et al. 2003).

Paclitaxel is a lipophilic molecule derived from the Pacific yew tree *Taxus brevifolia*. Paclitaxel is capable of inhibiting cellular division in the M phase as well as motility, activation, secretory processes and signal transduction (Belotti et al 1996, Giannakakou et al. 2001). Another first-generation DES, the TAXUS[®] stent (Boston Scientific, Natick, Massachusetts, USA), was developed on a stainless steel stent platform, coated with a polyolefin polymer derivate and a microtubular stabilizing agent, paclitaxel. The TAXUS[®] stent was designed to release paclitaxel within 30 days of implantation, although over 90 % of the paclitaxel remained within the polymer indefinitely (Stone et al. 2004a).

Since the United States Food and Drug Administration approved the first-generation DESs, they revolutionized the practice of PCI. The superiority of DESs over BMSs regarding the incidence of restenosis and hence repeat revascularization has been shown in numerous studies (Morice et al. 2002, Moses et al. 2003, Schofer et al. 2003, Schampaert et al. 2004, Ardissino et al. 2004, Grube et al. 2003, Colombo et al. 2003, Tanabe et al. 2003, Stone et al. 2004b, Dawkins et al. 2005). However, with increasing number of patients with co-morbidities and complex lesions, several pre-clinical and clinical safety concerns arosed related to the use of the first-generation DESs. Although significant differences in mortality or myocardial infarction had not been found in meta-analyses, the incidence of late and very late definite STs appeared somewhat increased (Virmani et al. 2004, Finn et al. 2005, Mauri et al. 2007, Stone et al 2007), and they were associated with the discontinuation of clopidogrel threrapy (Jensen et al. 2007). Incomplete neointimal coverage, the lack of functioning endothelium and hypersensitivity reactions to the polymer have been thought to increase the risk of late ST (Daemen et al. 2007, Nakazawa et al. 2008, Joner et al. 2006).

2.2.3.2 Second-generation durable polymer DESs

Newer-generation DESs have been developed in order to improve the safety profile of first-generation DES while maintaining the efficacy. The objective of the manufacturers was to develop improved and more biocompatible durable polymers, DESs using

bioresorbable polymers for drug-release and DESs with polymer-free drug release, and, finally, fully bioabsorbable DESs (Räber et al. 2011).

Everolimus is a member of the Limus family, and it is a Sirolimus analogue. Although the immunosuppressive activity of everolimus is 2- to 5-fold lower than that of sirolimus *in vitro*, oral everolimus has proven to be at least as potent as sirolimus in models of autoimmune disease and heart transplantation (Schuler et al. 1997). The second-generation everolimus-eluting stents (EES), the XIENCE® stent (Abbott Vascular, Santa Clara, CA, USA) also marketed as the PROMUS® stent (Boston Scientific, Natick, MA, USA), are manufactured on cobalt chromium alloy struts covered by a durable polymer consisting of acrylic and fluoro polymers with an everolimus concentration. The stent is designed to release 80% of the everolimus within 30 days of implantation (Räber et al. 2011). The EES has been compared against the paclitaxel-eluting stent (PES) in the SPIRIT II, SPIRIT III and SPIRIT IV trials as well as the COMPARE trials. The SPIRIT trials enrolled patients with simple to moderate complex coronary lesions. Patients with acute or recent myocardial infarction and high-risk lesions, such as chronic total occlusions and true bifurcations, as well as those with thrombus and those with left main coronary artery lesions or a vein graft were excluded the study. In the COMPARE trial, only patients unable to comply with dual antiplatelet therapy (DAPT) for 12 months or those presenting with cardiogenic shock were excluded. The EES-treated patients had significantly reduced rates of ST compared to the PES-treated ones through two years of follow-up, with a concomitant reduction in cardiac death or MI (Kedhi et al. 2012). The PROMUS Element™ stent (Boston Scientific, Natick, Massachusetts) is a novel EES that uses the same durable polymer as the XIENCE V stents and the PROMUS stents, but cobalt chromium is substituted by platinum chromium. In the PLATINUM trial, platinum chromium EES was non-inferior to the cobalt chromium EES for target lesion revascularization (TLR), with non-significant differences in measures of safety and efficacy during 12-month follow-up after PCI (Stone et al. 2011).

The ENDEAVOR® stent (Medtronic Vascular, Santa Rosa, CA, USA) received European Medicines Agency and FDA approval in July 2005 and February 2008, respectively. It is built on the platform of cobalt chromium BMS, coated with zotarolimus and a biocompatible, durable polymer. Zotarolimus is another Limus analogue, whose antiproliferative activities are comparable to those of sirolimus. The drug-polymer coating was designed to release 95% of the total dose of zotarolimus within 15 days of stent implantation in order to cause less inflammation than the polymers used in the first-generation DESs (Meredith et al. 2005). The zotarolimus-eluting stent has been compared with both first generation DESs in ENDEAVOR II, ENDEAVOR III, ENDEAVOR III and ENDEAVOR IV trials. In ENDEAVOR III trial after 9 months follow-up zotarolimus eluting stent was found inferior to SES regarding late loss and binary restenosis, but there was no significant differences in the rate of death, cardiac death, stent thrombosis, repeat revascularization, MACE, and target vessel failure (Kandzari et al. 2006). The ENDEAVOR IV trial's 5-year follow-up showed durable

efficacy and safety of the ENDEAVOR® stent compared with PES for the treatment of de novo lesions. Although the overall definite or probable ST rates were similar in both stent groups, very late ST and late MIs appeared significantly more common in the PES group (Kirtane et al. 2013). In the PROTECT trial, no evidence of the superiority of the ENDEAVOR® stent over the CYPHER® stent in regard to definite or probable ST could be found at 3-years' follow-up (Camenzind et al. 2012).

The ENDEAVOR RESOLUTE® (Medtronic Vascular, Santa Rosa, Ca, USA) is a modified zotarolimus-eluting stent, whose polymer consists of three components; a hydrophilic C19 polymer, water soluble polyvinyl pyrrolidinone and a hydrophobic C10 polymer. The zotarolimus release is different to that of the original ENDEAVOR® stent: 50 % of the drug is released within the first 7 days, and 85 % of the total drug is released at 60 days after stent implantation (Råber et al. 2011). The ENDEAVOR RESOLUTE FIM trial showed 0.8% target lesion revascularization (TLR) and 6.9% target vessel failure at 12 months after coronary stenting. The RESOLUTE All Comers trial compared the safety and efficacy of the ENDEAVOR RESOLUTE® stent and EES at 2-years follow-up, and no major differences were found between these two second-generation DESs (Silber et al. 2011).

2.2.3.3 DESs with a biodegradable polymer

Durable polymer coatings have proven to be a useful method for drug loading and drug release of the DESs. However, several animal and human studies have shown durable polymer to be a possible stimulus for local vascular hypersensitivity and inflammatory reactions potentially inducing late and very late ST (Byrne et al. 2009, Cook et al. 2007). In order to avoid these limitations, bioresorbable polymers have been developed. Most of the bioresorbable polymers utilize poly-L-lactic acid and poly-D-L-lactide, which are converted to lactic acid. Several DESs with a coating of biolimus-eluting biodegradable polymer have been developed. Biolimus is a highly lipophilic, semisynthetic sirolimus analogue, which reversibly inhibits the cell cycle transition of proliferating smooth muscle cells. The BIOMATRIX® stent (Biosensors International PTE Ltd., Singapore), the Nobori® stent (Terumo Corporation, Tokyo, Japan), the AXXESS® bifurcation stent (Devax, Inc., Irvine, Ca, USA), and the XTENT® modular system (Xtent, Inc., Menlo Park, CA, USA) are based on this polymer system. In the NOBORI phase I and II studies, the biolimus-eluting stent was found to be superior to PES regarding in-stent late loss (Chevalier B et al. 2007 and 2009). In the 2-year follow-up of the NOBORI II study, the rates of MACEs were low but increased in more complex lesions, and ST were rare (Danzi et al. 2012). The BIOMATRIX® stent was compared to sirolimus-eluting stent (SES) in the LEADERS trail on real-world patients. After 3-years' follow-up, the Biomatrix® stent had exhibited equivalent safety and efficacy to SES, and none definite ST occurred in patients treated with a biolimus-eluting stent after the discontinuation of clopidogrel (Wykrzykowska et al. 2011).

The SYNERGY stent (Boston Scientific Corp., Natick, Massachusetts) is a recently developed novel stent, which is built on a platinum-chromium stent platform using a biodegradable polymer with everolimus absorption. The EVOLVE trial compared the PROMUS Element EES and the SYNERGY stent with two different drug doses. During 6-months of follow-up, the rate of clinical events was low and comparable between the groups, and no ST occurred in any group (Meredith et al. 2012).

Sirolimus is used as an antiproliferative drug in several biodegradable polymer stents, such as the Nevo[®] stent (Cordis Corporation, Johnson & Johnson, Warren, NJ) and the Supralimus and the Supralimus-Core stents (Sahajanand Medical Technologies Pvt Ltd) as well as the ORSIRO stent (Biotronik AG, Bülach, Switzerland). A 3-year follow-up of the ISAR-TEST 4 trial patients showed similar clinical outcomes with biodegradable polymer SES and permanent polymer DES (Byrne et al. 2011). The BIOFLOW-I study, a prospective FIM study of the ORSIRO stent, demonstrated low rates of in-stent NIH and cardiovascular events at the 12-month follow-up (Hamon et al. 2013). Paclitaxel, novolimus and myolimus are also used in bioabsorbable polymer stents, but these stents are not in wide clinical use.

2.2.3.4 DESs with no polymer

As a polymer may be a potential source of late adverse events, attempts have been made to develop stents with a polymer-free drug-carrier system. However, the polymers in DESs control the release of the antiproliferative drugs. In order to solve this problem, the modifications in the surface of the stent platform are necessary to carry the drug. Several antiproliferative drugs are used in polymer-free stents. The Amazonia PAX stent (MINVASYS, Paris, France) integrates CoCr stent and paclitaxel. In the BioFreedom stent (Biosensors Inc, Newport Beach, Ca), a stainless steel platform has microstructured, abluminal surface that allows biolimus adhesion to the vessel wall. The OPTIMA stent (CID S.r.l., Saluggia, Italy) incorporates tacrolimus as the antiproliferative drug. The VESTAsync stent (MIV therapeutics, Atlanta, Ga) utilizes sirolimus, and in the YUKON ChoiceDES stent (Translumina, German) various drugs have been tested, such as a combination of sirolimus and procubol. In the ISAR-TEST 5 trial, the YUKON stent with the sirolimus+procubol combination was found to be noninferior to zotarolimus-eluting stent (ENDEAVOR RESOLUTE[®]) in regard to clinical end points at 12 months' follow-up (Massberg et al. 2011).

2.2.4 Bioabsorbable stents

The acute recoil and NIH appear a relatively shortly after PCI, and coronary stents do not yield ever-lasting benefit in the coronary. Instead, they can promote late adverse events, including very late ST and the elimination of physiological vasomotion. In some cases, implanted stents can impede surgical revascularization and impair lesion imaging. Bioabsorbable stents have potential in paediatric cardiology, because they allow vessel

growth and do not require surgical removal (Zartner et al. 2005). The concept of a bioabsorbable coronary stent developed over 20 years ago, but the challenges of these new devices are sufficient radial strength for an appropriate duration as well as the thickness of the struts and drug delivery system in the case of drug-eluting bioabsorbable stents (Tanguay et al. 1994).

Currently, four materials are used in bioabsorbable scaffolds-lactide polymers, particularly poly-levo-lactic acid as well as magnesium, polyanhydrides (salicylic acid and adipic acid), and polycarbonates (amino acids, eg, tyrosine) (Patel et al. 2013). The absorption period varies from three weeks to up to three years. Both bioabsorbable stent types, drug-eluting and non-drug-eluting ones, have been developed.

More than 16 different scaffolds are being developed by various manufactures. The longest follow-up (over 10 years) of biodegradable stents in humans has been undertaken by Nishio et al. They followed patients after The Igami-Tamai stent (Kyoto Medical Planning Co, Ltd; Kyoto, Japan) implantation, reporting the MACEs together with results of angiography and IVUS. The stent struts mostly disappeared within three years. Acceptable MACE rates and scaffold thrombosis rate (2) were reported without stent recoil and final negative vessel remodelling (Nishio S et al. 2012). In the ABSORB trial, the ABSORB everolimus-eluting bioresorbable vascular scaffold (Abbott Vascular, Santa Clara, Ca, USA) showed a sustained low rate of MACE (3.4%) with no late complications during a 4-year follow-up (Dudek et al. 2012). The first-generation AMS-1 absorbable magnesium scaffold/stent (Biotronik, Ag, Zurich, Switzerland) confirmed in the PROGRESS-AMS trial the unacceptable high rates of TLR 23.8% and 45% at 4 and 12 months, respectively. This was primarily caused by the early bioabsorption of the platform (Erber R et al. 2007). In the DREAMS drug-eluting absorbable metal scaffold (Biotronik Ag, Zurich, Switzerland) a degradable polyactic-co-glycolic acid polymer and paclitaxel coating was added onto AMS-2 refined magnesium alloy struts. This device performed much better than the AMS-1 in up to 12 months' follow-up in the BIOSOLVE-1-trial (Haude et al. 2013).

2.2.5 Other stent designs

In the setting of acute MI, epicardial vasoconstriction and thrombosis load can lead to stent undersizing and malapposition after primary PCI. The self-expanding, STENTYS® stent (STENTYS SA, Paris, France) is made of nitinol, an alloy of nickel and titanium, and is available in two forms: a BMS and a PES with a durable polymer. In the OPEN I study, a Stentys BMS and Stentys PES were compared in bifurcation lesions. At the 6-month follow-up, the clinically-driven TLR was 3.7% and 24.2%, and angiographic late loss in the proximal main branch 0.39 and 0.86 mm with PES and BMS, respectively (Verheye et al. 2011). In the APPPOSITION II study, a Stentys BMS was compared with a balloon-expandable stent in patients with ST-elevation MI undergoing primary PCI. Measured by OCT three days after implantation, the STENTYS stent demonstrated

better apposition of the stent struts. No statistical differences were seen in major adverse cardiac events after 6 months of follow-up (van Geuns et al. 2012).

The MGuard™ stent (MGS) (InspireMD, Tel Aviv, Israel) is a bare-metal stent with a polyethylene terephthalate (PET) micronet mesh coverage on its outer surface. It is designed to trap and prevent distal embolization during a STEMI PCI (Kaluski et al. 2008). Among patients with acute STEMI undergoing emergency PCI, the Master trial showed superior rates of epicardial coronary flow and complete ST-segment resolution with MGSs versus conventional metal stents (Stone et al. 2012). In the INSPIRE trial, 30 patients were followed after MGuard stent implantation for one year, and no efficacy or safety concerns arose (Costa et al. 2011).

2.3 Antithrombotic therapy during a percutaneous coronary intervention

To prevent thrombosis of the intravascular instrumentarium and to minimize thrombus formation at the site of the lesion treated, effective pharmacotherapy is required during PCI. The combination of antiplatelet agents and anticoagulants is used during PCI to minimize thrombotic complications and to improve the early clinical outcome (Popma et al. 2004).

2.3.1 Acetylsalicylic acid

Acetylsalicylic acid, i.e. aspirin, is a cornerstone in the adjunctive pharmacological therapy of PCI, and it is the most widely studied antiplatelet drug. Its irreversible effect on platelet function is carried by the inhibition of the thromboxane A₂ synthesis. Aspirin is rapidly absorbed in the stomach and upper intestine, and plasma levels peak 30–40 minutes after ingestion, with evident platelet function inhibition within an hour (Cheng 2013). However, complete suppression of thromboxane A₂ synthesis is achieved after 7–10 days' daily administration of 30–50 mg of aspirin (Patrono et al. 1985). The role of low-dose aspirin (75–325 mg daily) in secondary prevention for patients with coronary artery disease, peripheral artery disease or cerebrovascular disease is well established (Hennekens 2007, Baigent et al. 2009). Early trials suggested the aspirin and dipyramole combination for antithrombotic therapy in balloon angioplasty (Barnathan et al. 1987, Schwartz et al. 1988), but further studies showed comparable benefits in aspirin monotherapy (Lembo et al. 1990). Early studies on ST prevention demonstrated the benefits of combining warfarin with aspirin, but the safety of this strategy was questioned by the need for prolonged hospitalization and an excess of vascular access site complications when compared with aspirin monotherapy (Serruys et al. 1994). For all patients undergoing a PCI, either elective or with acute coronary syndrome (ACS), pretreatment with aspirin including a 150–300 mg oral loading dose is recommended,

and the medication may be administered intravenously 80–150 mg for patients who are unable to swallow, followed by a maintenance dose of 75–100 mg per os daily. Only in patients with an established allergy to aspirin, or non-responders to aspirin, alternative antiplatelet agents, mainly thienopyridine derivatives, should be considered (Levine et al. 2012).

2.3.2 Thienopyridine derivatives

To achieve effective platelet inhibition, thienopyridines that inhibit adenosine diphosphate induced platelet aggregation was developed. Ticlopidine was the first-generation P2Y₁₂ receptor antagonist, but the utility of this agent was limited by its bone marrow toxicity. Clopidogrel largely replaced ticlopidine, and became a standard antithrombotic therapy in coronary heart disease and in patients undergoing PCI. Prasugrel and ticagrelor are newer-generation thienopyridines that have more rapid onset of action than clopidogrel (Cheng 2013). Cangrelor is another, intravenously administered P2Y₁₂ receptor inhibitor that does not require metabolic conversion for activity. Cangrelor has a short average half-life of 2.6 minutes (Ferreiro et al. 2009), and the majority of patients recover more than 60% of their baseline aggregation response by 1 hour after infusion (Cheng 2013). In the CHAMPION-PHEONIX trial, the use of cangrelor during PCI was associated with a reduced rate of ischaemic events, including ST, when compared to the loading of pre-PCI clopidogrel, with no significant increase in severe bleeding (Bhatt et al. 2013). Elinogrel is a novel P2Y₁₂ receptor inhibitor with a direct, potent and reversible effect. It is the only P2Y₁₂ inhibitor available in both intravenous and oral formulations. The first results of relatively small randomized trials on elinogrel are available (Welsh et al. 2012), but the role of elinogrel in clinical practice is not well established.

2.3.2.1 Clopidogrel

Clopidogrel inhibits P2Y₁₂ receptor irreversibly, being a prodrug with no antiplatelet activity of its own. Only fifteen percent of the absorbed drug is metabolized by the liver in a two-step process into an active metabolite (R130964) (Oprea et al. 2013). A loading dose of 300 mg results in more rapid platelet inhibition than a 75 mg dose. After the loading dose of 600 mg, the peak plasma level is reached in 1-2 hours, but the full antiplatelet effect takes 4-6 hours to achieve. After the discontinuation of clopidogrel, it takes the lifespan of platelets, 7-10 days, for the antiaggregant effect to return to baseline (Tauber et al. 2004). Despite its established use in patients with coronary artery disease, clopidogrel has some limitations. Fifteen to thirty percent of patients on a therapeutic clopidogrel dose have inadequate platelet inhibition (Gurbel et al. 2003). The term “resistance to clopidogrel” has recently been revised to a high on-treatment platelet reactivity if visible in laboratory tests, and a treatment failure is found if a recurrent clinical event has occurred (Bonello et al. 2010). Patients in cardiogenic shock have demonstrated an impaired absorption of clopidogrel (Gurbel et al. 2009). Obese and diabetic patients might need a bigger dose of clopidogrel to achieve proper

antiplatelet effect (Santilli et al. 2012). CYP enzymes are a family of microsomal drug-metabolizing enzymes that metabolize clopidogrel into its active form. Statins, proton pump inhibitors, ketoconazole and erythromycin can inhibit clopidogrel metabolism by interacting with various CYP enzymes (Oprea et al. 2013). Several CYP and other enzymes affect clopidogrel metabolism, but the CYP2C19 enzyme appears to be the most important. The CYP2C19*2 or *3 allele of the CYP2C19 gene are associated with an impaired response to clopidogrel and an increased incidence of MACE (Cuisset et al. 2012, Karaźniewicz-Łada et al. 2010).

In stable coronary artery disease, a systematic clopidogrel preloading before diagnostic coronary angiography is not recommended. In the case of elective PCI, when the coronary anatomy is known beforehand, a loading dose of 600 mg clopidogrel is recommended, followed by 75 mg daily. For patients with ACS, 600 mg loading should be used (Amsterdam et al. 2014, Windecker et al. 2014). The CURRENT-OASIS 7 trial compared a double-dose regimen of clopidogrel (a 600 mg loading dose followed by a 150 mg dose at days 2 to 7 then a 75 mg maintenance dose) with a 300mg loading dose followed by a 75 mg maintenance dose. In the double-dose group, patients who underwent PCI had a tendency towards fewer cardiovascular events, but more major bleedings (Mehta et al. 2010).

2.3.2.2 Prasugrel

In order to overcome the suboptimal efficacy of clopidogrel in some patients, more potent and rapid P2Y₁₂ receptor antagonists have been developed. Prasugrel is a newer-generation irreversible P2Y₁₂ inhibitor that requires one metabolic step to be activated (Jernberg et al. 2006). Prasugrel has a more rapid onset of action and more consistent and complete P2Y₁₂ inhibition compared to clopidogrel (Bhatt 2009). Polymorphisms in CYP2C19 or the drug interaction with proton-pump inhibitors do not interfere with prasugrel metabolism. In high on-treatment platelet reactivity analyses most of the patients having suboptimal platelet reactivity inhibition on clopidogrel therapy demonstrate an adequate response to prasugrel (Angiolillo et al. 2011, Alexopoulos 2012). The TRITON-TIMI 38 trial compared prasugrel to clopidogrel in patients with ACS undergoing a planned PCI. Patients randomized to prasugrel had significantly fewer ischaemic events including ST, but had a higher risk of major bleedings (Wiviott et al. 2007). This was seen especially in patients with a known history of stroke, those over 75 years of age, and with a body weight of under 60 kg. In a subanalysis of the TRITON-TIMI 38 trial, prasugrel was more effective than clopidogrel in patients with STEMI or a history of diabetes mellitus, without an apparent excess in bleeding (Wiviott et al. 2008, Montalescot et al. 2009). However, in the TRILOGY ACS study, in patients with unstable angina or non-ST-elevation myocardial infarction (NSTEMI) not undergoing revascularization, prasugrel was not beneficial in comparison to clopidogrel in terms of cardiovascular death, MI or stroke. Prasugrel therapy was not associated with a higher risk of severe and intracranial bleeding among patients over 75 years of age in this study

(Roe et al. 2012). The ACCOAST study examined NSTEMI patients' pre-treatment with prasugrel vs. placebo before PCI. In the prasugrel pre-treated group, more major bleedings occurred with no benefit in regard to cardiovascular events (Montalescot et al. 2013). For NSTEMI patients, the recent European guideline recommends prasugrel loading after the coronary anatomy is known (Windecker et al. 2014). In the setting of STEMI, a 60mg loading dose of prasugrel is recommended as soon as possible, followed by 10mg maintenance dose daily (O'Gara et al. 2013, Windecker et al. 2014),

2.3.2.3 Ticagrelor

Ticagrelor belongs to a new class of antiplatelet agents, the cyclopentyl-triazolopyrimidines. It is a selective, reversible P2Y₁₂ receptor antagonist that, unlike clopidogrel and prasugrel, does not require metabolic activation, resulting in a faster onset of action and exhibiting a greater degree of the inhibition of platelet aggregation (80% at 2 hours after loading dose) as compared to other P2Y₁₂ inhibitors (Gurbel et al. 2009). However, in the clinical setting of STEMI in the RAPID study, after loading dose of 180mg ticagrelor, one to five hours was needed to achieve a satisfactory platelet reactivity assessed by VerifyNow (Parodi et al. 2013). Because the CYP3A4 enzyme mainly metabolizes ticagrelor, its pharmacodynamics are not effected by CYP2C19 genetic variants (Oprea et al. 2013). In the PLATO trial, ticagrelor was compared to clopidogrel in ACS patients. Treatment with ticagrelor reduced the rate of death from vascular causes, MI or stroke, with no increase in the rate of overall major bleedings but with an increase in the rate of non-GABG-related major bleedings. The most common side effects of ticagrelor therapy were dyspnoea and bradyarrhythmias, but they seldom caused discontinuation of treatment (Wallentin et al. 2009). Several subanalyses were performed from the PLATO trial. In substudies with patients with ACS and managed by medical treatment, patients who underwent GABG, and patients with STEMI, chronic kidney disease or diabetes, no significant differences in bleedings could be found between the ticagrelor and clopidogrel groups (James et al. 2010a and 2010b, Steg et al. 2010, Held et al. 2011, James et al. 2011). A 180 mg loading dose of ticagrelor is recommended for ACS patients, followed by a dose of 90 mg twice a day (O'Gara et al. 2013, Amsterdam et al. 2014, Windecker et al. 2014). To date, no larger studies have been published comparing prasugrel and ticagrelor in ACS patients.

Life-long single antiplatelet therapy, usually 75-100 mg oral aspirin if not contraindicated, is recommended for all patients after PCI. The optimal duration of P2Y₁₂ inhibitor after PCI has not been determined. The clinical setting of the patient, the type of stent used and the patient's risk for haemorrhagic complications must be considered. With early-generation DESs, there was a concern regarding the ST risk lasting even years after PCI, and several guidelines recommended a dual antiplatelet therapy (DAPT) with P2Y₁₂ receptor antagonist and aspirin for one year or longer after DES implantation. Data from new-generation DES trials show a safety profile of DESs similar to or even better than that of BMSs, and prolonging DAPT after DES implantation beyond one

year is not supported (El-Hayek et al. 2014). The recommended duration of DAPT in stable coronary artery disease is at least one month after BMS implantation and six months after new-generation DES implantation. In patients undergoing a PCI for high-risk ACS, one-year DAPT is recommended, irrespective of stent type (O’Gara et al. 2013, Amsterdam et al. 2014, Windecker et al. 2014).

2.3.3 Unfractionated heparin

For decades, unfractionated heparin (UFH) has been the most commonly used anticoagulant for PCI to prevent periprocedural thrombotic complications in either the elective or the ACS, either NSTEMI or STEMI, setting. Heparin is a glycosaminoglycan composed of a mixture of polysaccharide chains. The anticoagulation effect of UFH is based on the activation of antithrombin, which results in accelerated inactivation of several coagulation factors, particularly factor Xa. The UFH effect can be measured by testing the activated clotting time. UFH is administered as an intravenous bolus in a weight-adjusted manner (100 IU/kg) to achieve a therapeutic activated clotting time (250-350s). During prolonged procedures, under activated clotting time guidance, an additional i.v. bolus may be required (Boccaro et al. 1997, Koch et al. 1997). Heparin binds to plasma proteins, the levels of which vary between patients, thus yielding a possibly unpredictable anticoagulation response. Heparin increases coagulation factors, decreases antithrombin levels through the rebound effect and can induce thrombocytopenia (Gukathasan et al. 2013). However, UFH is widely used in the management of ACS patients and recommended in both European and North American guidelines (Amsterdam et al. 2014, Windecker et al. 2014).

2.3.4 Low-molecular-weight heparin

Low-molecular-weight heparin (LMWH) consists of fragments of UHF with a mean molecular weight of 5,000 daltons. The anticoagulation activities of LMWH occur via the inhibition of factor Xa opposing to antithrombin directly, thus inhibiting upstream activation of the coagulation cascade (Hirsh et al. 2004). Several clinical studies have demonstrated that LMWHs are effective and safe compared to UFH for the management of patients with ACS, with clinical benefit maintained long-term (Puymirat et al. 2013). Enoxaparin is a LMWH with the largest volume of published information on its use in the setting of PCI. In the ATOLL randomized trial, intravenous enoxaparin, as compared with UFH reduced clinical ischaemic outcomes with no differences in bleeding and procedural success in STEMI patients undergoing a PCI (Montalescot et al. 2011). The anticoagulation effect of enoxaparin is predictable and requires no monitoring (Silvain et al. 2010). In the case of NSTEMI, enoxaparin can be administered subcutaneously. In patients with no prior anticoagulation therapy, either in an elective or STEMI setting, or in NSTEMI patients, whose time elapse from the last subcutaneous administration so requires, an intravenous pre-procedural enoxaparin bolus may be used to support PCI

(Levine et al. 2012, Montalescot et al. 2011). In meta-analyses of over 30,000 patients, enoxaparin exhibited superiority over UHF in reducing mortality and bleeding outcomes during PCI, particularly in patients undergoing a primary PCI for STEMI. (Silvain et al. 2012).

2.3.5 Glycoprotein IIb/IIIa inhibitors

The platelets' aggregation and adhesion to disrupted endothelium is mainly mediated by the surface glycoprotein (GP) IIb/IIIa receptor (Plow et al. 1989). The GP IIb/IIIa inhibitors' antiplatelet effect is derived by blocking fibrinogen binding to the GPIIb/IIIa receptors, thus preventing the linking of platelets. Abciximab, tirofiban and eptifibatate are clinically available GP inhibitors. The trials with patients receiving GP inhibitors during PCI have yield mixed results. Abciximab was demonstrated to decrease the risk of MACEs compared to placebo in high-risk patients with NSTEMI and scheduled for a PCI after treatment with clopidogrel. In the setting of STEMI, deaths or reinfarctions were reduced in patients receiving abciximab versus placebo (Cheng et al. 2013). In a large meta-analysis of 20,000 patients, tirofiban used in patients with unstable angina and NSTEMI, scheduled for a PCI, was significantly more effective than placebo in reducing the risk of mortality or the composite of death and MI at 30 days' follow-up (Valgimigli et al. 2010). In another meta-analysis of more than 66,000 NSTEMI/ACS patients, GP inhibitors used during PCI reduced the risk of all-cause death at 30 days but not at six month, and reduced the risk of death or myocardial infarction both at 30 days and at six months (Bosch et al. 2013). However, the risk of increased severe bleeding associated with the use of GP inhibitors is demonstrated in several studies (Bosch et al. 2013, Sciahbasi A et al. 2012, Tricoci et al. 2011). At present, routine use of GP inhibitors during PCI is not recommended. Intra-procedural administration is warranted in the presence of complex, high-risk lesions, of threatening vessel closure, of visible thrombus, or of no-flow, regardless of the clinical indication for PCI. In the case of elective patients treated with UFH and not pre-treated with clopidogrel, the use of GP inhibitors can be considered. In setting of primary PCI for STEMI patients with a low bleeding risk, GP inhibitors may be used in conjunction with UFH (Levine et al. 2012, Steg et al. 2012).

2.3.6 Direct thrombin inhibitors

Three direct thrombin inhibitors, hirudin, argatroban and bivalirudin, have been studied as alternatives to heparin during PCI. Hirudin proved a promising agent in the first clinical studies (Serruys et. al 1995), but further investigations suggested an increased risk of major bleeding associated with its use during PCI (Roe et al. 2001, Mehta et al. 2002).

Bivalirudin offers several biochemical advantages over heparin. Bivalirudin does not bind plasma proteins, producing a more predictable anticoagulant effect and, thus not

requiring monitoring to achieve therapeutic levels. Unlike heparin, bivalirudin is not neutralized by platelet factor 4 and high-molecular-weight multimers of von Willenbrand factor. Bivalirudin has the capability to inactivate both free thrombin and fibrin-bound thrombin, which makes bivalirudin effective against already formed clots. Bivalirudin may provide antiplatelet and anti-inflammatory effects, which may offer additional protection against the acute thrombosis. Finally, the use of bivalirudin does not carry the potential for the development of heparin-induced thrombocytopenia (Thompson et al. 2011).

Several studies have investigated the safety and efficacy of bivalirudin during PCI in the setting of elective, unstable angina/NSTEMI and STEMI. In the CACHET trial with elective patients, bivalirudin with or without abxiximab was at least as effective and safe as heparin combined with abciximab (Lincoff et al. 2002). The REPLACE-1, the REPLACE-2 and the ISAR-REACT-3 trial demonstrated the noninferiority of bivalirudin to heparin or heparin plus GpIIb/IIIa inhibitors for use during elective PCI and, additionally, bivalirudin was associated with reduced major bleedings (Lincoff et al. 2003 and 2004, Kastrati et al. 2008).

NSTEMI and unstable angina patients have been studied comparing the use of bivalirudin to heparin during PCI in three large randomized controlled trials, and comparable outcomes could be found in up to one year of follow-up. Bivalirudin monotherapy was superior in terms of reducing bleedings, but this benefit was lost when bivalirudin was combined with GpIIb/IIIa inhibitors in the ACUITY trial (Bittl et al. 1995, Stone et al. 2006, Schulz et al. 2013).

In the clinical setting of STEMI, bivalirudin has exhibited efficacy and safety when compared to heparin plus GpIIb/IIIa inhibitors, and the reduction in mortality. This correlated directly with reduced haemorrhagic complications and seemed to persist during 3 years' follow-up (Stone et al. 2011, Shelton et al. 2013, Steg et al. 2013). However, in the HEAT-PPCI trial, compared with bivalirudin, UFH reduced the incidence of major adverse ischaemic events in the setting of primary PCI, with no increase in bleeding complications (Shadad et al. 2014).

2.4 Complications of percutaneous coronary intervention

2.4.1 Restenosis

In-stent restenosis, the re-narrowing of a stented area of the coronary, remains an important reason for the failure of long-term success after PCI. Angiographic restenosis is defined as a lumen diameter loss of at least 50% in the in-segment area including the stent area and 5-millimetre segments proximal and distal to the stent edges (Erber et al. 1998). The development of restenosis usually occurs during the first months after the PCI (Serruys et al. 1988). Depending on lesion- and patient-related factors, restenosis

has been observed to occur in 30%–50% of patients after coronary balloon angioplasty, and in as many as 60% of vein grafts.

ISR has traditionally been considered a relative benign clinical entity. Instead of recurrent angina angiographically apparent restenosis can cause only mild symptoms delaying the further intervention. In a study of over 10,000 patients whose coronary artery was stented with BMS and DES, routine control angiography was performed 6–8 months after PCI. Restenosis was detected in 2,643 (26.4%) of the patients. The primary outcome was 4-year mortality. Restenosis was found to be as an independent predictor of higher mortality together with other relevant clinical characteristics such as age, diabetes mellitus, smoking habit, previous bypass surgery and left ventricular ejection fraction even among patients asymptomatic at a routine control angiography (Cassese et al. 2014a).

Coronary balloon angioplasty induces vascular injury in the artery. Restenosis is a response to this barotrauma, resulted from three processes – early elastic recoil, negative arterial remodelling (vessel area decreases in size) and neointimal hyperplasia. Immediately after the PCI, the mechanical injury to the arterial wall stimulates the platelet activation and granulation tissue correspondence, followed by the proliferation of vascular smooth muscle cells and extracellular matrix synthesis (Rensing et al. 2001). Elastic recoil and negative remodeling are effectively prevented with stenting so that ISR is mainly caused by neointimal hyperplasia (Hoffman et al. 2000).

Recent pathological studies also suggest that in-stent neoatherosclerosis may play a role in ISR formation after the implantation of both BMSs and DESs. In an autopsy study, the earliest neoatherosclerotic changes were found at four months after SES implantation, while the earliest atherosclerotic change with foamy macrophage infiltration was seen beyond two years and remained a rare finding until four years in BMS stented lesions. The thin-cap fibroatheromas or intimal rupture that are seen in unstable lesions occurred earlier after DES implantation (1.5 ± 0.4 years) when compared to BMS implantation (6.1 ± 1.5 years) (Seung-Jung et al. 2012).

Diabetes doubles the risk of restenosis, and another patient-related risk factor is a history of restenosis (Kastrati et al. 1997). Complex lesion morphologies, chronic occlusions and ostial or bifurcation lesions are associated with a higher probability of restenosis (Colombo et al. 2004). A recent large study found small vessel size to be a powerful determinant of restenosis with all stents, in addition to a long lesion and long stent length after BMS implantation. The final percentage of diameter stenosis and different antirestenotic potency of DESa also predict the risk of ISR after DES implantation. Previous coronary bypass surgery was associated with a higher risk of ISR. PCI with a BMS is an independent predictor of a higher risk of restenosis as compared with first-generation DESs, while intervention with a second-generation DES demonstrated improved efficacy over first-generation DESs (Cassese et al. 2014b). Mechanical problems with stent implantation explain the development of ISR in many patients.

Both BMS and DES underexpansion is associated with ISR. Stent misplacement, the stent not fully covering the lesion or stent fractures may trigger focal ISR (Alfonso et al. 2014).

Systemic and local inflammatory status in the coronary artery wall at the time of PCI plays an important role in the development of restenosis (Toutouzas et al. 2004). Various proinflammatory biomarkers have been examined to evaluate the association of inflammatory status with ISR. The extent of C-reactive protein change immediately after PCI with a BMS and measured levels six months after appears to predict ISR. After DES implantation, C-reactive protein seems to be a superior predictor of thrombotic complications (Khouzam et al. 2012). The serum uric acid level is known as a predictor of cardiovascular diseases, most likely through an increased inflammatory response and the direct stimulation of vascular smooth muscle cell proliferation. In a study of 708 patients undergoing PCI with a BMS, the preprocedural serum uric acid level was a significant and independent predictor of further ISR formation (Turak et al. 2014). Matrix metalloproteinase-2, matrix metalloproteinase-9 and pregnancy-associated plasma protein A are inflammatory biomarkers that have been shown to associate with angiographic ISR, affecting extracellular matrix degradation and vascular smooth muscle cell migration after vascular injury (Jones et al. 2006). Fibrinogen, plasminogen activator inhibitor 1, and biomarkers for platelet and neutrophil activation soluble CD40 ligand and glycosylphosphatidylinositol-80 are also associated with ISR after BMS stenting (Khouzam et al. 2012). Interleukins, complement components C5a and C3a and tumour necrosis factor- α have been identified as markers of restenosis (Demyanets et al. 2014). Nitric oxide has been shown to prevent the growth of neointimal hyperplasia. Asymmetric dimethylarginine is a competitive inhibitor of nitric oxide synthesis. Asymmetric dimethylarginine levels were studied in 105 patients undergoing PCI with a BMS before and six months after the procedure. Twenty-seven (25.7%) patients developed ISR. The level of asymmetric dimethylarginine before the procedure was found to be a significant predictor of ISR (Ari et al. 2010). The risk of ISR is also associated with some genetic polymorphisms, such as the genes encoding the signalling molecule, toll-like receptor 2, and the cyclin-dependent kinase inhibitor, which regulates vascular smooth muscle cell and leukocyte proliferation (Khouzam et al. 2012). Neither testing of inflammatory biomarkers nor genetic markers to predict ISR have emerged in routine clinical use.

2.4.1.1 Treatment of restenosis

A great number of drugs have been tested to reduce intimal hyperplasia, but the attempts have failed. The inability of systematically administered drugs to reach sufficient concentrations locally to prevent the intimal hyperplasia reaction is considered to explain this failure (De Feyter et al. 2000). Repeating percutaneous angioplasty to re-dilatate in-stent restenosis has resulted in satisfactory acute results, but with a high recurrence of restenosis in up to 60% of the patients (Rensing et al. 2001). New approaches to coronary

intervention had to be developed to diminish the need for revascularization procedures. Mechanical debulking therapy by using a cutting balloon or rotational atherectomy did not show a significant reduction in recurrent ISR (Vom Dahl et al. 2002). Initially, intracoronary radiation, brachytherapy for ISR proved promising in reducing the clinical and angiographic restenosis rate. However, the issues of geographic miss and edge restenosis increased the risk of late stent thrombosis caused by delayed arterial healing, and the advent of DESs finally put an end to use of brachytherapy in ISR (Alfonso et al. 2014a).

Although there was some evidence that, in connection with the implantation of a BMS in BMS-ISR lesions in large vessels, a minimum of 3mm in diameter was associated with better long-term clinical and angiographic outcomes than balloon angioplasty, the results of repeat BMS implantations were unsatisfactory. In the RIBS I study, 450 BMS-ISR patients were treated with either balloon angioplasty or BMS. After six-months of follow-up, the binary restenosis rate was high in both groups (38% in the stented group, 39% in the balloon group) (Alfonso et al. 2003). The efficacy of DES in patients with BMS-ISR has been demonstrated in several studies. With first-generation DESs, the recurrent restenosis rate was 11%–21.7%, whereas an approximately 12% restenosis rate has been demonstrated with newer-generation DESs (Kastrati et al. 2005, Alfonso et al. 2006, Cassese et al. 2014b).

There is very little data concerning the treatment of ISR after DES implantation. A 14%–30% risk of 1-year (TLR) is associated with the strategy of the deployment of a second DES onto the DES-ISR. In highly complex lesions, using the same type of DES as the original was associated with a higher rate of TLR (46.3%) than an other type of DES (24.4%) was used in ISR treatment (Freixa et al. 2013).

Drug-eluting balloons have been developed as an alternative to treat ISR. DEBs are shown superiority to balloon angioplasty and comparable efficacy to first-generation DESs in BMS-ISR and also DES-ISR (Indermuehle et al. 2013). In the RIBS V Clinical Trial BMS-ISR patients were treated with either a DEB or an everolimus-eluting stent. At 9 months' follow-up, a low binary restenosis rate was seen in both groups (4.7% versus 9.5%, respectively) (Alfonso F et al. 2014b).

2.4.2 Stent thrombosis

ST is a rare but dreaded complication of PCI that most often occurs within the first month of stenting, leading to a fatality rate of 45% in some studies (Buchanan et al. 2012). ST leads to acute vessel closure and frequently presents with STEMI or sudden cardiac death (Kuchulakanti et al 2007). The Academic Research Consortium has classified STs acute if they occur within 24 hours of stenting, subacute within 1-30 days of stenting and late stent thrombosis (LST) within 30 days to one year of stenting. After one year, ST is considered very late stent thrombosis (Cutlip et al. 2007).

2.4.2.1 Risk factors of stent thrombosis

In case of acute ST, procedural-related factors, such as stent undersizing, incomplete stent expansion, residual stenosis or edge dissection and reduced coronary flow are important predictors of ST. The nonadherence to antithrombotic therapy is a striking risk factor for acute ST also (Buchanan et al. 2012).

The pathological findings in post mortem studies from patients who died of LST and very late ST have convinced, that delayed arterial healing characterized by poor endothelialisation is the most important morphometric predictor for LST and very late ST. This is particularly seen with first-generation DESs when stent struts penetrate into the necrotic core, in bifurcation stenting, with long and overlapping stents used and in severe stent strut fractures. The hypersensitivity reaction is more associated with SES, whereas malapposition with excessive fibrin depositon with PES (Otsuka et al. 2012). In-stent neoatherosclerosis is seen in both BMS and DES, but more frequently and earlier after DES implantation. The disruption of neoatherosclerotic neointima is another important predictor of very late ST (Nakazawa et al. 2011).

Premature cessation of thienopyrine is a strong predictor of ST after stent implantation (Airoldi et al. 2007, van Werkum et al. 2009). The clopidogrel resistance or CYP2C19 gene polymorphism may contribute to ST during uninterrupted DAPT therapy. However, current guidelines don't recommend the use of antiplatelet response or gene testing routinely to detect patients ST risk (Amsterdam et al. 2014, Windecker et al. 2014)

2.4.2.2 Stent thrombosis with different stents

In the early era of BMSs, an incidence as high as 20% was reported for ST. Better stents, better intervention techniques such as adequate stent sizing, high pressure post-dilatation and more efficient antiplatelet therapy decreased the incidence of ST during the first 30 days after BMS implantation to < 1%. Of those, over 80% occurred within the first two days of the PCI (Cutlip et al. 2001).

The efficacy of first-generation DESs in reducing ISR led to the increased use of SESs and PESs. Several studies showed an increased risk of LST after first-generation DESs (MCFadden et al. 2004, Joner et al. 2006, Lee et al. 2006, Pfistered et al. 2006), and a great concern over the safety of DESs arose (Cook et al. 2008). The risk of very late ST appeared to continue years beyond the first year after the implantation of a DES, with an annual ST incidence 0.5% in one study (Wenaweser et al. 2008, Vink et al. 2011). However, some studies did not establish differences in the incidence of ST between BMSs and DESs, and a comparable or even lower overall mortality with DES has been reported (Buchanan et al. 2012). Of note, long-term follow-up studies have also shown a very late ST risk with BMSs at the rate of 0.1% (Doyle et al. 2007).

To improve the safety, efficacy and stent delivery of DESs, second-generation DESs were developed with different antiproliferative agents, stent coating technologies and

smaller strut sizes and designs. Several studies and meta-analyses have demonstrated a lower risk of ST with second-generation DESs as compared to first-generation DESs (Sudhir et al. 2012). The durable polymer on the stent struts has been shown to provoke hypersensitivity reaction, and it can have an impact on local artery injury (Van der Giessen et al. 1996). Theoretically, arterial healing after the implantation of a stent with a biodegradable polymer or one without a polymer is better, presuming a lower rate of ST. So far however, studies have failed to demonstrate the superiority of these new type of DESs in terms of ST when compared to second-generation DESs with a durable polymer (Sudhir et al. 2012). In early studies with a completely bioresorbable scaffold, promising result regarding ST incidence have been reported (Serruys et al. 2009, Onuma et al. 2010, Diletti et al. 2013). In the recent ABSORB II study, 501 patients were randomized at a 2:1 ratio to receive either an everolimus-eluting bioresorbable scaffold or an everolimus-eluting metallic stent. In a one-year follow-up, three patients (0.9%) in the bioresorbable scaffold group and none in the metallic stent group had definite or probable ST (Serruys et al. 2015).

2.4.3 Bleeding complications

Peri- and post-procedural bleeding complications following coronary angiography and especially PCI are common adverse events (Moscucci et al. 2003, Budaj et al 2009). Bleeding complications are closely related to the intensity of antithrombotic therapy and are more common in PCI for ACS when antiplatelets and anticoagulants are used aggressively (Steg et al. 2011). Major bleeding episodes occur within 30 days after PCI in 0.7%–1.1% of elective, 0.6%–4.7% of NSTEMI and 0.9%–8.9% of STEMI patients, depending what definitions of major bleeding applied (Kwok et al. 2014). Haemorrhagic complications are associated with increased 30-day mortality, reinfarction and cerebrovascular events (Mamas et al. 2012). The bleeding may be fatal directly in the form of intracranial bleeding or by causing shock, or through ischaemic complications caused by the cessation of antiplatelet agents in response to bleeding. In the large meta-analysis of 42 studies by Kwok et al. including over half a million patients, major bleeding after PCI was associated with a threefold increase in mortality and MACEs, and this risk was sustained over a 12-month period (Kwok et al. 2014). A large proportion of haemorrhagic events occur at the vascular access site, and the use of a radial approach has been shown to decrease access site bleeding and vascular complications markedly in comparison to the femoral route (Jolly et al. 2009).

The common risk factors for bleeding are older age, female sex, lower body weight, invasive procedures and renal insufficiency. A possible explanation for the higher risk of bleeding with older patients is the weakening of the arterial wall with aging by collagen and amyloid deposits in the tunica media, causing vessel to become less inclined to constrict (Steg et al. 2011). In the GRACE registry, women with ACS had a 43% higher risk for in-hospital major bleedings than men (Moscucci et al. 2003). The increased

risk for bleeding in women might be caused by higher age, a smaller body and vessel size, a higher prevalence of comorbidities, reduced creatinine clearance and the fact that women are more likely to receive less recommended therapies (Alexander et al. 2005, Ndrepepa G et al. 2013). In renally impaired patients, platelet dysfunction, abnormalities in the coagulation cascade and excess dosing of antithrombotic drugs are plausible explanations for the increased bleeding risk (Remuzzi 1988).

2.4.3.1 Bleeding risk index

Several risk scoring systems have been developed to predict the risk of thromboembolic complications and bleeding in patients on long-term oral anticoagulation. The outpatient bleeding risk index (OBRI) considers a history of stroke, age > 65 years, a history of gastrointestinal bleeding and the presence of one or more specific comorbid conditions (recent myocardial infarction, renal insufficiency, severe anaemia or diabetes) (Beyth et al. 1998). In the modified outpatient bleeding risk index (mOBRI), previous stroke or gastrointestinal tract bleeding within two weeks is considered. In the HAS-BLED score, which is widely adopted in clinical use, hypertension, abnormal renal or liver function, stroke, bleeding history or predisposition, labile INR, as well as advanced age and drugs or alcohol concomitantly are calculated (Lip et al. 2011). The ATRIA score counts anaemia, renal insufficiency, age, hypertension and previous bleeding (Fang et al. 2011). In the REACH score, age, peripheral arterial disease, diabetes, hypercholesterolemia, congestive heart failure, type of oral anticoagulant used and former or current smoking habit yield risk points (Ducrocq et al. 2010). The HEMORR(2)HAGES score takes into account hepatic or renal disease, ethanol abuse, malignancy, older age, reduced platelet count or function, re-bleeding, hypertension, anaemia, genetic factors as well as excessive fall risk and stroke (Apostolakis et al. 2012). The CHADS₂ and CHA₂DS₂-VASc scores are used more to predict the stroke risk of AF patients, but stroke risk and bleeding risk are closely related, and CHADS₂ and CHA₂DS₂-VASc are also used as an indicator of bleeding risk. However, HAS-BLED seems to be superior in predicting the bleeding risk of patients on an uninterrupted anticoagulation (UAC) compared to CHADS₂ or CHA₂DS₂-VASc (Lip et al. 2011, Apostolakis et al. 2013, Roldán et al. 2013b). The HAS-BLED score outperforms the HEMORR(2)HAGES score or the ATRIA bleeding score in the prediction accuracy of bleeding and exhibits some predictive value for cardiovascular events and mortality in UAC patients (Apostolakis et al. 2012, Gallego et al. 2012, Roldán et al. 2013a). The usefulness of the risk scoring systems to predict outcome in AF patients undergoing PCI and receiving multiple antithrombotic drugs is scantily investigated. One study showed an association between a high HAS-BLED score and major bleeding episodes in AF patients after PCI (Ruiz-Nodar et al. 2012), while a report by Puurunen et al. failed to show the bleeding prediction power of the HAS-BLED (Puurunen et al. 2014). In a recent substudy of the AFCAS-registry in patients with AF undergoing PCI, the bleeding predictive performances of the bleeding risk scores were evaluated. Neither ATRIA, HAS-BLED, mOBRI nor REACH could predict bleeding complications in this patient subset (Kiviniemi et al. 2014).

2.4.4 Other complications

Certain other complications of PCI occur periprocedurally or soon after the intervention. Before the stent era, acute vessel closure was seen in 6.8%–13.6% of cases after balloon angioplasty (Cowley et al. 1984). It is caused by thrombus formation, coronary spasm or medial dissection of the coronary artery wall (Sutton et al. 1994). More aggressive antithrombotic therapy and the implantation of an intracoronary stent to move the intimal and medial flaps away from the lumen and to prevent elastic recoil diminished the rate of abrupt vessel closure markedly (Colombo et al. 1995). Periprocedural myocardial infarction occurs in 1% of PCIs, and emergency CABG is needed in 0.2%–0.3% of patients. The incidence of death is 0.2%, but higher in high risk patients. PCI is associated with an embolic stroke risk of roughly 0.5% (Grech 2003, Dauterman 2004). Allergy to the contrast medium is a rare complication, but contrast agent nephropathy is seen in 3%–7% of patients after PCI, and some patients need dialysis. Among those patients, 1-year mortality has been shown to be as high as 55% (McCullough 2006). The incidence of coronary perforation varies from 0.1% to 0.6% in PCI and can cause cardiac tamponade several hours after the procedure (Fasseas et al. 2004).

2.5 Coronary angiography and percutaneous coronary intervention during long-term anticoagulation therapy

2.5.1 Uninterrupted vs interrupted anticoagulation

More than 5% of patients undergoing PCI are estimated to be on long-term anticoagulation due to other underlying medical conditions, such as AF, mechanical valves and a recent or recurrent history of deep venous thrombosis or pulmonary embolism (Helft et al. 2006).

A temporary replacement of anticoagulation therapy by DAPT during PCI appears to increase adverse events (Lip et al. 2014). In a study of 426 AF patients on OAC, the non-use of anticoagulation markedly increased mortality after acute myocardial infarction (Ruiz-Nodar et al. 2008). A standard recommendation for AF patients on OAC has been the interruption of warfarin before coronary angiography and PCI to lower the periprocedural international normalized ratio (INR) to < 1.8 to reduce the bleeding and access site complications (Popma et al. 2001). For AF patients at low risk of thromboemboli who are undergoing surgical or diagnostic procedures that carry a risk of bleeding, discontinuing warfarin for up to 1 week without substituting heparin is considerable (January et al. 2014).

In patients with a high risk of thromboembolic complications, bridging therapy (BT) with unfractionated heparin or low-molecular-weight heparin has been recommended to cover the subtherapeutic levels of INR (Airaksinen et al. 2010a). However, these recommendations are based on circumstantial evidence rather than randomized trials or

large prospective datasets. Heparin BT has been used in patient with OAC undergoing an elective surgical or invasive procedure. In one study, 650 patients who required temporary interruption of warfarin because of an invasive procedure were observed using LMWH dalteparin as BT. Four thromboembolic events (0.6%), two deaths (0.3%) and six major bleeding episodes (0.9%) occurred during a mean of 14 days' follow-up (Douketis et al. 2004). In the REGIMEN registry study, patients received either UFH or LMWH as bridging therapy. 69 patients undergoing an elective surgical procedure were bridged with LMWH, and no thromboembolic events were reported after the operation. Two patients (2.9%) suffered major bleeding, and 11% were at a high risk of bleeding. Thromboembolic events occurred in 2.4 % of the UFH patients and 0.9% in the LMWH group, while major bleeding appeared in 5.5% and 3.3%, respectively (Spyropoulos et al. 2006). In another study, within 30 days after a dental procedure, major bleeding was registered in 7% of the patients using UFH and in 4% of the ones on LMWH as BT (Won et al. 2014).

The optimal strategy of BT with heparins is not established, and some studies have shown prolonged hospitalization, extra inconvenience of heparin administration, potential thromboembolism in association with subtherapeutic anticoagulation and possible increased bleeding events with BT. (Karjalainen et al. 2008). The recent meta-analyses of the perioperative anticoagulation strategy during cardiac implantable electronic device implantation showed a significantly increased risk of bleeding events in the heparin-bridged group compared to the OAC continuation group, with no statistical difference in thrombus occurrence (Du et al. 2014).

Performing PCI during uninterrupted oral anticoagulation (UAC) with an INR of 2.0–3.0 has been regarded as an alternative strategy to BT (Jamula et al. 2010). In a small prospective study of 23 patients undergoing diagnostic cardiac catheterization or PCI on UAC with an INR of 1.8–3.5, no minor or major bleedings or myocardial infarctions occurred during hospitalization (Jessup et al. 2003). A retrospective study of 523 patients showed major bleeding episodes and access site complications more commonly in interrupted versus UAC-treated patients (Karjalainen et al. 2008). In a multicentre prospective study of the AFCAS registry, the UAC versus BT strategies were compared in AF patients undergoing coronary stenting. There was a tendency towards increased overall bleeding complications in the BT group, but statistically significant differences were not found in major bleedings or major adverse cardiac and cerebrovascular events (MACCEs) between the groups, suggesting UAC as a simple and cost-effective alternative to heparin bridging (Lahtela et al. 2012). In the setting of elective PCI, no additional anticoagulation is recommended if the INR is > 2.5 .

Regardless of the timing of the last oral anticoagulant dose, additional parenteral anticoagulation is recommended in primary PCI patients on OAC. PCI through the femoral route is associated with an increased incidence of bleeding in patients on OAC, and the radial access is preferable (Schlitt et al. 2013, Windecker et al. 2014).

2.5.2 Management of long-term anticoagulation therapy after percutaneous coronary intervention

DAPT with aspirin and clopidogrel has been the standard antithrombotic therapy after PCI (Popma et al 2004). The optimal antithrombotic strategy after PCI for patients on long-term anticoagulation therapy is more challenging and still unclear, and the prognosis of warfarin-treated patients has been unsatisfactory irrespective of the antithrombotic combinations used (Karjalainen et al. 2007). Warfarin monotherapy with a high rate of adverse cardiac events is considered a poor therapeutic choice after coronary stenting (Leon et al. 1998). The combination of warfarin and aspirin after PCI is not effective in preventing ST and adverse cardiac events (Rubboli et al. 2005). The risk of thromboembolism is increased in AF patients on DAPT with aspirin and clopidogrel without warfarin therapy (Karjalainen et al. 2007). To avoid thromboembolic and ischaemic events, the addition of aspirin and clopidogrel to patients on warfarin therapy is recommended after PCI. However, this triple therapy is associated with an up to 45% annual bleeding risk (Dewilde et al. 2013). Triple therapy is recommended to be kept as short as possible to minimize the side effects, depending on the thromboembolic and bleeding risks, stent type and clinical setting of the patient (Rubboli et al. 2008).

The CHA₂DS₂-VASc and the HAS-BLED scores can be used to predict thromboembolism and bleeding episodes in AF patients undergoing PCI (Puurunen et al. 2014). In patients undergoing PCI with stable coronary artery disease and AF, with a CHA₂DS₂-VASc score of no less than 2 at low bleeding risk (HAS-BLED max 2), one month triple therapy is recommended, followed by OAC and clopidogrel for up to 12 months. In patients with ACS and AF with a HAS-BLED score of no more than 2, a duration of triple therapy of six months can be considered irrespective of stent type. Regardless of the clinical setting or stent type, one month of triple therapy is recommended for high-bleeding-risk patients (HAS-BLED minimum 3) with AF after PCI. To avoid gastrointestinal bleeding in patients at an increased risk, proton pump inhibitor therapy is recommended to be added to triple therapy even if there is no history of gastric bleedings. The target INR level of 2.0–2.5 during triple therapy may be reasonable (Amsterdam et al. 2010, Windecker et al. 2014).

There is sparse data on the use of prasugrel or ticagrelor in patients receiving triple therapy. The substitution of prasugrel for clopidogrel in triple therapy appears to increase the risk of bleeding (Sarafoff et al. 2013). Current guidelines do not recommend the use of prasugrel or ticagrelor as part of triple therapy.

In the WOEST trial, patients receiving anticoagulants and undergoing PCI were randomized to either double therapy (warfarin and clopidogrel) or triple therapy (warfarin, clopidogrel and aspirin). In the triple therapy group, more than 50% more bleeding complications occurred in comparison to double-therapy-treated patients over a one year period with comparable numbers of thrombotic and thromboembolic events (Dewilde et al. 2013). A retrospective registry of more than 12,000 real-life AF patients

confirmed the efficacy and safety of warfarin and clopidogrel after PCI (Lamberts et al. 2013). The results of two smaller registries further support the findings of the WOEST trial (Seivani et al. 2013, Rubboli et al. 2014).

2.5.3 Novel anticoagulants

Recent US and European guidelines recommend the use of novel oral anticoagulants (NOACs) for nonvalvular atrial fibrillation (Camm et al. 2012, January et al. 2014). The efficacy and safety of NOACs as antithrombotic therapy in patients with coronary heart disease and a need for antiplatelet therapy have been investigated intensively during the last years (Thompson et al. 2014). Ximelagatran, a direct thrombin inhibitor, was the first NOAC to demonstrate cardiovascular benefit in the treatment of post-MI patients (Wallentin et al. 2003). However, the agent had to be withdrawn from the market due to hepatotoxicity.

Apixaban, rivaroxaban and darexaban are oral direct Xa inhibitors. In the phase II APPRAISE trial, stable post-MI patients were treated with four different apixaban doses. Most of the patients received aspirin, and >75% also clopidogrel. Apixaban's dose-dependently increased bleeding rate was reported without statistical benefit in regard to adverse cardiovascular events (Alexander et al. 2009). The APPRAISE II trial also showed an increased bleeding risk and failed to demonstrate a reduction in ischaemic events when apixaban was combined with aspirin, or DAPT with aspirin and clopidogrel in ASC patients. The trial was terminated prematurely (Alexander et al. 2011).

In the ATLAS ACS-TIMI 46 and the ATLAS ACS-TIMI 51 trials, rivaroxaban was evaluated in ACS patients. Rivaroxaban combined with aspirin or DAPT reduced deaths, MIs and strokes, at the cost of a dose-dependent increase in bleeding episodes (Mega et al. 2009 and 2012). The RUBY-1 trial demonstrated increased bleeding in a dose-dependent manner in ACS patients treated with darexaban (Steg PG et al. 2011).

Dabigatran is a reversible, direct thrombin inhibitor. The role of dabigatran in the treatment of ACS was examined in the RE-DEEM study (Oldgren et al. 2011). In the dabigatran group, a 2–4-fold increase in bleeding events occurred when combined to DAPT, while the trial was not powered to assess ischaemic endpoints.

In the family of NOACs, voraxapan and atopaxar are PAR 1 antagonists. The TRACER trial showed an unacceptably high risk of bleeding complications in ACS patients when voraxapan was added to concomitant DAPT (Tricoci et al. 2012). Combining atopaxar to aspirin and thienopyridine did not increase major or minor bleeding complications, but a reduction in MACEs was not established in the LANCELOT-ACS trial (O'Donoghue et al. 2011).

According to the trials, the addition of a NOAC to antiplatelet therapy in the group of patients with a recent ACS might reduce cardiovascular events but increase the risk of

bleedings especially when dual anti-platelet therapy with aspirin and clopidogrel is used (Oldgren et al. 2013). The efficacy and safety of a combination of ticagrelor or prasugrel and NOACs have not been examined.

2.6 Optical coherence tomography

2.6.1 Technique

The first OCT was 1-dimensional low-coherence reflectometry, which used a Michelson interferometer and a broadband light source. In the early 1990s, a transverse scanning (B scan) was added, enabling 2-dimensional imaging of the retina (Huang et al. 1991). Intravascular OCT requires a fiberoptic wire that both emits a near-infrared light and records the reflection while rotating and being pulled back along the artery. Cross-sectional images are generated by measuring the echo time delay and intensity of the light reflected or back-scattered from internal structures in the tissue (Prati et al. 2010). Two types of OCT systems exist. The time-domain OCT was developed first, and second-generation systems are known as frequency-domain OCT, the main difference being the method used to calculate the electric field amplitude (Ferrante et al. 2013).

OCT cannot image through a blood field, as it requires the clearing or flushing blood from the lumen. In the occlusive technique, coronary blood flow was stopped by inflating a proximal occlusion balloon and flushing crystalloid solution through the end-hole of the balloon catheter. The arterial occlusion can cause haemodynamic instability or arrhythmias. Moreover, balloon-vessel size mismatch or backward blood flow from well-developed collaterals can affect image clarity. Ostial or very proximal lesions are not suitable for imaging with the occlusive technique (Prati et al. 2010). The frequency-domain OCT system performs with a non-occlusive technique, avoiding ischaemia-induced complications. Intracoronary contrast injection during image acquisition is still needed to achieve adequate displacement of red blood cells (Ferrante et al. 2013).

2.6.2 OCT versus IVUS

OCT is an imaging modality analogous to ultrasound imaging, but the speed of light used (3×10^8 m/s) is much faster than that of sound (1500 m/s). OCT imaging provides an axial resolution of 12–18 μm , compared with the 150–200 μm of intravascular ultrasound (IVUS) (Lowe et al. 2011). The penetration depth of OCT in most tissue types is limited to 1–3 mm, while IVUS can reach tissues to 10 mm, with the exception of calcified lesions in which sound has a limited penetration (Bezerra et al. 2009). The frequency-domain OCT systems have a higher catheter pull-back speed, up to 36 mm/s in the new commercially available technology the ILUMIEN™ OPTIS™ (Light Lab Imaging, USA), in comparison to the time-domain OCT systems with a maximum speed of 3 mm/s and IVUS with 1 mm/s, reducing the time required for image acquisition.

2.6.3 Use in clinical practice

The term “vulnerable plaque” was created in reference to coronary stenosis that did not appear significant in angiography but later caused an acute MI (Muller et al. 1989). In autopsy studies of acute coronary patients, certain histological findings have been associated with high-risk plaques: the presence of thin fibrous caps (<65µm), large lipid cores presenting more than 40% of the overall plaque volume, and increased infiltration of macrophages into a plaque cap. In addition, positive remodelling of the effected vessel, increased vasa-vasorum neovascularization, and intraplaque haemorrhage have been linked to vulnerable plaques (Burke et al. 1997). The resolution capability of OCT makes it the only modality that allows the identification and measurement of the thin fibrous cap of vulnerable plaques (Kubo et al. 2007). In one report, compared to histopathology, the thin cap fibroatheroma was diagnosed with 90% sensitivity and with 79% specificity using OCT imaging (Karjalainen et al. 2012). The ability of OCT to distinguish lipid-rich plaques, fibrocalcific plaques and fibrous plaques has been confirmed, and in studies on patients presenting with ACS, OCT has been able to identify lipid-rich culprit plaques in 90% patients with STEMI as opposed to 60% of patients with stable angina (Abtahian et al. 2012). In autopsy studies, OCT has successfully identified plaques with a greater than 10% macrophage density (CD68 positivity with immunohistochemistry) within the fibrous cap (Tearney et al. 2003). This technique has been successfully used for the measurement of macrophage densities in vivo (MacNeill et al. 2004). Microchannels that appear in OCT as tubuloluminal structures with no signal in thin capped plaques are believed to represent neovascularization, and associate plaque progression to the thin cap fibroatheroma over 7-month follow-up (Abtahian et al. 2012). ACS can be caused by plaque rupture or plaque erosion. OCT has been found to detect fibrous cap disruption and superficial plaque erosion significantly better than coronary angiography and IVUS (Kubo et al. 2007). Intravascular thrombi can easily be identified by OCT. A study of human cadavers showed that thrombi can be further distinguished by OCT images platelet-rich white thrombi and red-blood-cell-rich red thrombi (Kume et al. 2006).

OCT has heralded a new era in guiding PCI. In the OPUS-CLASS Study, the frequency-domain OCT provided accurate and reproducible quantitative measurements of coronary dimensions when compared with IVUS and angiography (Kubo et al. 2013). Before PCI, the length of the lesion, minimal luminal diameter and area, diameter of the reference vessel as well as the percentage of lumen obstruction and of neointimal hyperplasia can be measured with OCT.

The lesion severity and possible post-PCI complications can be approximated by defining plaque characteristics with a similar accuracy to IVUS (Abtahian et al. 2012). OCT is remarkably accurate at identifying post-stenting complications. The frequency-domain OCT has been found to be much more sensitive than IVUS in detecting intrastent tissue protrusion, stent strut malapposition, stent edge dissection and intrastent thrombus (Kubo et al. 2013). A remarkably high proportion of stent struts in malapposition has been reported even after high-pressure post-dilatation (Tanigawa et al. 2008). In long-term

follow of stents, malapposition associates with PCI failure (Cook et al. 2005). ISR tissue characterization can be accomplished with OCT. Very late ISR appears to be secondary to neoatherosclerosis, while early ISR is caused by NIH with BMSs (Takano et al. 2009). Neoatherosclerosis was seen earlier in DESs when compared to BMSs (Kang et al. 2011).

2.6.4 Vascular healing in OCT

The post-stenting neointimal healing response largely depicts the clinical and angiographic outcomes. Incomplete neointimal coverage of stent struts is considered to be a risk for stent thrombosis (Finn et al. 2007). OCT can reliably visualize early and very thin layers of neointimal coverage over stent struts (Karjalainen et al. 2012). However, despite the high sensitivity, OCT does not allow the direct imaging of the luminal endothelial layer. In a newly developed form of OCT, termed micro-OCT, with the axial resolution of 1 μ m, the imaging of coronary artery microstructures at a scale comparable to histopathology is possible (Liu et al. 2011). DESs are found to have significantly more uncovered struts than BMSs in long-term follow-up (Chen et al. 2008, Guagliumi et al. 2011), and differences between the various DESs appear in favour of the second-generation DESs compared to first-generation DESs (Choi et al. 2012, Kim et al. 2009, Takano et al. 2013, Toledano Delgado et al. 2013).

The endothelial progenitor cell-capturing stent has demonstrated 95% strut coverage after 30 days' follow-up (Lehtinen et al. 2012). In the TITAX-OCT study, binary stent strut coverage was significantly higher in the titanium-nitride-oxide-coated bio-active stent (BAS) compared to a PES at a mean of 47 months after stent implantation (Lehtinen et al. 2012). After 9-month follow-up, a BAS resulted in improved neointimal stent strut coverage as compared to an everolimus-eluting stent (Karjalainen et al. 2013).

3. AIMS OF THE STUDY

The specific aims were:

1. To assess the safety and feasibility of diagnostic coronary angiography during uninterrupted warfarin therapy (I).
2. To compare the long-term safety of drug-eluting stents and bare metal stents in patients on warfarin treatment (II).
3. To assess the value of an outpatient bleeding risk index (OBRI) in predicting bleeding events and prognosis during long-term follow-up after PCI and to investigate whether bleeding risk modifies contemporary treatment choices in this patient group (III).
4. To explore the extent of neointimal coverage of stent struts by optical coherence tomography (OCT) at 30 days following the implantation of BASs in an unselected non-diabetic population (IV).
5. To evaluate long-term clinical outcome in patients treated with titanium-nitride-oxide-coated stents and paclitaxel-eluting stents (V).

4. MATERIALS AND METHODS

4.1 Study design and subjects

In paper I, consecutive patients on long-term warfarin therapy (n = 258) referred for coronary angiography from 2003 through 2005 in 2 centres with long experience in uninterrupted warfarin therapy during coronary angiography and in 1 centre with a policy of preprocedural warfarin pause were analysed retrospectively. In addition, an age- (± 5 years) and sex-matched control group with no OAC and with a similar indication (acute/elective) for coronary angiography in each hospital during the same study period was collected. Matching was perfect with the exception of two cases with a sex mismatch and 12 cases with an indication mismatch.

The analyses in papers II and III were based on information collected in six Finnish hospitals including 415 (II) and 421 (III) consecutive patients on chronic warfarin treatment who underwent coronary stenting between the years 2002 and 2006. All patients were treated according to varying local practices and followed with the last contact being from September 2008 to February 2009. The major bleeding episodes and MACCE and medications at the time of the episode were recorded.

Paper IV explored the extent of the neointimal coverage of stent struts by means of OCT following the implantation of a BAS (Titan-2[®]). Twenty consecutive patients older than 18 years, with at least one significant coronary lesion defined as an at least 50% diameter stenosis by visual estimation in a native coronary artery, were enrolled. The main exclusion criteria included diabetes mellitus, unprotected left main or aorto-ostial lesions, in-stent restenosis, the required stent length of >28 mm, and contraindication to aspirin, clopidogrel, or heparin.

Paper V is based on a patient registry collected at Satakunta Central Hospital in Finland between May 2003 and November 2004. Consecutive patients with symptoms or signs of myocardial ischaemia and de novo coronary lesion(s) and scheduled for stent implantation were considered for this registry. A total of 405 patients fulfilled the criteria and entered this study. A total of 201 patients received one or more BAS (Titan-2[®]) exclusively, and 204 received one or more PESs (Taxus[®]). This patient population comprised 63% of all patients who underwent PCI during the study period. In addition to the original study population, baseline data on patients receiving BMS(s) during the index study period at Satakunta Central Hospital were gathered, and these patients were also followed for up to 3 years. Similar data from patients undergoing CABG were also collected. The clinical events after clopidogrel discontinuation in all patients undergoing a PCI with stent implantation were evaluated. All patients who were MACE-free at the time of clopidogrel discontinuation were followed for an additional 12 months after the clopidogrel withdrawal.

The study protocols were approved by the Ethics Committees of Satakunta Central Hospital (I–V) and the participating hospitals (I–III).

4.2 Methods

4.2.1 Coronary angiography and percutaneous coronary intervention

In papers I, II and III, the procedure was performed according to the standard technique using either the radial or the femoral approach. Periprocedural antithrombotic therapies employed were selected according to the various centres' practices.

In paper V, all patients were pre-treated with aspirin 100 mg daily and received intravenous enoxaparine 1 mg/kg during the procedure. Oral clopidogrel was administered as a loading dose of 300 mg before or immediately after the procedure. Patients treated with a PES were prescribed a minimum of 6 months of clopidogrel 75 mg per day. For patients treated with a BAS, clopidogrel was prescribed for a minimum of 3 months. Lesions were treated according to standard interventional techniques, with the final strategy (thrombectomy devices, direct stenting, postdilatation, periprocedural glycoprotein IIb/IIIa inhibitor, intravascular ultrasound) left entirely up to the operator's discretion. Angiographic success was defined as a residual stenosis of < 30% by visual analysis in the presence of Thrombolysis In Myocardial Infarction flow grade 3.

4.2.2 Outpatient bleeding risk index

Bleeding risk was evaluated retrospectively with the outpatient bleeding risk index (OBRI), which considers a history of stroke, age >65 years, history of gastrointestinal bleeding, the presence of ≥ 1 co-morbid condition (recent myocardial infarction [MI], renal insufficiency, severe anaemia, or diabetes) to stratify patients into 3 risk groups. Based on this classification, a patient is considered to be at a low (0 risk factor), moderate (1 risk factor or 2 risk factors), or high (3 to 4 risk factors) risk for bleeding.

4.2.3 OCT

In paper IV, OCT images were obtained with the C7-XR frequency-domain system (LightLab Imaging, Inc) employing the non-occlusive technique. OCT images were analysed offline in a core laboratory independently by two experienced investigators blinded to the patients' baseline, angiographic and procedural data, employing the proprietary software (OCT system software B.0.1; LightLab Imaging, Inc). Stent strut coverage, strut apposition, neointimal hyperplasia (NIH), and possible thrombosis were evaluated at 1 mm intervals (every fifth frame) in cross-sectional images. All cross-sectional images were initially screened for quality assessment, and if the image quality

was insufficient to allow reliable measurements, a subsequent (or preceding) cross-section with adequate quality was evaluated.

4.2.4 End point definitions

In studies I, II and III, the end points were MACCE and major bleeding, in addition to access site complications in study I. In study I, MACCE was defined as the occurrence of any of the following: death, myocardial infarction and/or stroke during hospitalization. Myocardial infarction was diagnosed if any increase in a myocardial injury marker level (troponin I or T) was detected with the symptoms suggestive of acute myocardial ischaemia. For the diagnosis of myocardial reinfarction, a new increase of > 50% in baseline injury marker level was demanded. During follow-up, in studies II and III (median 3.5 years in both studies), MACCE also included target vessel revascularization (TVR) and ST. TVR was defined as any reintervention driven by any lesion located in the stented vessel. ST was classified according to the consensus of the Academic Research Consortium criteria as definite, probable or possible (Cutlip et al. 2007) (II), or ST was diagnosed based on angiographic evidence of a thrombotic occlusion or thrombi within the stent or in autopsy (III). Stroke was defined as an ischaemic cerebral infarction caused by a thrombotic occlusion of a major intracranial artery or intracerebral haemorrhage (II,III). In study III, Periprocedural MI was not routinely screened, but if procedural MI was suspected, a troponin level >3 times the normal 99th percentile level was required for the diagnosis. Major bleeding was defined as a decrease in blood haemoglobin level of > 4.0 g/dl, the need for transfusion of ≥ 2 U of blood, need for corrective surgery, the occurrence of an intracranial or retroperitoneal haemorrhage, or any combination of these events (I-III). Vascular access site complications included pseudoaneurysm, arteriovenous fistula, retroperitoneal haemorrhage, the need for corrective surgery, the need for transfusions, and prolonged hospitalization due to haematoma in study I.

In study IV, the study endpoints were strut apposition, binary stent strut coverage and NIH thickness at 30 days' follow-up after BAS implantation. The apposition status and tissue coverage of each analysed strut was classified on a binary scale, thus creating four categories of struts: (a) apposed and covered; (b) apposed and uncovered; (c) malapposed and covered; and (d) malapposed and uncovered. Struts overlying an ostium of a side branch were labelled as non-apposed side-branch struts and excluded from the analysis. Struts were classified as uncovered if any part of the strut was exposed to the lumen with no visible tissue coverage, or covered if a layer of tissue was visible over the reflecting surfaces. For covered struts, the NIH thickness was measured. Binary stent strut coverage was defined as the percentage of covered struts of all analysed struts. The incomplete stent apposition distance was measured for protruding struts as previously described. The distance of 110 μm to define malapposition was adopted, by adding a margin of 18 μm as a correction for half of the blooming effect to the 91 μm strut thickness of the BAS. The sum was rounded up to a full 10 microns regarding the

axial resolution of frequency-domain OCT. Lumen and stent contours were traced semi-automatically or manually and the NIH area was calculated by subtracting the lumen's cross-sectional area from the stent cross-sectional area. The NIH area percentage was calculated by dividing the NIH area by the stent's cross-sectional area and multiplied by 100. If the lumen or stent cross-sectional areas were not measurable, they were omitted.

In study V, the primary endpoint was MACE, defined as the first occurrence of any of the following during the follow-up: death from cardiac causes, Q-wave or non-Q-wave myocardial infarction (MI), or TVR (emergency or elective coronary-artery bypass grafting or repeated coronary angioplasty). A Q-wave MI was defined as either (1) the presence of chest pain or other acute symptoms consistent with myocardial ischaemia and new pathologic Q waves in ≥ 2 continuous electrocardiographic leads, or (2) elevated cardiac enzyme levels > 2 times the upper limit of normal associated with any elevation above the upper limit of normal in creatine kinase-MB levels in the presence of new pathologic Q waves. A non-Q-wave MI was defined as an elevated creatine kinase > 2 times the upper limit of normal associated with any elevation above the upper limit of normal in creatine kinase-MB levels. TLR was defined as a repeat intervention to treat a stenosis within the stent or in the segments 5 mm distal or proximal to the stent. TVR was defined as a reintervention driven by any lesion located in the stented vessel. ST per-protocol was diagnosed in the presence of an acute coronary syndrome with angiographic evidence of either vessel occlusion or thrombus within the study stent, or in autopsy.

4.2.5 Clinical data and follow-up

In study I, all medical records of consecutive patients on long-term warfarin therapy referred to coronary angiography were reviewed retrospectively to evaluate rates of access site complications, major bleeding and MACCE during hospitalization. An age- and sex- matched control group with a similar indication for coronary angiography during the same study period was collected. The length of hospitalization and patient baseline characteristics including indications for warfarin therapy and periprocedural antithrombotic therapy as well as the annual stroke risk of patients with nonvalvular AF using the CHADS₂ scoring were recorded.

In studies II and III, the long-term outcomes of consecutive warfarin-treated patients who underwent DES or BMS stenting were analysed. Baseline and in-hospital data were collected from local institutional clinical computerized databases. Furthermore, a non-blinded review of full medical records of the eligible patients was performed to determine the perioperative antithrombotic strategies and the incidence of in-hospital complications. All patients were followed by office visits or telephone interviews by the treating physicians. All data available from the hospital records and the institutional electronic clinical database were checked at the end of the follow-up period to record the medication at the time of MACCE and major bleeding. Hospital records and death certificates from Statistics Finland were used to record and classify deaths.

In study IV, all patients underwent follow-up coronary angiography with OCT examination of the index vessel at an average of one month postoperatively.

In study V, all patients underwent clinical follow-up. Adverse events were monitored at hospital discharge and by office visits or telephone interviews by the cardiologist at one and three years. All data available from hospital records, the institutional electronic clinical database and the referring physicians were checked at the end of the follow-up period and entered into the computer database. Follow-up angiography was clinically driven by symptoms or signs suggestive of myocardial ischaemia. The indication for repeat revascularization was a significant luminal stenosis (> 50% diameter stenosis) in the presence of angina symptoms and/or proven myocardial ischaemia in the target vessel territory

4.2.6 Statistical analyses

In paper I, continuous variables are presented as mean (SD) and study groups were compared by Student's unpaired t test. Categorical variables are presented as counts and percentages and were compared by the chi square or Fisher's exact test. Multivariable logistic regression analyses were performed to identify independent predictors for access site and bleeding complications in the OAC group. Variables considered for the model included age, sex, disease type (acute vs stable), access site, INR level, use of low-molecular-weight heparin bridging and warfarin pause. The adequacy of the model was ascertained using the Hosmer and Lemeshow Goodness-of-Fitness test. Results are presented as odds ratios (OR) with 95% confidence intervals (CI). A two-sided p value < 0.05 was required for statistical significance.

In paper II, Continuous variables were presented as mean \pm standard deviation, while categorical variables were described with absolute and relative (percentage) frequencies. Continuous variables such as stent area, lumen area, NIH area and NIH thickness were estimated as medians which were used for analysis. This has been done because the number of measurements of stent area and lumen area for each stent was rather small (mean, 17 ± 6 ; median, 17; range, 4 to 29). The results of pooled analyses were expressed as pooled proportions (%). Because heterogeneity was anticipated in observational studies, it was assessed a priori by a random effects model (DerSimonian-Laird). Inter-observer variability was assessed by evaluating 50 random cross-sectional images by two independent investigators.

In paper III, categorical variables are presented as numbers and percentages and were compared with the chi-square or Fisher's exact test where appropriate. Continuous variables are presented as means \pm SDs and differences between study groups were tested with analysis of variance and a Bonferroni correction was performed to account for multiple comparisons. MACCEs, major bleeding episodes, and all-cause deaths were analysed with Kaplan-Meier survival curves during follow-up, and differences between

groups were compared using the log-rank test. After univariate analyses, logistic multivariable regression analysis was performed to identify independent predictors for major bleeding and MACCEs in the entire study population. Because of multiple testing, only variables with a 2-sided p value of < 0.05 in univariate analysis were accepted for the model. Results are presented as odds ratios (ORs) with 95% confidence intervals.

In paper IV, the normally distributed continuous variables are shown as mean \pm standard deviation and were compared by the unpaired t test; other continuous variables are shown as median and interquartile range and compared with the Mann–Whitney U test. Dichotomous variables and outcome end points are presented as counts and percentages and compared with the chi-square test and Fisher's exact test. A two-sided p value of < 0.05 was considered statistically significant. Survival analyses were performed by means of the Kaplan–Meier test, and differences between groups were assessed using the log-rank test. In propensity score analyses, logistic regression with backward selection was performed to calculate the risk of these patients to be 'assigned' to the BMS or DES group. Variables listed in Table I with $p < 0.2$ have been included into the regression model. Receiver operating characteristic (ROC) curve analysis was used to estimate the area under the curve of the model predicting the probability of being included in the DES or the BMS group. The calculated propensity score was employed for one-to-one matching as well as to adjust for other variables in estimating their impact on the postoperative outcome. Matching between study groups was done according to a difference in the propensity score of < 0.005 . Cox regression analysis with backward selection was used to adjust the effect of clinical variables as well as propensity score on outcome end points.

In paper V, continuous variables are presented as mean (SD) and groups were compared with the aid of the Student's unpaired t-test. Categorical variables are presented as counts and percentages and associations between categorical variables were compared by the chi-square or Fisher's exact test. Variables significantly ($p < 0.05$) associated with clinical events in univariate Cox proportional hazards regression models, were included in multivariable Cox regression analysis to identify independent predictors for clinical events during the 3 year follow-up. Propensity scores were used to adjust for potential bias in the comparison between non-randomized BAS and PES groups. Propensity scores were calculated as the predicted probability of patients being treated with a PES as opposed to BAS using logistic regression. The differences between BAS and PES groups in outcome variables were compared after adjustment for propensity score (linear term) by using Cox regression analysis. Propensity score was also included in multivariable models. The variables included in the propensity score model and Cox regression models were age, sex, diabetes, current smoking, hypercholesterolemia, hypertension, previous MI, previous PCI, previous CABG, multivessel disease, acute ST-elevation MI, acute non-ST-elevation MI, unstable angina, stent diameter, stent length, and glycoprotein IIb/IIIa inhibitor. A two-sided p value of < 0.05 was required for statistical significance. All-cause death, TVR, MI and MACE were analysed by means of Kaplan–Meier survival

curves during the three years of follow-up, and the differences between groups were compared using log-rank test.

All data in study V were analysed with the use of SPSS version 11 (SPSS Inc., Chicago, Illinois, USA) and the SAS system for Windows version 9.1 (SAS Institute Inc., Cary, NC, USA). The data in studies I and II were analysed with the use of SPSS version 15.0 for Windows, and in studies III and IV with SPSS version 16.0.1. In study IV, the pooled analysis of measurements was performed using Meta-analyst Beta 3.13 software (http://tuftscaes.org/meta_analyst/) in order to account for clustering in view of the large number of measurements obtained by OCT, and hence to arrive an estimation of binary stent strut coverage, the frequency of malapposed struts, and NIH thickness.

5. RESULTS

5.1 The safety and feasibility of diagnostic coronary angiography during uninterrupted warfarin therapy (I)

A total of 258 patients with an indication of long-term warfarin therapy underwent coronary angiography. An age- and sex-matched control group (n = 258) with similar disease presentation (unstable or stable symptoms) was collected. Baseline clinical characteristics are shown in **Table 1**.

Table 1. Baseline clinical characteristics.

	Warfarin (n=258)	Control (n=258)	p value
Men	177 (69%)	176 (68%)	1.0
Age (years)	66 ± 10	66 ± 10	1.0
Diabetes mellitus	53 (21%)	58 (22%)	0.67
Hypercholesterolemia	129 (50%)	177 (67%)	<0.001
Current or ex-smoker	59 (23%)	72 (28%)	0.23
Hypertension	146 (57%)	157 (61%)	0.37
Heart failure	93 (36%)	32 (12%)	<0.001
Stroke	40 (16%)	12 (5%)	<0.001
Myocardial infarction	69 (27%)	74 (29%)	0.70
PCI	23 (9%)	22 (9%)	1.0
Indication for angiography			
Stable angina pectoris	212 (82%)	200 (78%)	0.23
STEMI	5 (2%)	18 (7%)	0.01
NSTEMI	25 (10%)	19 (7%)	0.43
Unstable angina pectoris	16 (6%)	21 (8%)	0.50

PCI, percutaneous myocardial infarction; STEMI, ST-elevation myocardial infarction; NSTEMI, non-ST-elevation myocardial infarction. Modified from original publication I.

Radial access was used in 56% of patients in the warfarin group and in 60% of controls (p = 0.21). There was no difference in access site and bleeding complications (1.9% vs 1.6%) or major adverse cardiovascular and cerebrovascular events (0.4% vs 0.8%) between the warfarin group and their controls.

Warfarin was interrupted in 80 patients (31%), and bridging therapy was used in 24 of these patients (30%). INR levels were higher in the uninterrupted warfarin group (2.3 vs 1.9, p < 0.001), but the incidence of access site complications was not higher (1.7%) than in patients with a warfarin pause (2.5%) or in patients with pause and

bridging therapy (8.3%). The need for blood transfusions ($n = 2$) occurred only in patients with bridging therapy. Access site complications were more common in the 22 patients with suprathreshold anticoagulation ($\text{INR} > 3$) than in patients with therapeutic periprocedural INR (9.1% vs 1.5%, $p < 0.05$).

5.2 The long-term safety of drug-eluting stents and bare metal stents in patients on warfarin treatment (II)

In study II, the long-term outcome of 415 consecutive warfarin-treated patients who underwent DES ($n = 191$) or bare-metal ($n = 224$) stenting in six hospitals were analysed. The mean duration of triple therapy was longer (4.2 ± 3.1 versus 2.1 ± 1.8 months; $p < 0.001$) in the DES group. The incidence of MACCE was comparable in the DES and bare-metal groups (39.8% versus 42.4%; $p = 0.59$) during a median follow-up of 3.5 years. Similarly, major bleeding events occurred equally often in both study groups (14.7% versus 12.9%). Six patients in the DES group and seven patients in the bare-metal group suffered ST (3.1% versus 3.1%).

There were no significant differences in the periprocedural antithrombotic treatments (unfractionated heparin, low-molecular-weight heparins, glycoprotein blockers or level of oral anticoagulation) between the groups. The antithrombotic medication at hospital discharge is described in **Table 2**.

At discharge, 58% in the BMS group and 62% of the DES patients received triple therapy, and 30% in the BMS group and 31% in the DES received dual therapy where clopidogrel was combined with aspirin or warfarin. The mean duration of triple therapy was shorter in the BMS group.

Table 2. Antithrombotic medication at discharge and duration of major treatment options.

	BMS (n=224)	DES (n=191)	P
Aspirin + clopidogrel	30 (13.4%)	36 (18.8%)	0.14
Triple therapy	129 (57.6%)	119 (62.3%)	0.37
Warfarin + aspirin	28 (12.5%)	12 (6.3%)	0.04
Warfarin + clopidogrel	37 (16.5%)	23 (12.0%)	0.21
Warfarin monotherapy	0	1 (0.5%)	NS
Duration of triple therapy, months	2.1 ± 1.8	4.2 ± 3.1	< 0.0001
Duration of clopidogrel therapy, months	4.6 ± 7.6	6.6 ± 6.8	0.01
Duration of warfarin + aspirin combination, months	11.6 ± 16.7	17.3 ± 19.4	0.37

BMS, bare metal stent; DES, drug-eluting stent; triple therapy, warfarin + aspirin + clopidogrel. Modified from original publication II.

In the propensity score analyses of 101 matched pairs, the outcome was similar in both stent groups, as demonstrated in **Table 3**.

Selective use of a DES with a short triple therapy seems to be safe in patients with warfarin therapy. The prognosis of this patient population is quite unsatisfactory, and major bleeding events are common irrespective of stent type.

Table 3. Outcome events in propensity-matched pairs according to the stent type.

	BMS (n=101)	DES (n=101)	p
MACCE, n (%)	43 (42.6)	40 (39.6)	NS
Myocardial infarction	9 (8.9)	17 (16.8)	NS
All-cause death	24 (23.8)	16 (15.8)	NS
TVR	10 (9.9)	11 (10.9)	NS
Redo PCI	15 (14.9)	26 (25.7)	0.05
CABG	6 (5.9)	4 (4.0)	NS
Stroke/TIA	10 (9.9)	6 (5.9)	NS
Stent thrombosis	2 (2.0)	5 (5.0)	NS
Cardiac death, n (%)	15 (14.9)	9 (8.9)	NS
Major bleeding, n (%)	13 (12.9)	18 (17.8)	NS

MACCE, major cardiac and cerebrovascular events; TVR, target vessel revascularization; PCI, percutaneous coronary intervention; CABG, coronary artery bypass grafting; TIA, transient ischaemic attack. Modified from original publication II.

5.3 The value of an outpatient bleeding risk index (OBRI) in predicting bleeding events and prognosis during long-term follow-up after PCI and the impact of OBRI on treatment choices (III)

A total of 421 patients with OAC underwent PCI, and complete follow-up was achieved in all patients (median 1,276 days). Most patients were in the moderate or high bleeding risk group. OBRI had no significant effect on periprocedural or long-term antithrombotic medications, choice of access site, or stent type. During follow-up, 59 (14.0 %) patients had major bleeding episodes. Although there were no differences in in-hospital bleeding events between the OBRI categories, the incidence of major bleeding increased ($p = 0.02$) progressively with higher OBRI category during the follow-up; **Table 4**. Most bleeding events occurred shortly after PCI; **Figure 1**. Mortality was highest in patients with a high OBRI (14.1%, 20.7%, and 39.5%, respectively, $p = 0.009$), but the rates of major adverse cardiovascular and cerebrovascular events were comparable between the OBRI categories.

In multivariable analyses, old age (OR 1.04, 95% CI 1.00–1.08, $p = 0.03$), absence of hypercholesterolemia (OR 0.34, 95% CI 0.19–0.64, $p < 0.001$), non-ST-elevation MI (OR 2.13, 95% CI 1.10–4.12, $p = 0.03$), and baseline creatinine level (OR 1.01, 95% CI

1.00–1.01, $p < 0.001$) predicted major bleeding. Old age (OR 1.03, 95% CI 1.00– 1.05, $p = 0.03$), heart failure (OR 1.72, 95% CI 1.04–2.83, $p = 0.04$), previous MI (OR 1.90, 95% CI 1.24–2.90, $p = 0.003$), and ST-elevation MI (OR 3.38, 95% CI 1.63–7.02, $p = 0.001$) were the only independent predictors of MACCEs.

Patients with a high OBRI often have major bleeding episodes and OBRI appeared to be suitable for risk evaluation in this patient group.

Table 4. Major bleeding and medication at the time of major bleeding according to the outpatient bleeding risk index.

	OBRI 0 (n=64)	OBRI 1-2 (n=319)	OBRI 3-4 (n=38)	p
Major bleeding	4 (6%)	45 (14%)	10 (26%)	002
Medication at the time of major bleeding				
Warfarin	1 (25%)	14 (31%)	3 (30%)	NS
Warfarin + aspirin	1 (25%)	12 (27%)	3 (30%)	NS
Warfarin+ clopidogrel	0	5 (11%)	0	NS
Aspirin + clopidogrel	0	1 (2%)	0	NS
Aspirin	0	3 (7%)	0	NS
Triple therapy	2 (50%)	10 (22%)	4 (40%)	NS

Triple therapy, warfarin + aspirin + clopidogrel. Modified from original publication III.

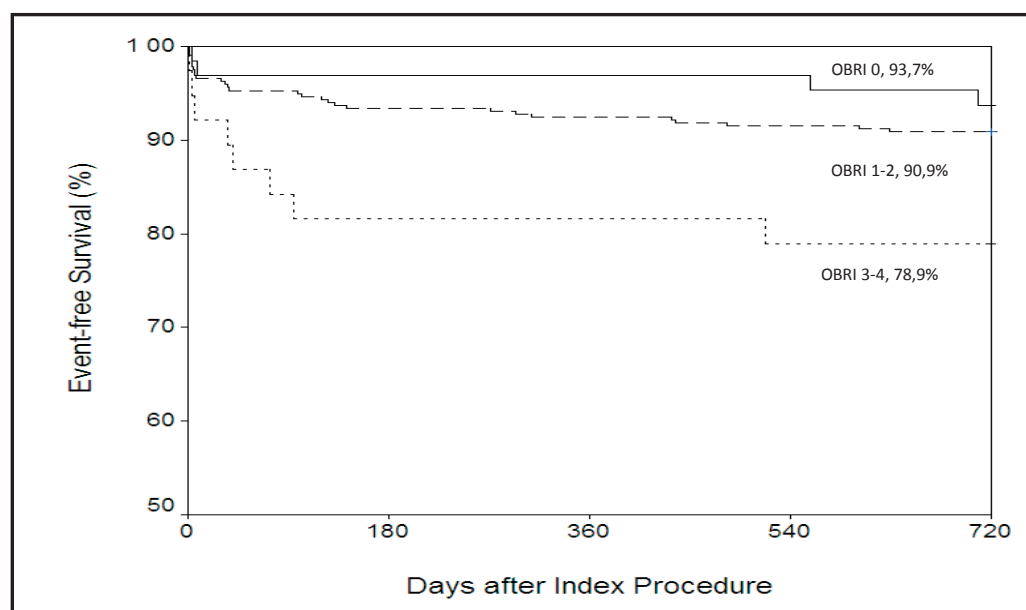


Figure 1. Kaplan-Meier time-to-events curve for major bleeding according to OBRI category. OBRI, outpatient bleeding risk index. Modified from original publication III.

5.4 The extent of neointimal coverage of stent struts by optical coherence tomography (OCT) at 30 days following the implantation of BASs in an unselected non-diabetic population (IV)

A total of 20 consecutive non-diabetic patients who underwent BAS (Titan-2[®]) implantation were studied. The mean age was 65 ± 13 years, and 85% were male. OCT images were obtained at 30-day follow-up. Binary stent strut coverage was defined as the number of covered struts as a percentage of all analysed struts. Patients underwent an OCT examination at an average of 30.5 ± 5.7 days following stent implantation. In these, 411 cross-sections were analysed, including 3780 struts. Binary stent strut coverage was 97.2%, and the prevalence of malapposed struts was 3.2%. OCT measurements are shown in **Table 5**. Pooled analyses showed that the mean NIH thickness was $103 \mu\text{m}$ (95% confidence interval [CI], 85–125). The inter-observer variability of the same cross-section measurements of NIH thickness was $6 \pm 9 \mu\text{m}$. Binary stent strut coverage was satisfactory and the prevalence of malapposed struts was low at 30-day follow-up after BAS implantation. No clinical events were observed during the period from stent implantation to the time of follow-up.

Table 5. Optical coherence tomography measurements.

Variable	Measurement
Struts per cross section (n)	9.2 ± 3.1
NIH thickness (qm)	109.7 ± 83.6
Stent cross-sectional area (mm ²)	7.15 ± 1.83
Lumen cross-sectional area (mm ²)	6.28 ± 1.99
NIH area (mm ²)	0.86 ± 0.46
Percent NIH area (%)	14.2 ± 8.2
Binary stent strut coverage	3674 (97.2%)
Malapposed stent struts	129 (3.2%)

Data given as n (percentage) or mean \pm standard deviation. NIH, neointimal hyperplasia. Modified from original publication IV.

5.5 Long-term clinical outcome in patients treated with titanium-nitride-oxide-coated stents and paclitaxel-eluting stents (V)

A total of 201 patients (218 lesions/221 stents) were treated with a BAS (Titan-2[®]), and 204 patients (244 lesions/247 stents) with a PES (Taxus[®]). The PES patients were younger, and they had less hypercholesterolemia and hypertension in their medical history. BAS patients more often had acute MI as their presenting symptom and more complex B- and C-type lesions treated. The total stent length was significantly shorter ($p < 0.001$) in the BAS group. After 3 years of follow-up, the rate of MACE was 13.9% for BAS and 23.5% for PES (adjusted HR 2.0, 95% CI 1.2–3.2, $p = 0.006$). This difference was mainly driven by a higher incidence of MI in the PES group (19.1%) in comparison to the BAS (7.5%) group (adjusted HR 3.2, 95% CI 1.7–5.8, $p < 0.001$). At 3 years, stent

thrombosis occurred in 15 patients in the PES (7.4%) group, as demonstrated in **Figure 2**. There was no stent thrombosis in the BAS group.

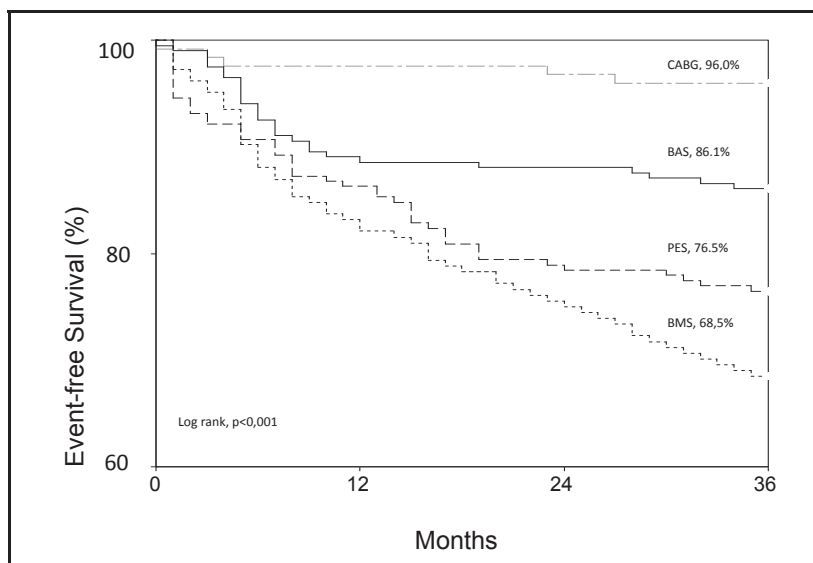


Figure 2. MACE-free survival during the 3-year follow-up period estimated with the Kaplan-Meier method. The significance of the differences between treatment groups was assessed by the log-rank test. CABG, coronary artery bypass grafting; BAS, bioactive stent; PES, paclitaxel eluting stent; BMS, bare metal stent. Modified from original publication V.

In multivariable analysis, MACE at 3 years was predicted by older age (HR 1.03, 95% CI 1.01–1.05, $p = 0.02$), previous MI (HR 1.7, 95% CI 1.0–2.8, $p = 0.03$), non-ST-elevation MI as the presenting symptom (HR 1.8, 95% CI 1.1–3.0, $p = 0.01$) and the use of a PES (HR 2.0, 95% CI 1.2–3.2, $p = 0.006$). MI or cardiac death was predicted by older age (HR 1.05, 95% CI 1.02–1.08, $p < 0.001$), previous PCI (HR 2.1, 95% CI 1.2–3.6, $p = 0.009$) and the use of a PES (HR 3.2, 95% CI 1.7–5.8, $p < 0.001$). After the multivariable models were adjusted for propensity score the differences in MACE (HR 2.2, 95% CI 1.2–3.8, $p = 0.007$) and MI or cardiac death (HR 4.1, 95% CI 2.1–8.1, $p < 0.001$) between the groups remained significant.

In addition, 184 patients treated with BMSs during the same study period were examined. Patients in the BMS group had less PCI's in their medical history than PES patients (7% vs. 24%, respectively), and BMS patients also received shorter stents than PES patients (16.4 mm vs. 21.2 mm, respectively). In the BMS group, patients more often had acute non-ST-elevation MI as their presenting symptom before the procedure than those in the PES group (39% in BMS group vs. 24% in PES group). When compared to the BAS group, BMS patients had more seldom had a previous MI in their medical history (44% in BAS group vs. 32% in BMS group) and also less complex C-type lesions treated (25% vs. 4%, respectively). During the 3-year follow-up, the MACE rate in the BMS group was higher

(31.5%) compared to other stent groups. This was mainly driven by a moderately high incidence of recurrent MI, TLR and cardiac death in the BMS group. ST occurred in 2.7 % of patients in BMS group ($p = 0.4$ vs. BAS group, $p = 0.03$ vs. PES group).

The clinical records of 124 patients who had undergone CABG during the same study period (mean age 64 years [range 38–85], 14% female) were studied. Diabetes was present in 26%, hypercholesterolemia in 92% and hypertension in 62% of the patients, and 18% of them were current smokers. A total of 14 patients (11%) had a revascularization procedure (11 patients PCI and 3 CABG) and 33 patients (27%) an MI in their medical history. Ten patients (8%) had single-vessel disease, and 41 patients (9 patients had ST-elevation MI, 28 non-ST-elevation MI and 4 unstable angina) presented with acute coronary syndrome before the index angiography and subsequent CABG. The overall rate of MACE in the CABG patients during 3 years of follow-up was 4% including 3 sudden cardiac deaths (2.4%), 3 acute MI (2.4%) and 1 TVR (0.8%). One patient died during the index hospitalisation, and this event occurred two days after the CABG. Two patients died of a non-cardiac cause during the follow-up.

Of the 589 study patients (88.1%) who underwent PCI, 519 remained MACE-free at the time of clopidogrel discontinuation (184 patients in BAS, 183 in PES and 152 in BMS groups). During the 12-month follow-up after the clopidogrel withdrawal, there was no difference in the incidence of MACE between the three groups, but the incidence of MI was higher in the PES group compared with the other two stent groups; **Figure 3**. After the clopidogrel discontinuation, ST occurred more frequently in the PES group than the BAS group (3.8% vs. 0%, $p = 0.009$).

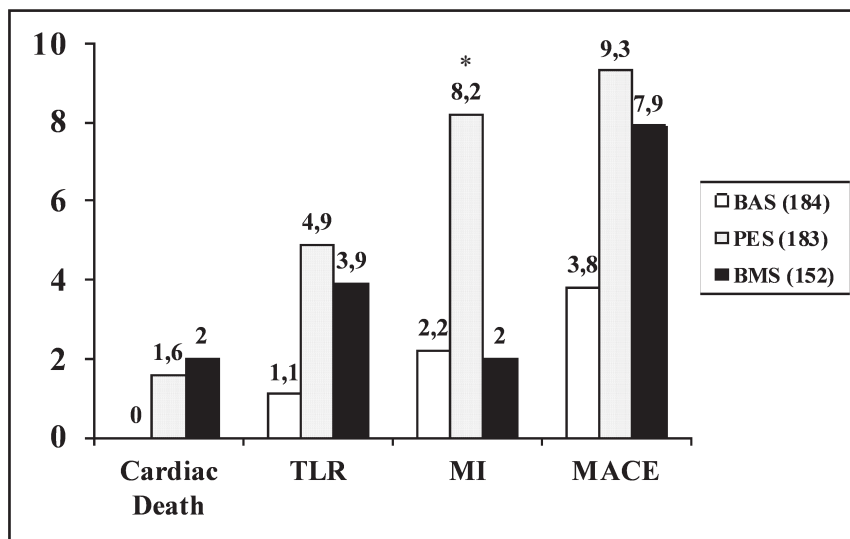


Figure 3. Outcome events during the 12-month follow-up after the discontinuation of clopidogrel. BAS, bioactive stent; PES, paclitaxel-eluting stent; BMS, bare metal stent; TLR, target lesion revascularization; MI, myocardial infarction; MACE, major adverse cardiac events. *BAS versus PES, $p = 0.01$ and BMS versus PES, $p = 0.01$. Modified from original publication V.

6. DISCUSSION

6.1 The safety and feasibility of diagnostic coronary angiography during uninterrupted warfarin therapy (I)

The major finding was that the simple strategy of performing coronary angiography during uninterrupted therapeutic warfarin anticoagulation does not predispose patients to excessive bleeding or access site complications during coronary angiography. However, access site complications seemed to associate with supratherapeutic INR levels.

It has been generally recommended to patients on long-term warfarin therapy to discontinue warfarin a few days prior to elective coronary angiography or intervention to reach INR levels of < 1.8 (Grossman 2000, Popma et al. 2001). The fear of unopposed fatal bleeding has been the main argument against an uninterrupted warfarin therapy policy during cardiac procedures. However, in the case of major bleeding, the anticoagulant effect of warfarin can be overcome by concentrates of blood clotting factors II, VII, IX and X. The anticoagulant effect can also be decreased by low doses of vitamin K₁, but the effect is slower and if large doses of vitamin K₁ are used, the patient may become resistant to warfarin for up to 1 week because of the accumulation of vitamin K₁ in the liver. BT with heparin is recommended for patients at an increased risk of thromboembolism who require an interruption of AC for elective surgery or an invasive procedure. However, guidelines have been based on circumstantial evidence rather than randomized large-scale trials (Karjalainen et al. 2008). Wide fluctuation in INR values are commonly and long-lastingly seen after the interruption of warfarin, often necessitating prolonged bridging therapy. The reinitiation of warfarin may cause a transient prothrombotic state due to protein C and S suppression (Hirsh et al. 2001).

The safety and efficacy of BT have been questioned in patients undergoing coronary angiography, pacemaker implantation or pulmonary vein ablation. In some studies, BT has shown no advantages and even increased bleeding events. Furthermore, prolonged hospitalization has been recorded in heparin-bridged patients, and patients with acute coronary syndromes on long-term OAC wait for coronary procedures longer and are less likely to undergo angiography and PCI than the patients without oral anticoagulation (Lahtela et al. 2012). Performing angiography or PCI without interrupting OAC avoids the increased thrombotic risk associated with a subtherapeutic anticoagulation level if the interruption is not fully covered by LMWH. For patients with a high bleeding risk, a strategy of a temporary adjustment of warfarin dosing to reach a periprocedural INR range of 1.5–2.0 may be a reasonable option for anticoagulation treatment during coronary angiography. This strategy has been shown to be safe and effective in the prevention of thromboembolism after noncardiac surgery (Larson et al. 2005).

Current guidelines provide limited guidance on long-term OAC during coronary angiography and the peri-PCI period. Most of the available data are still based on small, mainly single-centre and retrospective patient cohorts or derive from subgroup analyses of larger controlled trials of OAC patients. In the recent European consensus paper, the UAC strategy with no additional heparin boluses during PCI is preferred for AF patients at moderate to high risk of thromboembolism (Lip et al. 2014). In the same paper, the lowest possible median INR levels within the therapeutic range are recommended for patients with AF and a prosthetic mechanical heart valve undergoing percutaneous procedure. Patients with recent (3-6 months) or recurrent venous thromboembolism are also considered to be at risk of recurrent events if anticoagulation is interrupted. A radial access route is recommended to minimize access-related bleeding, especially during therapeutic anticoagulation. In the recent AHA/ACC/HRS atrial fibrillation guideline, the cessation of warfarin and allowing the INR to normalize before an interventional procedure is recommended for low-risk nonvalvular patients. For patients at a higher risk of thromboembolism, such as those with mechanical valves, a prior stroke or a CHA₂DS₂-VASc score of at least 2, bridging therapy with UFH or LMWH, or a UAC strategy could be chosen (January et al. 2014).

6.2 Comparison of the long-term safety of drug-eluting stents and bare metal stents in patients on warfarin treatment (II)

Study II was the largest and most comprehensive evaluation of the long-term outcome in OAC patients after coronary stenting published by that time. There were 16 earlier studies reporting the outcomes in patients on long-term warfarin undergoing coronary stenting, and most of these were small retrospective single-centre series (Airaksinen et al. 2010).

Bleeding complications are the most common non-ischaemic complications of PCI, especially in the treatment of acute coronary syndromes. Most of the bleeding events occur early during the hospital phase, and in the large CRUSADE Registry, for example, the incidence of in-hospital major bleeding events was as high as 9.4% (Subherwal et al. 2009). In the AFCAS study of 963 patients with AF undergoing coronary intervention with stent implantation, in-hospital bleeding complications occurred in 7.1% of patients, being severe in 2.5% (Schlitt et al. 2013). The incidence of bleeding events seems relatively high when patients on long-term OAC need concomitant potent antiplatelet agents due to a PCI (Rubboli et al. 2008). Triple therapy is the most frequently used drug regimen in this scenario. The downside of this potent antithrombotic combination is the high incidence of bleeding complications, since the incidence of major bleedings increases in the range of 3.2-6.6-fold compared with DAPT (Airaksinen et al. 2010). In comparison to post-MI patients on OAC alone, triple therapy patients have a 3-fold increased risk of hospital admission for bleeding complications (Sørensen et al. 2009). The duration of triple therapy seems to be critical, since in a pooled analysis the rate of

major bleeding increased from 4.6% to 10.3% when the treatment period increased from one month to 6-12 months or more (Rubboli et al. 2008).

Our results confirm those of earlier studies demonstrating a high rate of major bleeding complications after PCI in patients needing long-term OAC (Karjalainen et al. 2007 and 2008, Rossini et al. 2008, Ruiz-Nodar et al. 2009). The use of a DES was not associated with an increase in the rate of major bleeding episodes relative to BMS use. This was not unexpected, since only 62% of the patients in the DES group and 58% of those in the BMS group received triple therapy at discharge and the duration of triple therapy was shorter than recommended at the time the study was carried out in both stent groups, reflecting the contemporary treatment policies. Furthermore, the recently published results from the AFCAS study showed that DES use was associated with outcomes comparable to those of BMS use with no excess bleeding complications during one-year follow-up (Kiviniemi et al. 2014). In one study (Ruiz-Nodar et al. 2009), the use of a DES was associated with a higher rate of major bleedings, with no difference in thrombotic complications in patients with atrial fibrillation. The longer duration of triple therapy in the DES-treated patients may contribute to this difference, since also Sarafoff et al. reported that the use of a DES was feasible and safe in patients receiving either 12 weeks of triple therapy or dual antiplatelet therapy (Sarafoff et al. 2008).

DESs were developed to reduce the problem of restenosis inherent to BMSs. In study II, DES patients received significantly longer and smaller stents than BMS patients, apparently reflecting the higher risk of restenosis in the DES-treated lesions. The actual rate of clinical restenosis was comparable in both groups, suggesting that the stenting policy was effective in the prevention of restenosis.

A longer delay in arterial healing may extend the risk of ST far beyond 30 days after the DES implantation. This problem has been shown in many first-generation DES studies (MCFadden et al. 2004, Joner et al. 2006, Lee et al. 2006, Pfistered et al. 2006). Consequently, there has been concern of regarding late stent thrombosis after DES implantation, and early discontinuation of antiplatelet therapy has been the most important predisposing factor for stent thrombosis. However, recent reports have suggested lower ST rates in patients with newer-generation DESs as compared to those with BMSs (Kiviniemi et al. 2014a). Recent recommendations suggest as short triple therapy as possible for patients with an indication for concomitant OAC depending on the clinical setting, acute vs. elective procedure, bleeding risk and type of stent used. Triple therapy is recommended for four weeks to six months after PCI, with a careful estimation of the patient's risk profile. Currently available data do not support prolonging thienopyridine beyond one year. It may be considered in very selected cases, such as stenting of the left main, proximal left anterior descending, proximal bifurcation or recurrent MI. (Amsterdam et al. 2014, Lip et al. 2014). The risk of stent thrombosis after the cessation of short triple therapy was low in study II, and the two cases of stent thrombosis occurred so late that the recommended 12 months' treatment would not have prevented these very late events. Findings in study II suggest that a shorter-lasting triple

therapy may also be considered after DES implantation, especially when the clinical risks and consequences of stent thrombosis are considered reasonable or the individual bleeding risk is high.

6.3 The value of an outpatient bleeding risk index (OBRI) in predicting bleeding events and prognosis during long-term follow-up after PCI and its influence on contemporary treatment choices (III)

The annual risk of major bleedings in patients on long-term OAC undergoing coronary angiography or PCI is estimated to be approximately 3%. The bleeding risk varies to a great extent between the patients, and seems to be higher in the first year after treatment and in old patients (Hylek et al. 2007). In study III, in addition to old age, the absence of hypercholesterolemia, non-ST-elevation MI and baseline creatinine level were independent predictors of major bleeding. Previous data do not support the association between the absence of hypercholesterolemia and risk of major bleeding. Furthermore, statins may decrease the incidence of gastrointestinal bleeding (Enajat et al. 2009, Gulmez et al. 2009).

A variety of bleeding risk scores have been developed to predict the risk of major bleeding in patients with AF; **Table 6**.

Table 6. The risk factors of different scoring systems for estimating the risk of major bleeding in patients with atrial fibrillation.

Risk score system	Risk factors
ATRIA	anaemia, renal impairment, age ≥ 75 years, hypertension, previous bleeding episode
HAS-BLED	hypertension, abnormal renal/liver function, stroke, bleeding history or predisposition, labile INR, elderly, drugs/alcohol
OBRI	history of stroke, age ≥ 65 years, history of gastrointestinal bleeding, presence of ≥ 1 comorbid condition: recent MI, renal insufficiency, severe anemia or diabetes
REACH	age, peripheral arterial disease, hypercholesterolemia, congestive heart failure, hypertension, antithrombotic therapy, former/current smoker
HEMORR(2)HAGES	hepatic or renal disease, ethanol abuse, malignancy, older age, reduced platelet count or function, re-bleeding, hypertension, anemia, genetic factors, excessive fall risk, stroke

INR, international normalized ratio; MI, myocardial infarction

In study III, less than 10% of patients were in the high bleeding risk group, and over 25% of them suffered major bleeding during the period of triple therapy. The overall prognosis of this patient group seemed to be poor. The OBRI scoring appeared to be suitable for risk evaluation in patients on long-term OAC after PCI. The bleeding risk seemed not to modify periprocedural or long-term treatment choices in this patient group.

Although the bleeding risk scorings, especially the HAS-BLED score, are widely used for bleeding risk evaluation in AF patients, data from recent studies have not been convincing on the predictive performance of these risk-estimation tools in AF patients (Burgess et al. 2013, Kiviniemi et al. 2014b). The accurate prediction of bleeding seems highly challenging when multiple antithrombotic medication are used due to AF and PCI.

6.4 The neointimal coverage of stent struts following the implantation of BASs (IV)

The major finding was that upon evaluation by means of OCT at 30-day follow-up after BAS (Titan-2[®]) implantation, in an unselected non-diabetic cohort, binary stent strut coverage was satisfactory and the prevalence of malapposed struts was low.

After PCI, uncovered stent struts directly exposed to the blood stream provide a substrate for the occurrence of ST. This fact is supported by pathological studies that have unveiled deficient tissue healing in cases of late ST associated with DESs (Finn et al. 2007, Murata et al. 2010). Malapposed struts may result in flow disturbance that would create a prothrombotic milieu (Davies et al. 2005). Earlier studies have showed a binary stent strut coverage range of 84%–99% for DESs at 3–13 months of follow-up (Karjalainen et al. 2012) and 98%–99% for BMSs at 6–13 months of follow-up (Guagliumi et al. 2010 and 2011). Long-term OCT follow-up showed excellent binary stent strut coverage for BASs when compared to paclitaxel-eluting stents (99.6 vs 89.2%; $p < 0.001$) in patients treated for acute myocardial infarction (Lehtinen et al. 2012a). However, the data on very early stent healing is scarce. In one study, 30 days after implantation of an endothelial progenitor cell capturing stent, which is designed to promote endothelialisation with an antibody coating, binary stent strut coverage of 95% was seen in OCT (Lehtinen et al. 2012b). The endothelial coverage of the BAS appears to be more complete when compared to an endothelial progenitor cell capturing stent at this stage. Based on the limited data available, the binary stent strut coverage of BASs as early as 30 days following the implantation would seem better than that demonstrated with DESs, and quite comparable with that of BMSs. These findings might encourage the shortening of dual-antithrombotic therapy after PCI with BAS, thus reducing the risk of major bleeding in patients with several bleeding risk factors.

The frequency of malapposed struts (3.2%) was somewhat higher than that reported for various DESs (0.2%–1.8%) at 9–13 months of follow-up in two large randomized controlled trials (Barlis et al. 2010, Gutiérrez-Chico et al. 2011) or when compared to an endothelial progenitor cell capturing stent at 30 days (2.4%) (Lehtinen et al. 2012). This apparent divergence of findings might be viewed better in light of the exceptionally high frequency of patients presenting with acute coronary syndrome (80%) in this study. In another OCT study, significantly better stent strut coverage and apposition was seen nine months after a PCI with a DES in patients with stable coronary artery disease compared to ACS patients (Kim et al. 2011).

6.5 Long-term clinical outcome in patients treated with titanium-nitride-oxide-coated stents and paclitaxel-eluting stents (V)

Study V was first long-term comparison of BASs (Titan-2[®]) with first-generation PES (Taxus[®]) in routine clinical practice. The major finding was that the unrestricted use of a BAS in de novo lesions led to a superior long-term outcome in comparison to a PES even in high risk patients with complex coronary lesions. The risk of ST was fairly low, but it was concentrated on the use of a PES in the setting of acute MI. During the follow-up period of 1–3 years, the incidence of recurrent MI, ST and subsequent MACE was significantly lower in BAS patients. There was no ST in the BAS group. A TITANOX-coating may contribute to these findings, since an in vitro study has suggested that TITANOX reduces platelet adhesion and fibrinogen binding in comparison to stainless steel (Steinemann 1996). Compared to other study groups, patients undergoing CABG had lower rates of MACE and needed repeated revascularization less frequently. Despite the different incidence of ISR and ST, long-term death and MI rates have been comparable in previous DES trials in patients receiving either a BMS or a DES.

In the TITAX-AMI trial, patients presenting with acute MI who underwent early PCI, those with a BAS achieved a better clinical outcome as compared to patients with a PES at the 5-year follow-up. Lower cumulative rates of overall MACE, cardiac death, recurrent MI and definite ST occurred in the BAS group; yet, with statistically similar rates of ischaemia-driven TLR and all-cause death (Tuomainen et al. 2013). The 5-year follow-up in the PORI Registry showed a significantly lower incidence of MI, MACE and ST after BAS implantation as compared to DES. No statistical differences could be found in TLR, cardiac death or all-cause death between the stent groups (Karjalainen et al. 2011). Furthermore, the results in study V demonstrate a similar incidence of all cause death in all stent groups, as well as in the CABG group.

The MACE rate was higher in the BMS group when compared to the other stent groups and the CABG group at 3 years follow-up. This was mainly driven by a moderately high incidence of recurrent MI, TLR and cardiac death in the BMS group. This trend has seen in studies comparing BMS to DES (Mauri et al. 2007, Stone et al. 2007) and BAS (Giraud-Sauveur 2007, Moschovitis et al. 2010). The rate of recurrent MI appeared to be higher in the PES group when compared to the BMS group.

As to the comparison of the TITANOX stent to newer-generation DESs, one study found a zotarolimus-eluting stent (Endeavor[®]) to be superior to the TITANOX stent with regard to late loss and binary restenosis (Pilgrim et al. 2011). In the BASE-ACS trial, ACS patients received either a Titan2[®] BAS or a Xience V EES. After 24 months of follow-up, the rates of outcomes were similar in both groups (Romppanen et al. 2013). In the ongoing TIDES-ACS trial, a novel BAS (Optimax[™]) is compared to a biodegradable polymer EES (Synergy[™]). This multicentre trial explores hard endpoints (cardiac death, MI and major bleeding) in patients presenting with ACS, and compares modern BASs and EESs (Colkesen et al. 2015).

6.6 Possible limitations of the study

Studies I-III were limited by a typical retrospective study design including individual risk-based decision-making in the treatment choices. The outcome assessments were not blinded, and the small sample sizes possibly caused some bias in records and limited subgroup analyses. In study I, differences in the perioperative use of antithrombotic medication as well as other differences in management strategies and patient selection may have modified the results. In studies II and III, data on medication in clinical databases were not complete for all patients during the follow-up, especially when a patient underwent repetitive medication changes. Information on minor bleeding complications was incomplete, and the threshold for an access site bleeding that caused prolonged hospitalization may have varied among institutions, which might have under-estimated the bleeding complications observed in clinical practice.

In study IV, findings were based on a single-centre register with a relatively small sample size of the cohort. Despite the fact that the resolution of the OCT technique is high and allows adequate visualization of the tissue surrounding the stent struts, the composition of such tissue is not clearly discernible, particularly around malapposed struts. Thus, the presence of fibrin and/or thrombotic tissue overlying the struts might be mistaken for neointimal coverage reducing the specificity of OCT. A thin rim of neointima covering the struts may fall beyond the resolution of the OCT imaging catheter commercially available currently, compromising the sensitivity of the technique.

The evaluation of stent struts at 1 mm longitudinal intervals is an experimentally validated method for the assessment of neointimal strut coverage and has shown excellent reproducibility. However, it might have a lower sensitivity to detect uncovered struts than shorter-interval protocols.

Study V carried the general problem of registry-based observational studies with nonblinded outcome assessment. The single-centre, low-patient-number registry possibly gave rise to unrecognized selection and performance bias, and the size of patient groups for subgroup analyses were limited. Angiographic control was performed in a minority of patients, and the incidence of angiographic ISR and silent ST might have been underestimated.

The strength of the single-centre registry in study V was that Satakunta Central Hospital is the only centre with coronary angiography capacity in the referral area. The population in this area is stationary, enabling complete and long enough follow-up of an all-inclusive unrestricted patient population undergoing coronary revascularization in daily practice. Furthermore, all patients during the study period undergoing PCI or CABG were included in these analyses, reflecting the actual outcome of patients with coronary heart disease needing invasive therapy.

7. CONCLUSION

1. The strategy of performing coronary angiography during uninterrupted therapeutic warfarin anticoagulation is a relatively safe alternative to bridging therapy, if the international normalized ratio level is not on a supratherapeutic level (I).
2. Selective use of drug-eluting stents with a short triple therapy seems to be safe in patients with warfarin therapy (II).
3. Patients on home warfarin with a high outpatient bleeding risk index often have major bleeding episodes after PCI, and OBRI may be used for risk evaluation in this patient group (III).
4. After titanium nitride oxide-coated stent implantation, the binary stent strut coverage was satisfactory and the prevalence of malapposed struts was low as evaluated by optical coherence tomography at 30-day follow-up (IV).
5. The titanium-nitride-oxide-coated stent resulted in a better clinical outcome during three years of follow-up, with a reduced incidence of recurrent myocardial infarction, major cardiac adverse events and stent thrombosis when compared to a paclitaxel-eluted stent (V).

8. ACKNOWLEDGEMENTS

This study was carried out at the Department of Internal Medicine at Seinäjoki Central Hospital and at the Heart Center at Satakunta Central Hospital in collaboration with the Department of Medicine at the University of Turku during 2003–2015.

I would like to express my warmest and most sincere gratitude to my supervisors, Docent Pasi Karjalainen, M.D., Ph.D., and Professor Juhani Airaksinen, M.D., Ph.D., who introduced me to this subject. Their enthusiasm for science and their great experience supported me through this long project. Their superior encouragement enabled me to process and complete this thesis.

I wish to express my sincere gratitude to Professor Antti Ylitalo, M.D., Ph.D., for his support in research and for sharing his knowledge and experience in interventional cardiology.

I also express my warmest thanks to the Head of Department Matti Kotila, M.D., for his understanding and support, and his efforts enabling me to write this thesis.

I am sincerely grateful to Docent Olli Anttonen, M.D., Ph.D., and Docent Kari Ylitalo, M.D., Ph.D., for their valuable and constructive comments on this thesis. Their excellent and thorough review helped me to improve the quality of my thesis.

I express my gratitude and thanks to Pekka Porela, M.D., Ph.D., Kai Nyman, M.D., Fausto Biancari, M.D., Ph.D., Matti Niemelä, M.D., Ph.D., Saira Vikman, M.D., Ph.D., Hanna Suurmunne, M.D., Ph.D., Marja Puurunen, M.D., Ph.D., Tuomas Lehtinen, M.D., Tuomas Kiviniemi, M.D., Ph.D. and Wail Nammas, M.D. for their important contribution to the completion of this study.

I thank Tero Vahlberg, M.Sc., for his skilled and helpful statistical advice and guidance and Eeva Parviainen, M.A., for her careful revision of the language in this thesis.

Finally, my deepest thanks to my loving wife, Kaija, and my great children Karoliina, Jaakko and Johannes, for your patience and support over the years.

This study has been financially supported by the EVO grant of Satakunta Central Hospital, the Signe Niemistö Legacy Fund and a grant from the Finnish Foundation for Cardiovascular Research. This support is gratefully acknowledged.

Seinäjoki, September 2015

Antti-Pekka Annala

9. REFERENCES

- Abtahian F, Jang IK (2012). Optical coherence tomography. basics, current application and future potential. *Curr Opin Pharmacol* 12:583-591.
- Airaksinen K, Sclitt A, Rubboli A, et al (2010a). How to manage antithrombotic treatment during percutaneous coronary interventions in patients receiving long-term oral anticoagulation: To “bridge” or not to “bridge”? *Eurointervention* 6:520-526.
- Airaksinen KEJ, Ylitalo A, Karjalainen PP (2010b). Drug-eluting stents in patients on long-term oral anticoagulation therapy: a mission impossible? *Interv Cardiol* 2:127-135.
- Airoldi F, Colombo A, Morici N, et al (2007). Incidence and predictors of drug-eluting stent thrombosis during and after discontinuation of thienopyridine treatment. *Circulation* 116:2501-2555.
- Alexander JH, Becker RC, Bhatt DL, et al (2009). Apixaban, an oral, direct selective factor Xa inhibitor, in combination with antiplatelet therapy after acute coronary syndrome: results of the Apixaban for Prevention of Acute Ischemic and Safety Events (APPRAISE) trial. *Circulation* 119:2877-2885.
- Alexander JH, Lopes RD, James S, et al (2011). APPRAISE-2 investigators. Apixaban with antiplatelet therapy after acute coronary syndrome. *N Eng J Med* 365:699-708.
- Alexander KP, Chen AY, Roe MT, et al (2005). Excess dosing of antiplatelet and antithrombin agents in the treatment of non-ST-segment elevation acute coronary syndromes. *JAMA* 294:3108-3116.
- Alexopoulos D (2012). Prasugrel resistance: fact or fiction. *Platelets* 23:83-90.
- Alfonso F, Byrne RA, Rivero F, et al (2014a). Current treatment of in-stent restenosis. *J Am Coll Cardiol* 63:2659-2673.
- Alfonso F, Pérez-Vizcayno MJ, Cárdenas A, et al (2014b). A randomized comparison of drug-eluting balloon versus everolimus-eluting stent in patients with bare-metal stent-in-stent restenosis: the RIBS V Clinical Trial (Restenosis Intra-stent of Bare Metal Stents: paclitaxel-eluting balloon vs. everolimus-eluting stent). *J Am Coll Cardiol* 63:1378-1386.
- Alfonso F, Pérez-Vizcayno MJ, Hernandez R, et al (2006). A randomized comparison of sirolimus-eluting stent with balloon angioplasty in patients with in-stent restenosis: results of the Restenosis Intra-stent: Balloon Angioplasty Versus Elective Sirolimus-Eluting Stenting (RIBS-II) trial. *J Am Coll Cardiol* 47:2152-2160.
- Alfonso F, Zueco J, Cequier A, et al (2003). A randomized comparison of repeat stenting with balloon angioplasty in patients with in-stent restenosis. *J Am Coll Cardiol* 42:796-805.
- Al Suwaidi J, Holmes DR jr, Salam AM, et al (2004). Impact of coronary artery stents on mortality and nonfatal myocardial infarction: meta-analyses of randomized trials comparing a strategy of routine stenting with that of balloon angioplasty. *Am Heart J* 147:815-822.
- Amsterdam EA, Wenger NK, Brindis RG, et al. (2014). 2014 AHA/ACC Guideline for the Management of Patients With Non-ST-elevation Acute Coronary Syndromes: A Report of the American College of Cardiology/American Heart Association Task Force of Practical Guidelines. *Circulation* 130:2354-2394.
- Angiolillo DJ, Badimon JJ, Saucedo JF, et al (2011). A pharmacodynamic comparison of prasugrel versus high-dose clopidogrel in patients with type 2 diabetes mellitus and coronary artery disease: results of the Optimizing anti-Platelet Therapy in diabetes Mellitus (OPTIMUS)-3 Trial. *Eur Heart J* 32:838-846.
- Aoki J, Serruys PW, van Beusekom H, et al (2005). Endothelial progenitor cell capture by stents coated with antibody against CD 34. The HEALING-FIM (Healthy Endothelial Accelerated Lining Inhibits Neointimal Growth-First in Man) Registry. *J Am Coll Cardiol* 45:1574-1579.
- Apostolakis S, Lane DA, Buller H, et al (2013). Comparison of the CHADS2, CHA2DS2-VASc and HAS-BLED scores for the prediction of clinically relevant bleeding in anticoagulated patients with atrial fibrillation: the AMADEUS trial. *Thromb Haemost* 110:1074-1079.
- Apostolakis S, Lane DA, Guo Y, et al (2012). Performance of the HEMORR(2)HAGES, ATRIA, and HAS-BLED bleeding risk-prediction scores in patients with atrial fibrillation undergoing anticoagulation: the AMADEUS (evaluating the use of SR34006 compared to warfarin or acenocoumarol in patients with atrial fibrillation) study. *J Am Coll Cardiol* 60:861-867.
- Ardissino D, Cavallini C, Bramucci E, et al (2004). Sirolimus-eluting vs uncoated stents for prevention of restenosis in small coronary arteries; a randomized trial. *JAMA* 292:2727-2734.
- Ari H, Ari S, Erdoğan E, et al (2010). A novel predictor of restenosis and adverse cardiac events: asymmetric dimethylarginine. *Heart Vessels* 25:19-26.
- Auer J, Maurer E, Berent R, et al (2003). Clinical and angiographic outcome after cutting balloon angioplasty. *J Interv Cardiol* 16:15-21.

- Babapulle MN, Eisenberg MJ (2002). Coated stents for the prevention of restenosis. *Circulation* 106:2859-2866.
- Badr S, Ben-Dor I, Dvir D, et al (2013). The state of the excimer laser for coronary intervention in the drug-eluting stent era. *Cardiovasc Revasc Med* 14:93-98.
- Baigent C, Blackwell L, Collins R, et al (2009). Aspirin in the primary and secondary prevention of vascular disease: collaborative meta-analyses of individual participant data from randomized trials. *Lancet* 373:1849-1860.
- Baim DS, Wahr D, George B, et al (2002). Randomized trial of a distal embolic protection device during percutaneous intervention of saphenous vein aorto-coronary bypass grafts. *Circulation* 105:1285-1290.
- Barlis P, Regar E, Serruys PW, et al (2010). An optical coherence tomography study of a biodegradable vs. durable polymer-coated limus-eluting stent: a LEADERS trial sub-study. *Eur Heart J* 31:165-176.
- Barnathan ES, Schwartz JS, Taylor L, et al (1987). Aspirin and dipyridamole in the prevention of acute coronary thrombosis complicating coronary angioplasty. *Circulation* 76:125-134.
- Belkacemi A, Agostoni P, Nathoe HM, et al (2012). First results of the DEB-AMI (drug eluting balloon in acute ST-segment elevation myocardial infarction) trial: a multicenter randomized comparison of drug-eluting balloon plus bare-metal stent versus drug-eluting stent in primary percutaneous coronary intervention with 6-month angiographic, intravascular, functional, and clinical outcomes. *J Am Coll Cardiol* 59:2327-2337.
- Bech GJ, Buysse B, Pijls NH, et al (2001). Fractional flow reserve to determine the appropriateness of angioplasty in moderate coronary stenosis: a randomized trial. *Circulation* 103:2928-2934.
- Belotti D, Vergani V, Drudis T, et al (1996). The microtubule-affecting drug paclitaxel has antiangiogenic activity. *Clin Cancer Res* 2: 1843-1849.
- Bezerra HG, Costa MA, Guagliumi G, et al (2009). Intracoronary Optical Coherence Tomography: A Comprehensive Review. *J Am Cardiol Interv* 2:1035-1046.
- Beyth RJ, Quinn LM, Landefeld CS, et al (1998). Prospective evaluation of an index for predicting the risk of major bleeding in outpatients treated with warfarin. *Am J Med* 105:91-99.
- Bhatt DL (2009). Prasugrel in clinical practice. *N Eng J Med* 361:940-942.
- Bhatt DL, Stone GW, Mahaffey KW, et al (2013). Effect of platelet inhibition with cangrelor during PCI on ischemic events. *N Engl J Med* 368:1303-1313.
- Bittl JA, Strony J, Brinkel JA, et al (1995). Treatment with bivalirudin (Hirulog) as compared with heparin during coronary angioplasty for unstable or postinfarction angina. Hirulog Angioplasty Study Investigators. *N Eng J Med* 333:764-769.
- Boccaro A, Benamer H, Juliard J, et al (1997). A randomized trial of a fixed high dose vs a weight-adjusted low dose of intravenous heparin during coronary angioplasty. *Eur Heart J* 18:631-635.
- Bonello L, Tantry US, Marcucci R, et al (2010). Consensus and future directions on the definition of high on-treatment platelet reactivity to adenosine diphosphate. *J Am Coll Cardiol* 56:919-933.
- Bosch X, Marrugat J, Sanchis J, et al (2013). Platelet glycoprotein IIb/IIIa blockers during percutaneous coronary intervention and as the initial medical treatment of non-ST segment elevation acute coronary syndromes. *Cochrane Database Syst Rev* 11:CD002130.
- Brophy JM, Belishe P, Joseph L (2003). Evidence for use of coronary stents: a hierarchical Bayesian meta-analysis. *Ann Intern Med* 138:777-786.
- Buchanan GL, Basavarajaiah S, Chieffo A (2013). Stent thrombosis: incidence, predictors and new technologies. *Thrombosis* 2012:956962.
- Buchbinder M, Fortuna R, Sharma S, et al (2000). Debulking prior to stenting improves acute outcomes: early results from the SPORT trial. *J Am Coll Cardiol* 35(Suppl A):8A.
- Budaj A, Eikelboom JW, Mehta SR, et al (2009). OASIS 5 Investigators. Improving clinical outcomes by reducing bleeding in patients with non-ST-elevation acute coronary syndromes. *Eur Heart J* 30:655-61.
- Burgess S, Crown N, Louzada ML, et al (2013). Clinical performance of bleeding risk scores for preventing major and clinically relevant non-major bleeding events in patients receiving warfarin. *J Thromb Haemost* 11:1647-1654.
- Burke AP, Farb A, Malcom AT, et al (1997). Coronary risk factors and plaque morphology in men with coronary disease who died suddenly. *N Eng J Med* 336:1276-1282.
- Byrne RA, Iijima R, Mehil J, et al (2009). Durability of antirestenotic efficacy in drug-eluting stents with and without permanent polymer. *JACC Cardiovasc Interv* 2:291-299.
- Byrne RA, Kastrati A, Massberg S, et al (2011). Biodegradable polymer versus permanent polymer drug-eluting stents and everolimus- versus sirolimus-eluting stents in patients with coronary artery disease. 3-year outcomes from a randomized clinical trial. *J Am Coll Cardiol* 58:1325-1331.
- Camenzind E, Wijns W, Mauri L, et al (2012). Stent thrombosis and major clinical events at 3 years after

- zotarolimus-eluting or sirolimus-eluting coronary stents implantation: a randomized, multicentre, open-label, controlled trial. *Lancet* 380:1396-1405.
- Camm AJ, Lip GY, De Caterina R, et al (2012). 2012 focused update of the ESC Guidelines for the management of atrial fibrillation: an update of the 2010 ESC Guidelines for the management of atrial fibrillation. *Eur Heart J* 33:2719-2747.
- Cassese S, Byrne RA, Schulz S, et al (2014a). Prognostic role of restenosis in 10 004 patients undergoing routine control angiography after coronary stenting. *Eur Heart J* 36:94-99.
- Cassese S, Byrne RA, Tada T, et al (2014b). Incidence and predictors of restenosis after coronary stenting in 10 004 patients with surveillance angiography. *BMJ* 100:153-159.
- Cavusoglu E, Kini A, Marmur J, et al (2004). Current status of rotational atherectomy. *Catheter Cardiovasc Interv* 62:485-498.
- Chen BX, Ma FY, Luo W, et al (2008). Neointimal coverage of baremetal and sirolimus-eluting stents evaluated with optical coherence tomography. *Heart* 94:566-570.
- Cheng JW (2013). Updates in antiplatelet agents used in cardiovascular diseases. *J Cardiovasc Pharmacol Ther* 18:514-524.
- Chevalier B, Serruys PW, Silber S, et al (2007). Randomised comparison of Nobori, biolimus A9-eluting coronary stent with a Taxus(R), a paclitaxel-eluting coronary stent in patients with stenosis in native coronary arteries: The Nobori 1 trial. *Eurointerv* 2:426-434.
- Chevalier B, Silber S, Park SJ, et al (2009). Randomized comparison of the Nobori Biolimus A9-eluting coronary stent with the Taxus Liberté paclitaxel – eluting coronary stent in patients with stenosis in native coronary arteries. *Cardiovas Interv* 2:188-195.
- Chiang MH, Lee WL, Tsao CR, et al (2013). The use and clinical outcomes of rotablation in challenging cases in the drug-eluting stent era. *J Chin Med Assoc* 76:71-77.
- Choi HH, Kim JS, Yoon DH, et al (2013). Favorable neointimal coverage in everolimus-eluting stent at 9 months after stent implantation: comparison with sirolimus-eluting stent using optical coherence tomography. *Int J Cardiovasc Imaging* 28:491-497.
- Colombo A, Goldberg SL, Almagor Y, et al (1995). Intracoronary stenting without anticoagulation accomplished with intravascular ultrasound guidance. *Circulation* 91:1676-1688.
- Colombo A, Drzewiecki J, Banning A et al (2003). Randomized study to assess the effectiveness of slow- and moderate-release polymer-based paclitaxel-eluting stents for coronary artery lesions. *Circulation* 108: 788-794.
- Colombo A, Moses JW, Morice MC, et al (2004). Randomized study to evaluate sirolimus-eluting stents implanted at coronary bifurcation lesions. *Circulation* 108:1244-1249.
- Cook S, Wenaweser P, Togni M, et al (2007). Incomplete stent apposition and very late stent thrombosis after drug-eluting stent implantation. *Circulation* 115:2426-2434.
- Cook S, Meier B (2008). Have we been misled by the ESC DES firestorm? *Eurointervention* 3:535-537.
- Costa JR Jr, Abizaid A, Feres F, et al (2011). One-year results of the INSPIRE trial with the novel MGuard stent: serial analyses with QCA and IVUS. *Catheter Cardiovasc Interv* 78:1095-100.
- Colkesen EB, eefting FD, Rensing BJ, et al (2015). TIDES-ACS Trial: comparison of titanium-nitride-oxide coated bio-active-stent to the drug (everolimus)-eluting stent in acute coronary syndrome. study design and objectives. *Minerva Cardioangiol* 63:21-29.
- Cowley MJ, Dorros G, Kelsey SF, et al (1984). Acute coronary events associated with percutaneous transluminal coronary angioplasty. *Am J Cardiol* 53:12C-16C.
- Cuisset T, Morange PE, Alessi MC (2012). Recent advances in the pharmacogenetics of clopidogrel. *Human genetics* 131:653-664.
- Cutlip DE, Baim DS, Ho KK, et al (2001). Stent thrombosis in the modern era: a pooled analysis of multicenter coronary stent clinical trials. *Circulation* 103:1967-1971.
- Cutlip DE, Windecker S, Mehran R, et al (2007). Clinical end points in coronary stent trials: a case for standardized definitions. *Circulation* 115:2344-2351.
- Daemen J, Wenaweser P, Tsuchida K, et al (2007). Early and late coronary stent thrombosis of sirolimus-eluting and paclitaxel-eluting stents on routine clinical practice: data from a large two-institutional cohort study. *Lancet* 369:667-678.
- Danzi GB, Chevalier B, Urban P, et al (2012). Clinical performance of a drug-eluting stent with a biodegradable polymer in a unselected patient population: the NOBORI 2 study. *Eurointerv* 8:109-116.
- Davies PF, Spaan JA, Krams R (2005). Shear stress biology of the endothelium. *Ann Biomed Eng* 33:1714-1718.
- Dawkins K, Grube E, Guagliumi G, et al (2005). Clinical efficacy of polymer-based paclitaxel-eluting stents in the treatment of complex, long coronary artery lesions from a multi-center, randomized

- trial: support for the use of drug-eluting stents in contemporary clinical practice. *Circulation* 112: 3306-3313.
- Dauterman KW (2004). Percutaneous coronary intervention: In: Griffin Bp, Topoj EJ eds: Manual of cardiovascular medicine, 2nd Ed. Philadelphia : Lippincott Williams & Wilkins, 763-779.
- De Feyter PJ, Vos J, Rensing BJ (2000). Antirestenosis trials. *Curr Interv Cardiol Rev* 2:326-331.
- Delewi R, Hoebers LP, RÅmunddal T, et al (2013). Clinical and Procedural Characteristics Associated With Higher Radiation Exposure During Percutaneous Coronary Interventions and Coronary Angiography. *Circ Cardiovasc Interv* 6:501-506.
- Demyanets S, Tentzeris I, Jarai R, et al (2014). An increase of interleukin-33 serum levels after coronary stent implantation is associated with coronary in-stent restenosis. *Cytokine* 67:65-70.
- Dewilde WJ, Oirbans T, Vergheught FW, et al (2013). Use of clopidogrel with or without aspirin in patients taking oral anticoagulant therapy and undergoing percutaneous coronary intervention: an open-label, randomised, controlled trial. *Lancet* 381:1107-1115.
- Diletti R, Farooq V, Girasis C, et al (2013). Clinical and intravascular imaging outcomes at 1 and 2 years after implantation of absorb everolimus eluting bioresorbable vascular scaffolds in small vessels. Late lumen enlargement: does bioresorption matter with small vessel size? Insight from the ABSORB cohort B trial. *Heart* 99:98-105.
- Dill T, Dietz U, Hamm CW, et al (2000). A randomized comparison of balloon angioplasty versus rotational atherectomy in complex coronary lesions. (COBRA study). *Eur Heart J* 21:1759-1766.
- Dotter CT, Judkins MP (1964). Transluminal treatment of atherosclerotic obstruction: description of a new technique and a preliminary report of its application. *Circulation* 30:654-670.
- Doyle B, Rihal CS, O'Sullivan CJ, et al (2007). Outcomes of stent thrombosis and restenosis during extended follow-up of patients treated with bare-metal coronary stents. *Circulation* 116:2391-2398.
- Douketis JD, Johnson JA, Turpie AG, et al. (2004). Low-molecular-weight-heparin as bridging anticoagulation during interruption of warfarin: assessment of a standardized periprocedural anticoagulation regimen. *Arc Intern Med* 164:1319-1326.
- Du L, Zhang Y, Wang W, et al (2014). Perioperative anticoagulation management in patients on chronic oral anticoagulant therapy undergoing cardiac devices implantation: a meta-analysis. *Pacing Clin Electrophysiol* 37:1573-1586.
- Duckers HJ, Soullie T, den Heijer P, et al (2007). Accelerated vascular repair following percutaneous coronary intervention by capture of endothelial progenitor cells promotes regression of neointimal growth at long term follow-up: final results of the Healing II trial using an endothelial progenitor cell capturing stent (Genous R stent. *Eurointerv* 3:350-358.
- Ducrocq G, Wallace JS, Baron G, et al (2010). Risk score to predict serious bleeding in stable outpatients with or at risk of atherothrombosis. *Eur Heart J* 31:1257-1265.
- Dudek D, Onuma Y, Ormiston JA, et al (2012). Four-year clinical follow-up of the ABSORB everolimus-eluting bioresorbable vascular scaffold in patients with de novo coronary artery disease: The ABSORB trial. *Eurointerv* 7:1060-1061.
- El-Hayek G, Messerli F, Bangalore S, et al (2014). Meta-analyses of randomized clinical trials comparing short-term versus long-term dual antiplatelet therapy following drug-eluting stents. *Am J Cardiol* 114:236-242.
- Enajat M, Teerenstra S, van Kuilenburg J, et al (2009). Safety of the combination of intensive cholesterol-lowering therapy with oral anticoagulation medication in elderly patients with atrial fibrillation: a randomized, double-blind placebo-controlled study. *Drugs Aging* 26:585-593.
- Erber R, Di Mario C, Bartunek J, et al (2007). Temporary scaffolding of coronary arteries with bioabsorbable magnesium stent: a prospective, non-randomised multicenter trial. *Lancet* 369:1869-1875.
- Erber R, Haude M, Höpp HW, et al (1998). Coronary-artery stenting compared with balloon angioplasty for restenosis after initial balloon angioplasty. *N Eng J Med* 339:1672-1678.
- Fang MC, Go AS, Chang Y, et al (2011). A new risk scheme to predict arfarin-associated hemorrhage: the ATRIA (anticoagulation and risk factors in atrial fibrillation) study. *J Am Coll Cardiol* 58:395-401.
- Fasseas P, Orford JL, Panetta CJ, et al (2004). Incidence, correlates, management, and clinical outcome of coronary perforation: analysis of 16,298 procedures. *Am Heart J* 147:140-145.
- Ferrante G, Presbitero P, Whitbourn R, et al (2013). Current applications of optical coherence tomography for coronary intervention. *Int J Cardiol* 165:7-16.
- Ferreiro JL, Ueno M, Angiolillo DJ, et al. (2009). Cangrelor: e review on its mechanism of action and clinical development. *Expert Rev Cardiovasc Ther* 7:1195-1201.
- Finn AV, Kolodgie FD, Harnek J, et al (2005). Differential response of delayed healing and persistent inflammation at sites of overlapping

- sirolimus- or paclitaxel-eluting stents. *Circulation* 112:270-278.
- Finn AV, Joner M, Nakazawa G, et al (2007). Pathological correlates of late drug-eluting stent thrombosis: strut coverage as a marker of endothelialization. *Circulation* 115:2435-2441.
- Fischman DL, Leon MB, Baim DS, et al (1994). A randomized comparison of coronary-stent placement and balloon angioplasty in the treatment of coronary artery disease. *N Eng J Med* 331: 496-501.
- Freixa X, Almasood AS, Khan SQ, et al (2013). Choice of stent and outcomes after treatment of drug-eluting stent restenosis in highly complex lesions. *Catheter Cardiovasc Interv* 81:E16-E22.
- Fröhlich GM, Lansky AJ, Ko DT, et al (2013). Drug eluting balloons for *de novo* coronary lesions – a systematic review and meta-analyses. *BMC Med* 11:123.
- Gallero P, Roldán V, Torregrosa JM, et al (2012). Relation of the HAS-BLED bleeding risk score to major bleeding, cardiovascular events, and mortality in anticoagulated patients with atrial fibrillation. *Circ Arrhythm Electrophysiol* 5:312-318.
- Garasic JM, Edelman ER, Squire JC, et al (2000). Stent and artery geometry determine intimal thickening independent of arterial injury. *Circulation* 101:812-818.
- Giampaolo N, Belloni F, Cosentino N, et al (2013). Case-Control Registry of Excimer Laser Coronary Angioplasty Versus Distal Protection Devices in Patients With Acute Coronary Syndromes due to Saphenous Vein Graft Disease. *Am J Cardiol* 112:1586-1891.
- Giannakakou P, Robey R, Fojo T, et al (2001). Low concentrations of paclitaxel induce cell type-dependent p53, p21 and G1/G2 arrest instead of mitotic arrest: molecular determinants of paclitaxel-induced cytotoxicity. *Oncogene* 20:3806-3813.
- Giraud-Sauveur Y (2007). Titan 2 bio-active stent (BAS) with titanium-NO. *Eurointerv* 3:526-528.
- Grech ED (2003a). ABC of interventional cardiology: percutaneous coronary intervention. I: History and development. *BMJ* 326:1080-1082.
- Grech ED (2003b). ABC of interventional cardiology: percutaneous coronary intervention. II: the procedure. *BMJ* 326:1137-1140.
- Grossman W (2000). Historical perspective and present practice of cardiac catheterization. In: Baim D, ed. *Grossman's Cardiac Catheterization, angiography and intervention*, 6th Ed. Philadelphia: Lippincott Williams & Wilkins, 1-8.
- Grube E, Silber S, Hauptmann K, et al (2003). TAXUS I: six- and twelve-months results from a randomized, double-blind trial on a slow-release paclitaxel-eluting stent for *de novo* coronary lesions. *Circulation* 107:38-42.
- Grüntzig AR, Senning Å, Siegenthaler WE (1979). Nonoperative dilatation of coronary-artery stenosis. percutaneous transluminal coronary angioplasty. *N Engl J Med* 301:61-68.
- Guagliumi G, Costa MA, Sirbu V, et al (2011). Strut coverage and late malapposition with paclitaxel-eluting stents compared with bare metal stents in acute myocardial infarction: optical coherence tomography substudy of the Harmonizing Outcomes with Revascularization and Stents in Acute Myocardial Infarction (HORIZONS-AMI) Trial. *Circulation* 123:274-281.
- Guagliumi G, Sirbu V, Bezerra H, et al (2010). Strut coverage and vessel wall response to zotarolimus-eluting and bare-metal stents implanted in patients with ST-segment elevation myocardial infarction: the OCTAMI (Optical Coherence Tomography in Acute Myocardial Infarction) study. *JACC Cardiovasc Interv* 3:680-687.
- Gukathasan N, Mehran R (2013). Acute coronary syndromes: advances in antithrombotics. *Curr Atheroscler Rep* 15:318.
- Gulmez S, Lassen A, Aalykke C, et al (2009). Do statins protect against gastrointestinal bleeding? *Br J Clin Pharmacol* 67:460-465.
- Gurbel PA, Antonino MJ, Tantry US (2009). Recent developments in clopidogrel pharmacology and their relation to clinical outcomes. *Expert Opin Drug Metab Toxicol* 5:989-1004.
- Gurbel PA, Bliden KP, Butler K, et al (2009). Randomized double-blind assessment of the ONSET and OFFSET of the antiplatelet effects of ticagrelor versus clopidogrel in patients with stable coronary artery disease: the ONSET/OFFSET study. *Circulation* 120:2577-2585.
- Gurbel PA, Bliden KP, Hiatt BL, et al (2003). Clopidogrel for coronary stenting: response variability, drug resistance and the effect of pretreatment platelet reactivity. *Circulation* 107:2908-2913.
- Gutensohn K, Beythien C, Bau J, et al (2000). In vitro analyses of diamond-like carbon coated stents: Reduction of metal ion release, platelet activation and thrombogenicity. *Thromb Res* 99:577-585.
- Gutiérrez-Chigo JL, van Geuns RJ, Regar E, et al. (2011). Tissue coverage of a hydrophilic polymer-coated zotarolimus-eluting stent vs. a fluoropolymer-coated everolimus-eluting stent at 13-months follow-up: an optical coherence tomography substudy from the RESOLUTE All Comers trial. *Eur Heart J* 32:2454-2463.
- Hamon M, Baron J-C, Viader F, et al (2008). Periprocedural stroke and cardiac catheterization. *Circulation* 118:678-83.

- Hamon M, Niculescu R, Deleanu R, et al (2013). Clinical and angiographic experience with a third-generation drug-eluting Orsiro stent in the treatment of single de novo coronary artery lesions (BIOFLOW-I): a prospective, first-in-man study. *Eurointerv* 8:1006-1011.
- Hannawi B, Lam WW, Wang S, et al (2014). Current use of Fractional Flow Reserve: a Nationwide Survey. *Texas Heart Inst J* 41:579-584.
- Haude M, Erbel R, Erne P, et al (2013). Safety and performance of the drug-eluting absorbable metal scaffold (DREAMS) in patients with de novo coronary lesions: 12 month results of the prospective, multicenter, first-in-man BIOSOLVE-1 trial. *Lancet* 381:836-844.
- Haide M, Lee SW, Worthley SG, et al (2013). The REMEDEE Trial: A Randomised Comparison of a Combination Sirolimus-Eluting Endothelial Progenitor Cell Capture Stent With a Paclitaxel-Eluting Stent. *JACC Cardiovasc Interv* 4:334-343.
- Head SJ, Kieser TM, Falk V, et al (2013). Coronary artery bypass grafting: Part 1: the evolution over the first 50 years. *Eur Heart J* 34:2862-2872.
- Held C, Asenblad N, Bassand JP, et al. (2011). Ticagrelor versus clopidogrel in patients with acute coronary syndromes undergoing coronary artery bypass surgery: results from the PLATO (platelet inhibition and patient outcomes) trial. *J Am Coll Cardiol* 57:672-684.
- Helft G, Gilard M, Le Feuvre C, et al (2006). Drug insight: antithrombotic therapy after percutaneous coronary intervention in patients with an indication for anticoagulation. *Nat Clin Pract Cardiovasc Med* 3:673-680.
- Hennekens CH (2007). Aspirin in the treatment and prevention of cardiovascular disease: current perspective and future directions. *Curr Atheroscler Rep* 311:409-416.
- Hirch J, Dalen J, Anderson DR, et al (2001). Oral anticoagulants: mechanism of action, clinical effectiveness, and optimal therapeutic range. *Chest* 119(1 Suppl):8S-21S.
- Hirsh J, Raschke R (2004). Heparin and low-molecular-weight heparin: the Seventh ACCP Conference on Antithrombotic and Thrombolysis Therapy. *Chest* 126(3suppl):188S-203S.
- Hoffmann R, Mintz GS, Dussaillant GR, et al (1996). Pattern and mechanism of in-stent restenosis. A serial intravascular ultrasound study. *Circulation* 94:1247-1254.
- Huang D, Swanson EA, Lin CP, et al (1991). Optican coherence tomography. *Science* 254:1178-1181.
- Huang N, Yang P, Leng YX, et al (2003). Hemocompatibility of titanium oxide films. *Biomaterials* 24:2177-2187.
- Hylek E, Evans-Molina C, Shea C, et al (2007). Major hemorrhage and tolerability of warfarin in the first year of therapy among elderly patients with atrial fibrillation. *Circulation* 115:2689-2696.
- Indermuehle A, Bahl R, Lansky AJ, et al (2013). Drug-eluting balloon angioplasty for in-stent restenosis: a systematic review and meta-analyses of randomized controlled trials. *Heart* 99:327-333.
- Jaffer AK, Ahmed M, Brotman DJ, et al (2005). Low-molecular-weight-heparins as periprocedural anticoagulation for patients on long-term warfarin therapy: a standardized bridging therapy protocol. *J Thromb Thrombolysis* 20:11-16.
- James S, Angiolillo DJ, Cornel JH, et al (2010a). Ticagrelor vs. clopidogrel in patients with acute coronary syndromes and diabetes: a substudy from the platelet inhibition and patient outcomes (PLATO) trial. *Eur Heart J* 31:3006-3016.
- James S, Budaj A, Aylward P, et al (2010b). Ticagrelor versus clopidogrel in acute coronary syndromes in relation to renal function: results from the platelet inhibition and patient outcomes (PLATO) trial. *Circulation* 122:1056-1067.
- James SK, Row MT, Cannon CP, et al (2011). Ticagrelor versus clopidogrel in patients with acute coronary syndromes intended for non-invasive management: substudy from prospective randomized platelet inhibition and patient outcomes (PLATO) trial. *BMJ* 342:d3527.
- Jamula E, Lloyd N, Schwalm J, et al (2010). Safety of uninterrupted anticoagulation in patients requiring elective coronary angiography with or without percutaneous coronary intervention: A systematic review and metaanalyses. *Chest* 138:840-847.
- January CT, Wann LS, Alpert JS, et al (2014). 2014 AHA/ACC/HRS Guideline for the Management of Patients With Atrial Fibrillation: A Report of the American College of Cardiology/American Heart Association Task Force on Practice Guidelines an the Heart Rhythm Society. *Circulation* 130:e199-267.
- Jensen LO, Maeng M, Kaltoft A, et al (2007). Stent thrombosis, myocardial infarction, and death after drug-eluting and bare-metal stent coronary interventions. *J Am Coll Cardiol* 50:463-470.
- Jernberg T, Payne CD, Winters KJ, et al (2006). Prasugrel achieves greater inhibition of platelet aggregation and a lower rate of non-responders compared with clopidogrel in aspirin treated patients with stable coronary artery disease. *Eur Heart J* 27:1166-1173.
- Jessup DB, Coletti AT, Muhlestein JB, et al (2003). Elective coronary angiography and percutaneous coronary intervention during uninterrupted warfarin therapy. *Catheter Cardiovasc Interv* 60:180-184.

- Johnson NP, Kirkeeide RL, Gould KL, et al (2012). In discordance of coronary flow reserve and fractional flow reserve due to methodology or clinically relevant coronary pathophysiology? *JACC Cardiovasc Imaging* 5:193-202.
- Jolly SS, Amlani S, Hamon M, et al (2009). Radial versus femoral access for coronary angiography or intervention and the impact on major bleeding and ischemic events; a systematic review and meta-analyses on randomized trials. *Am Heart J* 157:132-40.
- Jolly SS, Cairns JA, Yusuf S, et al (2015). Randomized Trial of Primary PCI with or without Routine Manual Thrombectomy. *N Eng J Med* 372:1389-1398.
- Joner M, Finn AV, FARB A, et al (2006). Pathology of drug-eluting stents in humans: delayed healing and late thrombotic risk. *J Am Coll Cardiol* 48:193-202.
- Jones GT, Kay IP, Chu JW, et al (2006). Elevated plasma active matrix metalloproteinase-9 level is associated with coronary artery in-stent restenosis. *Arterioscler Thromb Vasc Biol* 26:e121-125.
- Kaluski E, Tsai S, Klapholz M (2008). Coronary stenting with MGuard: from conception to human trials. *Cardiovasc Revasc Med* 9:88-94.
- Kandzari DE, Leon MB, Popma JJ, et al (2006). Comparison of zotarolimus-eluting stents in patients with native coronary artery disease: A randomized controlled trial. *J Am Coll Cardiol* 48:2440-2447.
- Kanei Y, Kwan T, Nakra NC, et al (2011). Transradial cardiac catheterization: a review of access site complications. *Catheter Cardiovasc Interv* 78:840-6.
- Kang SJ, Mintz GS, Akasaka T, et al (2011). Optical coherence tomographic analysis of in-stent neoatherosclerosis after drug-eluting stent implantation. *Circulation* 123:2954-2963.
- Karaźniewicz-Lada M, Danielak D, Głowka F (2012). Genetic and non-genetic factors affecting the response to clopidogrel therapy. *Expert Opin Pharmacother* 13:663-683.
- Karjalainen PP, Kiviniemi TO, Lehtinen T, et al (2013). Neointimal coverage and vasodilator response to titanium-nitride-oxide-coated bioactive stents and everolimus-eluting stents in patients with acute coronary syndrome: insights from the BASE-ACS trial. *Int J Cardiovasc Imaging* 29:1693-1703.
- Karjalainen PP, Nammas W (2012). Optical coherence tomography: On the way to decipher the 'Rosetta stone'. *Int J Cardiol* 159:79-81.
- Karjalainen PP, Niemelä M, Airaksinen JKE, et al (2012). A prospective randomised comparison of titanium-nitride-oxide-coated bioactive stents with everolimus-eluting stents in acute coronary syndrome: the BASE-ACS trial. *Eurointerv* 8:306-315.
- Karjalainen PP, Porela P, Ylitalo A, et al (2007). Safety and efficacy of combined antiplatelet-warfarin therapy after coronary stenting. *Eur Heart J* 28:726-732.
- Karjalainen PP, Vikman S, Niemelä M, et al (2008). Safety of percutaneous coronary intervention during uninterrupted oral anticoagulant treatment. *Eur Heart J* 29:1001-1010.
- Karjalainen PP, Ylitalo A, Airaksinen JK, et al (2011). Five-year clinical outcome of titanium-nitride-oxide-coated bioactive stent implantation in a real-world population: a comparison with paclitaxel-eluting stents: the PORI registry. *J Interv Cardiol* 24:1-8.
- Karjalainen PP, Ylitalo A, Airaksinen KE (2006). Real world experience with the TITAN stent: a 9-month follow-up report from the Titan Pori registry. *Eurointerv* 2:187-191.
- Karrowni W, Vyas A, Giacomino B, et al (2013). Radial versus femoral access for primary percutaneous interventions in ST-segment elevation myocardial infarction patients: a meta-analysis of randomized controlled trials. *J Am Cardiol Intv* 6:814-823.
- Kastrati A, Mehilli J, von Beckerath N, et al (2005). Sirolimus-eluting stent or paclitaxel-eluting stent vs balloon angioplasty for prevention of recurrences in patients with coronary in-stent restenosis: a randomized controlled trial. *JAMA* 293:165-171.
- Kastrati A, Mehilli J, Dirschinger J, et al (2001). Restenosis after coronary placement of various stent types. *Am J Cardiol* 87:34-39.
- Kastrati A, Neumann FJ, Mehilli J, et al (2008). Bivalirudin versus unfractionated heparin during percutaneous coronary intervention. *New Engl J Med* 359: 688-696.
- Kastrati A, Schomic A, Elezi S, et al (1997). Predictive factors of restenosis after coronary stent placement. *J Am Coll Cardiol* 30:1428-1436.
- Kedev S, Zafirovska B, Dharma S, et al (2013). Safety and feasibility of transulnar catheterization when ipsilateral radial access is not available. *Catheter Cardiovasc Interv* 83:E51-60.
- Kedhi E, Stone GW, Kereiakes DJ, et al (2012). Stent thrombosis: insight on outcomes, predictors and impact of dual therapy interruption from the SPIRIT II, SPIRIT III, SPIRIT IV and COMPARE trials. *Eurointerv* 2012:599-606.
- Kereiakes DJ, Cox DA, Hermiller JB, et al (2003). Usefulness of a cobalt chromium coronary stent alloy. *Am J Cardiol* 92:463-466.
- Khouzam RM, Shaheen M, Aziz RK, et al (2012). The important role of inflammatory biomarkers pre and post bare-metal and drug-eluting stent implantation. *Can J Cardiol* 28:700-705.

- Kiemeneij F, Laarman GJ (1995). Transradial artery coronary angioplasty. *Am Heart J* 129:1-8.
- Kiemeneij F, Laarman GJ, Odekerken D, et al (1997). A randomized Comparison of Percutaneous transluminal Coronary Angioplasty by the Radial, Brachial and Femoral Approaches: The Access Study. *J Am Coll Cardiol* 29:1269-75.
- Kim J-S, Fan C, Choi D, et al (2011). Different patterns of neointimal coverage between acute coronary syndrome and stable angina after various type of drug-eluting stents implantation; 9-months follow-up optical coherence tomography study. *Int J Cardiol* 146:341-346.
- Kim J-S, Jang I-K, Kim J-S, et al (2009). Optical coherence tomography evaluation of zotarolimus-eluting stents at 9-month follow-up: comparison with sirolimus-eluting stents. *Heart* 95:1907-1912.
- Kirtane AJ, Leon MW, Ball ME, et al (2013). The "final" 5-year follow-up from the ENDEAVOR IV Trial comparing a zotarolimus-eluting stent with a paclitaxel-eluting stent. *JACC Cardiovasc Interv* 4:325-333.
- Kiviniemi T (2008). Assessment of coronary blood flow and the reactivity of the microcirculation noninvasively with transthoracic echocardiography. *Clin Physiol Funct Imaging* 28:145-155.
- Kiviniemi T, Puurunen M, Schlitt A, et al (2014a). Bare-metal vs. drug-eluting stents in patients with atrial fibrillation undergoing percutaneous coronary intervention. *Circ J* 78(11):2674-2681.
- Kiviniemi T, Puurunen M, Schlitt A, et al (2014b). Performance of bleeding risk-prediction scores in patients with atrial fibrillation undergoing percutaneous coronary intervention. *Am J Cardiol* 113:1995-2001.
- Koch KT, Piek JJ, de winter RJ, et al (1997). Early ambulation after coronary angioplasty and stenting with six French guiding catheters and low-dose heparin. *Am J Cardiol* 80:1084-1086.
- Kubo T, Akasaka T, Shite J, et al (2013). OCT Compared With IVUS in a Coronary Lesion Assessment: The OPUS-CLASS Study. *JACC Cardiovasc Imaging* 6:1095-1104.
- Kubo T, Imanishi T, Takarada S, et al (2007). Assessment of culprit lesion morphology in acute myocardial infarction: ability of optical coherence tomography compared with intravascular ultrasound and coronary angiography. *J Am Coll Cardiol* 50:933-939.
- Kuchulakanti PK, Chu WW, Torguson R, et al (2006). Correlates and long-term outcomes of angiographically proven stent thrombosis with sirolimus- and paclitaxel-eluting stents. *Circulation* 113:1108-1113.
- Kume T, Akasaka T, Kawamoto T, et al (2006). Assessment of coronary arterial thrombus by optical coherence tomography. *Am J Cardiol* 97:1713-1717.
- Kutryk MJ, Kuliszewski MA (2009). In vivo endothelial progenitor cell seeding for the accelerated endothelialization of endovascular devices. Abstract presented in TCT 2003. *Am J Cardiol* 92:94.
- Kvok CS, Rao SV, Myint PK, et al (2014). Major bleeding after percutaneous coronary intervention and risk of subsequent mortality: a systematic review and meta-analyses. *Open Heart* 1:e000021.
- Köster R, Vieluf D, Kiehn M, et al (2000). Nickel and molybdenum contact allergies in patients with coronary in-stent restenosis. *Lancet* 356:1895-1897.
- Lagerqvist B, Fröbert O, Olivecrona GK, et al (2014). Outcomes 1 Year after Thrombus Aspiration for Myocardial Infarction. *N Eng J Med* 371:1111-1120.
- Lahtela H, Rubboli A, Schitt A, et al (2012). Heparin bridging vs. uninterrupted oral anticoagulation in patients with Atrial Fibrillation undergoing Coronary Artery Stenting. Results from the AFCAS registry. *Circ J* 76:1363-1368.
- Lamberts M, Gislason GH, et al (2013). Oral anticoagulation and antiplatelets in atrial fibrillation patients after myocardial infarction and coronary intervention. *J Am Coll Cardiol* 62:981-989.
- Larson BJB, Zumberg MS, Kitchens CS (2005). A feasibility study of continuing dose-reduced warfarin for invasive procedures in patients with thromboembolic risk. *Chest* 127:922-927.
- Lee CH, Lim J, Low A, et al (2006). Late angiographic stent thrombosis of polymer based paclitaxel eluting stent. *Heart* 92:551-553.
- Lehtinen T, Airaksinen KE, Karjalainen PP (2012a). Stent strut coverage of titanium-nitride-oxide coated stent compared to paclitaxel-eluting stent in acute myocardial infarction: TITAX-OCT study. *Int J Cardiovasc Imaging* 28:1859-1866.
- Lehtinen T, Kiviniemi TO, Mikkelsen J, et al (2012b). Early vascular healing after endothelial progenitor cell capturing stent implantation. *J Inv Cardiol* 24:631-635.
- Lembo NJ, Black AJ, Roubin GS, et al. (1990). Effect of pre-treatment with aspirin versus aspirin plus dipyridamole on frequency and type of acute complications of percutaneous transluminal coronary angioplasty. *Am J Cardiol* 65:422-426.
- Leon MB, Baim DS, Popma JJ, et al (1998). A clinical trial comparing three antithrombotic drug regimens after coronary-artery stenting. Stent Anticoagulation Restenosis Study Investigators. *N Eng J Med* 339:1665-1671.
- Levine Gn, Bates ER, Blankenship JC, et al (2012). 2011 ACCF/AHA/SCAI Guideline for Percutaneous

- Coronary Intervention: executive summary: a report of the American College of Cardiology Foundation/American Heart Association Task Force on Practice Guidelines and the Society for Cardiovascular Angiography and Interventions. *Catheter Cardiovasc Interv* 79:453-495.
- Limacher A, Räber L, Laube E, et al (2012). Clinical long-term outcome after implantation of titanium-nitride-oxide coated stents compared with paclitaxel- or sirolimus-eluting stents: propensity-score matched analysis. *Eurointerv* 7:1043-1050.
- Lincoff AM, Bittl JA, Harrington RA, et (2003). Bivalirudin and provisional glycoprotein IIb/IIIa blockade compared with heparin and planned glycoprotein IIb/IIIa blockade during percutaneous coronary intervention: REPLACE-2 randomized trial. *JAMA* 289:853-863.
- Lincoff AM, Bittl JA, Kleiman NS, et al (2004). Comparison of bivalirudin versus heparin during percutaneous coronary intervention (the Randomized Evaluation of PCI Linking Angiomax to Reduced Clinical Events [REPLACE]-1 trial). *Am J Cardiol* 93:1092-1096.
- Lincoff AM, Kleiman NS, Kottke-Marchant K, et al (2002). Bivalirudin with planned or provisional abciximab versus low-dose heparin and abciximab during percutaneous coronary revascularization: results of the Comparison of Abciximab Complications with Hirulog for Ischemic Events Trial (CACHET). *Am Heart J* 143:847-853.
- Lip GY, Andreotti F, Fauchier L, et al (2011). Bleeding risk assessment and management in atrial fibrillation patients: a position document from the European Heart Rhythm Association, endorsed by the European Society of Cardiology Working Group on Thrombosis. *Europace* 13:723-746.
- Lip GYH, Frison L, Halperin JL, et al (2011). Comparative validation of a novel risk score for predicting bleeding risk in anticoagulated patients with atrial fibrillation: the has-BLED (hypertension, abnormal renal/liver function, stroke, bleeding history or predisposition, labile INR, elderly, drugs/alcohol concomitantly) score. *J Am Coll Cardiol* 57:173-180.
- Lip GY, Windecker S, Huber K, et al (2014). Management of antithrombotic therapy in atrial fibrillation patients presenting with acute coronary syndrome and/or undergoing percutaneous coronary or valve interventions: a joint consensus document of the European Society of Cardiology Working Group of Thrombosis, European Heart Rhythm Association (EHRA), European Association of Percutaneous Cardiovascular Interventions (EAPCI) and European Association of Acute Cardiac Care (ACCA) endorsed by the Heart Rhythm Society (HRS) and Asia-Pacific Heart Rhythm Society (APHRS). *Eur Heart J* 35:3155-3179.
- Liu L, Gardecki JA, Nadkarni SK, et al (2011). Imaging the Subcellular structure of Human Coronary atherosclerosis Using 1- μ m Resolution Optical Coherence Tomography (μ OCT). *Nat Med* 17:1010-1014.
- Lopez-Palop R, Pinar E, Lozano I, et al (2004). Utility of the fractional flow reserve in the evaluation of angiographically moderate in-stent restenosis. *Eur Heart J* 25:2040-2047.
- Lowe HC, Narula J, Fujimoto Jg, et al (2011). Intracoronary optical diagnostics: current status, limitations, and potential. *J Am Coll Cardiol Interv* 4:1257-1270.
- MacNeill BD, Jang IK, Bouma BE, et al. Focal and multi-focal plaque macrophage distributions in patients with acute and stable presentations of coronary artery disease. *J Am Coll Cardiol* 44:972-979.
- Mamas MA, Ratib K, Routledge H, et al (2012). Influence of access site selection on PCI-related adverse events in patients with STEMI: meta-analyses of randomized controlled trials. *Heart* 98:303-311.
- Mann T, Cubeddu G, Bowen J, et al (1998). Stenting in Acute Coronary Syndromes: A Comparison of Radial Versus Femoral Access Sites. *J Am Coll Cardiol* 32:572-6.
- Massberg S, Byrne RA, Kastrati A, et al (2011). Polymer-free sirolimus- and probucol-eluting versus new generation zotarolimus-eluting stents in coronary artery diseases: the Intracoronary Stenting and Angiographic Results: Test Efficacy of Sirolimus- and Probucol-Eluting versus Zotarolimus-eluting Stents (ISAR-TEST 5) trial. *Circulation* 124:624-632.
- Mauri L, Bonan R, Weiner BH, et al (2002). Cutting balloon angioplasty for the prevention on restenosis: results of the cutting balloon global randomized trial. *Am J Cardiol* 90:1079-1083.
- Mauri L, Cox D, Hermiller J, et al (2007). The PROXIMAL trial: proximal protection during saphenous vein graft intervention using the Proxis Embolic Protection System: a randomized, prospective multicenter clinical trial. *J Am Coll Cardiol* 50:1442-1449.
- Mauri L, Hsieh WH, Massaro Jm, et al (2007). Stent thrombosis in randomised clinical trials of drug-eluting stents. *N Eng J Med* 356:1020-1029.
- McCullough P (2006). Outcomes of contrast-induced nephropathy: Experience in patients undergoing cardiovascular intervention. *Catheter Cardiovasc Interv* 67:335-343.
- McFadden EP, Stabile E, Regar E, et al (2004). Late thrombosis in drug-eluting stents after

- discontinuation of antiplatelet therapy. *Lancet* 364:1519-1521.
- Mega JL, Braunwald E, Mohanavelu S, et al (2009). Rivaroxaban versus placebo in patients with acute coronary syndromes (Atlas Acs-Timi 46): a randomised, double blind, phase II trial. *Lancet* 374:29-38.
- Mega JL, Braunwald E, Wiviott SD, et al (2012). ATLAS ACS 2-TIMI 51 Investigators. Rivaroxaban in patients with recent acute coronary syndrome. *N Eng J Med* 366:9-19.
- Mehta SR, Eikelboom JW, Rupprecht HJ, et al (2002). Efficacy of hirudin in reducing cardiovascular events in patients with acute coronary syndrome undergoing early percutaneous coronary intervention. *Eur Heart J* 23:117-123.
- Mehta SR, Tanguay JF, Eikelboom JW, et al (2010). Double-dose versus standard-dose clopidogrel and high-dose versus low-dose aspirin in individuals undergoing percutaneous coronary intervention for acute coronary syndromes (CURRENT-OASIS 7): a randomised factorial trial. *Lancet* 376:1233-1243.
- Meredith IT, Ormiston J, Whitbourn R, et al (2005). First-in-human study of the Endeavor ABT-578-eluting phosphorylcholine-encapsulated stent system in de novo native coronary artery lesions: Endeavor I trial. *Eurointerv* 1:157-164.
- Meredith IT, Verheye S, Dubois CL, et al (2012). Primary endpoint results of the EVOLVE trial. A randomized evaluation of a novel bioabsorbable polymer-coated, everolimus-eluting coronary stents. *J Am Coll Cardiol* 59:1362-1370.
- Meredith IT, Worthley S, Whitbourn R, et al (2009). Clinical and angiographic results with the next-generation resolute stent system: A prospective, multicenter, first-in-human trial. *JACC Cardiovasc Interv* 2:977-985.
- Meuwissen M, Siebes M, Chamuleau SA, et al (2002). Hyperemic stenosis resistance index for evaluation of functional coronary lesion severity. *Circulation* 106:441-446.
- Montalescot G, Bolognese L, Dudek D, et al (2013). Pretreatment with Prasugrel in NON-ST-Segment Elevation Acute Coronary Syndromes. *N Eng J Med* 369:999-1010.
- Montalescot G, Wiviott SD, Braunwald E, et al (2009). Prasugrel compared with clopidogrel in patients undergoing percutaneous coronary intervention for ST-elevation myocardial infarction (TRITON-TIMI 38): double-blind, randomized controlled trial. *Lancet* 373:723-731.
- Montalescot G, Zeymer U, Silvain J, et al (2011). Intravenous enoxaparin or unfractionated heparin in primary percutaneous coronary intervention for ST-elevation myocardial infarction: the international randomised open-label ATOLL trial. *Lancet* 378:693-703.
- Morice M-C, Serruys PW, Sousa JE et al (2002). A randomized comparison of a sirolimus-eluting stent with a standard stent for coronary revascularization. *N Eng J Med* 346:1773-1780.
- Moschovitis A, Simon R, Seidenstücker A et al (2010). Randomised comparison of titanium-oxide coated stents with bare metal stents: five year follow-up of the TINOX trial. *Eurointerv* 6:63-68.
- Moscucci M, Fox KA, Cannon CP, et al (2003). Predictors of major bleeding in acute coronary syndromes: the Global Registry of Acute Coronary Events (GRACE). *Eur Heart J* 24:1815-23.
- Moses JW, Leon MB, Popma JJ, et al (2003). Sirolimus-eluting stents versus standard stents in patients with stenosis in a native coronary artery. *N Eng J med* 349:1315-1323.
- Mosseri M, Miller H, Tamari I, et al (2006). The titanium-NO stent: results of a multicenter registry. *Eurointerv* 2:192-196.
- Mosseri M, Tamari I, Plich M, et al (2005). Short and long term outcome of the Titanium-NO stent registry. *Cardiovasc Revasc Med* 6:(1),2-6.
- Muller JE, Tofler GH, Stone PH (1989). Circadian variation and triggers of onset of acute cardiovascular disease. *Circulation* 79:733-743.
- Murata A, Wallace-Bradley D, Tellez A, et al (2010). Accuracy of optical coherence tomography in the evaluation of neointimal coverage after stent implantation. *JACC Cardiovasc Imaging* 3:76-84.
- Nakazawa G, Finn AV, Joner M, et al (2008). Delayed arterial healing and increased late stent thrombosis at culprit sites after drug-eluting stent placement for acute myocardial infarction patients; an autopsy study. *Circulation* 118:1138-1145.
- Nakazawa G, Otsuka F, Nakano M, et al (2011). The pathology of neoatherosclerosis in human coronary implants: bare-metal and drug-eluting stents. *J Am Coll Cardiol* 57:1314-1322.
- Navarese EP, Tarantini G, Musumeci G, et al (2013). Manual vs mechanical thrombectomy during PCI for STEMI: a comprehensive direct and adjusted indirect meta-analyses of randomized trials. *Am J Cardiovasc Dis* 3:146-157.
- Ndrepepa G, Schulz S, Neuman F-J, et al (2013). Bleeding after percutaneous coronary intervention in women and men match for age, body mass index, and type of antithrombotic therapy. *Am Heart J* 166:534-540.
- Nishio S, Kosuga K, Igaki K, et al (2012). Long-Term (>10 Years) clinical outcomes of first-in-human biodegradable poly-L-lactic acid coronary stents: Igaki-Tamai stents. *Circulation* 125:2343-2352.

- Nobuyoshi M, Kimura T, Nosaka H, et al (1988). Restenosis after successful percutaneous transluminal coronary angioplasty: serial angiographic follow-up of 229 patients. *J Am Coll Cardiol* 12:616-623.
- Noman A, Egred M, Bagnall A, et al (2012). Impact of thrombus aspiration during primary percutaneous coronary intervention on mortality in ST-segment elevation myocardial infarction. *Eur Heart J* 33:3054-3061.
- O'Doghue ML, Bhatt DL, Wiviott SD, et al (2011). Safety and tolerability of atopaxar in the treatment of patients with acute coronary syndromes: the lessons from antagonizing the cellular effects of Thrombin-Acute Coronary Syndromes Trial. *Circulation* 123:1843-1853.
- O'Gara PT, Kushner FG, Ascheim DD, et al (2013). 2013 ACCF/AHA guideline for the management of ST-elevation myocardial infarction: executive summary: a report of the American College of Cardiology Foundation/American Heart Association Task Force on Practice Guidelines: developed in collaboration with the American College of Emergency Physicians and Society for Cardiovascular Angiography and Interventions. *Catheter Cardiovasc Interv* 82(1):E1-27.
- Oldgren J, Budaj A, Granger CB, et al (2011). Dabigatran vs. placebo in patients with acute coronary syndromes on dual antiplatelet therapy: a randomized, double-blind, phase II trial. *Eur Heart J* 32:2781-2789.
- Oldgren J, Wallentin L, Alexander JH, et al (2013). New oral anticoagulants in addition to single or dual antiplatelet therapy after an acute coronary syndrome: a systematic review and meta-analysis. *Eur Heart J* 34:1670-1680.
- Onuma Y, Serruys PW, Ormiston JA, et al (2010). Three-year results of clinical follow-up after a bioresorbable evero-limus eluting scaffold in patients with de novo coronary artery disease: The ABSORB trial. *Eurointervention* 6:47-53.
- Oprea AD, Popescu WM (2013). P2Y12 Receptor Inhibitors in Acute Coronary Syndromes: What is New on the Horizon? *Cardiol Res Pract* 2013:195456.
- Otsuka F, Nakano M, Ladich E, et al (2012). Pathologic etiologies of late and very late stent thrombosis following first-generation drug-eluting stent placement. *Thrombosis* 2012:608593.
- Park SJ, Lee CW, Hong MK, et al (2002). Comparison of gold-coated NIR stents with uncoated NIR stents in patients with coronary artery diseases. *Am J Cardiol* 89:872-875.
- Parodi G, Valenti R, Bellandi B, et al (2013). Comparison of prasugrel and ticagrelor loading doses in the ST-segment elevation myocardial infarction patients: RAPID (Rapid Activity of Platelet Inhibitor Drugs) primary PCI study. *J Am Coll Cardiol* 61:1601-1606.
- Patel N, Banning AP (2013). Bioabsorbable scaffolds for the treatment of obstructive coronary artery disease: the next revolution in coronary intervention? *Heart* 99:1236-1243.
- Patrono C, Ciabattini G, Patrignani P, et al (1985). Clinical pharmacology of platelet cyclo-oxygenase inhibition. *Circulation* 72:1177-1184.
- Pfisterer M, Brunner-La Rocca HP, Buser PT, et al (2006). Late clinical events after clopidogrel discontinuation may limit the benefit of drug-eluting stents: an observational study of drug-eluting versus bare-metal stents. *J Am Coll Cardiol* 48:2584-2591.
- Pilgrim T, Räber L, Limacher A, et al (2011). Comparison of titanium-nitride-oxide-coated stents with zotarolimus-eluting stents for coronary revascularization a randomized controlled trial. *JACC Cardiovasc Interv* 6:672-678.
- Plow EF, Ginsberg Mh (1989). Cellular adhesion: GPIIb-IIIa as a prototypic adhesion receptor. *Prog Hemost Tromb* 9:117-156.
- Popma JJ, Bittl Ja (2001). Coronary angiography and intravascular ultrasonography. In: Braunwald E, Zipes DP, Libby P eds. *Heart Disease: Textbook of Cardiovascular Medicine*, 6th Ed. Philadelphia: WB Saunders, 387-421.
- Popma JJ, Berger P, Ohman EM, et al (2004). Antithrombotic therapy during percutaneous intervention. The seventh ACCP conference on antithrombotic and thrombolytic therapy. *Chest* 126(3 suppl):576S-599S.
- Prati F, Regar E, Mintz GS, et al (2010). Expert review document on methodology, terminology, and clinical applications of optical coherence tomography: physical principles, methodology of image acquisition, and clinical application for assessment of coronary arteries and atherosclerosis. *Eur Heart J* 31:401-415.
- Puurunen MK, Kiviniemi T, Schlitt A, et al (2014). CHADS₂, CHA₂DS₂-VASc and HAS-BLED as predictors of outcome in patients with atrial fibrillation undergoing percutaneous coronary intervention. *Thromb Res* 133:560-566.
- Puymirat É, Aissaoui N, Silvain J, et al (2013). Comparison of bleeding complications and 3-year survival with low-molecular-weight heparin versus unfractionated heparin for acute myocardial infarction: The FAST-MI registry. *Arc Cardiovasc Dis* 105:347-354.
- Rao SV, Ou FS, Wang TY, et al (2008). Trends in the prevalence and outcomes of radial and femoral approaches to percutaneous coronary intervention: a report from the national cardiovascular data registry. *J Am Coll Cardiol Intv* 1:379-86.

- Ratib K, Mamas MA, Routledge H, et al (2013). Influence of Access Site Choice on Incidence of Neurologic Complications After Percutaneous Coronary Intervention. *Am Heart J* 165:317-324.
- Remuzzi G (1998). Bleeding in renal failure. *Lancet* 1:205-208.
- Rensing BJ, Vos J, et al (2001). Coronary restenosis elimination with a sirolimus eluting stent: first European human experience with 6-month angiographic and intravascular ultrasonic follow-up. *Eur Heart J* 22:2125-2130.
- Roe MT, Armstrong PW, Fox KA, et al (2012). Prasugrel versus clopidogrel for acute coronary syndromes without revascularization. *N Eng J Med* 367:1297-1309.
- Roe MT, Granger CB, Puma JA, et al (2001). Comparison of benefits and complications of hirudin versus heparin for patients with acute coronary syndrome undergoing early percutaneous coronary intervention. *Am J Cardiol* 88:1403-1406.
- Roldán V, Marín F, Fernández H, et al (2013a). Predictive value of the HAS-BLED and ATRIA bleeding scores for the risk of serious bleeding in a “real-world” population with atrial fibrillation receiving anticoagulant therapy. *Chest* 143:179-184.
- Roldán V, Marín F, Manzano-Fernández S, et al (2013b). The HAS-BLED score has better prediction accuracy for major bleeding than CHADS₂ or CHA₂DS₂-VASc scores in anticoagulated patients with atrial fibrillation. *J Am Coll Cardiol* 62:2199-2204.
- Romppanen H, Nammas W, Kervinen K, et al (2013). Stent-oriented versus patient-oriented outcome in patients undergoing early percutaneous coronary intervention for acute coronary syndrome: 2-year report from the BASE-ACS trial. *Ann Med* 45:488-493.
- Rubboli A, Halperin JL, Airaksinen KE, et al (2008). Antithrombotic therapy in patients treated with oral anticoagulation undergoing coronary artery stenting. An expert consensus document with focus on atrial fibrillation. *Ann Med* 40:428-436.
- Rubboli A, Milandri M, Castelvetti C, et al (2005). Meta-analyses of trials comparing oral anticoagulation and aspirin versus dual antiplatelet therapy after coronary stenting. *Cardiology* 104:101-106.
- Rubboli A, Schlitt A, Kiviniemi T, et al (2014). One-year outcome of patients with atrial fibrillation undergoing coronary artery stenting: an analyses of the AFCAS registry. *Clin Cardiol* 37:357-364.
- Ruiz-Nodar JM, Marín F, Hurtado JA, et al (2008). Anticoagulant and antiplatelet therapy use in 426 patients with atrial fibrillation undergoing percutaneous coronary intervention and stent implantation. *J Am Coll Cardiol* 51:818-825.
- Ruiz-Nodar JM, Marin F, Sánchez-Paño J, et al (2009). Efficacy and safety of drug eluting stent use in patients with atrial fibrillation. *Eur Heart J* 30:932-939.
- Räber L, Windecker S (2011). Current status of drug-eluting stents. *Cardiovasc Therapeutics* 29:176-189.
- Samal AK, White CJ (2002). Percutaneous Management of Access Site Complications. *Catheter Cardiovasc Interv* 57:12-23.
- Santilli F, Vazzana R, Liani M, et al (2012). Platelet activation in obesity and metabolic syndrome. *Obes Rev* 13:27-42.
- Sarafoff N, Martischniq A, Wealer J, et al (2013). Triple therapy with aspirin, prasugrel, and vitamin K antagonists in patients with drug-eluting stent implantation and a indication for oral anticoagulation. *J Am Coll Cardiol* 61:2060-2066.
- Sarafoff N, Ndrepepa G, Mehilli J, et al (2008). Aspirin and clopidogrel with or without phenprocoumon after drug eluting coronary stent placement in patients on chronic oral anticoagulation. *J Intern Med* 264:472-480.
- Schampaert E, Cohen EA, Schluter, et al (2004). The Canadian study of the sirolimus-eluting stent in the treatment of patients with long de novo lesions in small native coronary arteries (C-SIRIUS). *J Am Coll Cardiol* 43:1110-1115.
- Schofer J, Schluter M, Gershlick AH, et al (2003). Sirolimus-eluting stents for treatment of patients with long atherosclerosis lesions in small coronary arteries: double-blind, randomized controlled trial (E-SIRIUS). *Lancet* 362:1093-1099.
- Schuler W, Sedrani R, Cottens S, et al (1997). SDR RAD, a new rapamycin derivate. Pharmacological properties in vitro and in vivo. *Transplantation* 64:36-42.
- Schulz S, Kastrati A, Ferenc M, et al (2013). One-year outcomes with abciximab and unfractionated heparin versus bivalirudin during percutaneous coronary interventions in patients with non-ST-segment elevation myocardial infarction: updated results from the ISAR-REACT 4 trial. *Eurointervention* 9:430-436.
- Schiahbasi A, Biondi-Zoccai G, Romagnoli E, et al (2012). Routine upstream versus selective downstream administration of glycoprotein IIb/IIIa inhibitors in patients with non-ST-elevation acute coronary syndromes: a meta-analyses of randomized trials. *Int J Cardiol* 155:243-248.
- Schiele F, Meneveau N, Gilard M, et al (2003). Intravascular ultrasound-guided balloon angioplasty compared with stent: immediate and 6-month results of the multicentre, randomized Balloon Equivalent to Stent Study (BEST). *Circulation* 107:545-551.

- Schlitt A, Rubboli A, Lip GY, et al (2013). The management of patients with atrial fibrillation undergoing percutaneous coronary intervention with stent implantation: in-hospital data from the Atrial Fibrillation undergoing Coronary Artery Stenting study. *Catheter Cardiovasc Interv* 82:E864-E870.
- Schwartz L, Bourassa MG, Lesperance J, et al. (1988). Aspirin and dipyridamole in the prevention of restenosis after percutaneous transluminal coronary angioplasty. *N Eng J Med* 318:1714-1719.
- Seivani Y, Abdel-Wahab M, Geist V, et al (2013). Long-term safety and efficacy of dual therapy with oral anticoagulation and clopidogrel in patients with atrial fibrillation treated with drug-eluting stents. *Clin Res Cardiol* 102:799-806.
- Serruys PW, Chevalier B, Dudek D, et al (2014). A bioresorbable everolimus-eluting scaffold versus a metallic everolimus-eluting stent for ischaemic heart disease caused by de-novo native coronary artery lesions (ABSORB II): an interim 1-year analysis of clinical and procedural secondary outcomes from a randomised controlled trial. *Lancet* 385:43-54.
- Serruys PW, de Jaegere P, Kiemeneij F, et al (1994). A comparison of balloon-expandable-stent implantation with balloon angioplasty in patients with coronary artery diseases. *N Eng J Med* 331:489-495.
- Serruys PW, Herman JP, Simon R, et al (1995). A comparison of hirudin with heparin in the prevention of restenosis after coronary angioplasty. HELVETICA Investigators. *N Engl J Med* 333: 757-763.
- Serruys PW, Keane D (1993). The bailout stent: is a friend in need always a friend indeed? *Circulation* 88:2455-2457.
- Serruys PW, Ormiston JA, Onuma Y, et al (2009). A bioresorbable everolimus-eluting coronary stent system (ABSORB): 2-year outcomes and results from multiple imaging methods. *Lancet* 373:897-910.
- Serruys PW, van Hout B, Bonnier H, et al (1998). Randomised comparison on implantation of heparin-coated stents with balloon angioplasty in selected patients with coronary artery disease (BENESTENT II). *Lancet* 352:673-678.
- Seung-Jung P, Soo-Jin K, Virmani R, et al (2012). In-stent neoatherosclerosis. A final common pathway of late stent failure. *J Am Coll Cardiol* 59:2051-2057.
- Shadzad A, Kemp I, Mars C, et al (2014). Unfractionated heparin versus bivalirudin in primary percutaneous coronary intervention (HEAT-PPCI): an open-label, single centre, randomized controlled trial. *Lancet* 384:1849-1858.
- Shah AK, Sinha RK, Hickok NJ, et al (1999). High-resolution morphometric analyses of human osteoblastic cell adhesion on clinically relevant orthopedic alloys. *Bone* 24:499-506.
- Shelton R, Eftychiou C, Somers K, et al (2013). Bivalirudin in patients undergoing primary percutaneous coronary intervention for acute ST-elevation myocardial infarction: outcomes in a large real-world population. *Eurointervention* 9:118-124.
- Shishikura D, Otsuji S, Takiuchi S, et al (2013). Vaporizing Thrombus With Excimer Laser Before Coronary Stenting Improves Myocardial Reperfusion in Acute Coronary Syndrome. *Circ J* 77:1445-1452.
- Sigwart U, Puel J, Mirkovitch V, et al (1987). Intravascular stents to prevent occlusion and restenosis after transluminal angioplasty. *N Eng J Med* 316:701-706.
- Silber S, Windecker S, Vranckx P, et al (2011). Unrestricted randomized use of two new generation drug-eluting coronary stents: 2-year patient-related versus stent-related outcomes from the RESOLUTE All Comers trial. *Lancet* 377:1241-1247.
- Silvain J, Beygui F, Ankri A, et al (2010). Enoxaparin anticoagulation monitoring in the catheterization laboratory using a new bedside test. *J Am Coll Cardiol* 55:617-625.
- Silvain J, Beygui F, Barthélémy O, et al (2012). Efficacy and safety of enoxaparin versus unfractionated heparin during percutaneous coronary intervention: systematic review and meta-analysis. *BMJ* 344:e553.
- Sketch MH jr, Ball M, Rutherford B, et al (2005). Evaluation of the Medtronic (DRIVER) cobalt-chromium alloy coronary stent system. *Am J Cardiol* 95:8-12.
- Spyropoulos AC, Turpie AG, Dunn AS, et al (2006). Clinical outcomes with unfractionated heparin or low-molecular-weight heparin as bridging therapy in patients on long-term oral anticoagulants: The REGIMEN registry. *J Thromb Haemost* 6:1246-1252.
- Steg PG, Huber K, Andreotti F, et al (2011). Bleeding in acute coronary syndromes and percutaneous coronary interventions: position paper by the Working Group of Thrombosis of the European Society of Cardiology. *Eur Heart J* 32:1854-1864.
- Steg PG, James SK, Atar D, et al (2012). ESC Guidelines for the management of acute myocardial infarction in patients presenting with ST-segment elevation.: Task Force on the management of ST-segment elevation acute myocardial infarction of the European Society of Cardiology (ESC). *Eur Heart J* 33:2569-2619.
- Steg PG, James S, Harrington RA, et al (2010). Ticagrelor versus clopidogrel in patients with ST elevation acute coronary syndromes intended for

- reperfusion with primary percutaneous coronary intervention: a platelet inhibition and patient outcomes (PLATO) trial subgroup analysis. *Circulation* 122:2131-2141.
- Steg PG, Mehta SR, Jukema JW, et al (2011). RUBY-1: a randomized, double blind, placebo-controlled trial of the safety and tolerability of the novel oral factor Xa inhibitor darexaban (YM 150) following acute coronary syndrome. *Eur Heart J* 32:2541-2554.
- Steg PG, van'tHof A, Hamm CW, et al (2013). Bivalirudin Started during Emergency Transport for Primary PCI. *New Engl J Med* 369:2207-2217.
- Steinmann SG (1996). Metal implants and surface reactions. *Injury* 27(3 suppl):16SC-22SC.
- Steinmann SG (1998). Titanium: the material of choice? *Periodontol* 2000. 17:7-21.
- Stone GW, Abizaid A, Silber S, et al (2012). Prospective, Randomized, Multicenter Evaluation of a Polyethylene Terephthalate Micronet Mesh-Covered Stent (MGuard) in ST-Segment Elevation Myocardial Infarction: The MASTER trial. *J Am Coll Cardiol* 60:1975-1984.
- Stone GW, Ellis SG, Cannon L, et al (2005). Comparison of a polymer-based paclitaxel-eluting stent with a bare metal stent in patients with complex coronary artery disease: a randomized controlled trial. *JAMA* 294:1215-1223.
- Stone GW, Ellis SG, Cox DA, et al (2004a). A polymer-based, paclitaxel-eluting stent in patients with coronary artery diseases. *New Engl J Med* 350:221-231.
- Stone GW, Ellis S, Cox DA et al (2004b). One-year clinical results with the slow-release, polymer-based, paclitaxel-eluting TAXUS stent: the TAXUS-IV trial. *Circulation* 109:1942-1947.
- Stone GW, McLaurin BT, Cox DA, et al (2006). Bivalirudin for patients with acute coronary syndromes. *N Eng J Med* 355:2203-2216.
- Stone GW, Moses JW, Ellis SG, et al (2007). Safety and efficacy of sirolimus- and paclitaxel-eluting coronary stents. *N Eng J Med* 356:998-1008.
- Stone GW, Teirstein PS, Meredith IT, et al (2011). A prospective, randomized evaluation of a novel everolimus-eluting coronary stents. The PLATINUM (a Prospective, Randomized, Multicenter Trial to Assess an Everolimus-Eluting Coronary Stent System [PROMUS Element] for the Treatment of Up to Two de Novo Coronary Artery Lesions) trial. *J Am Coll Cardiol* 57:1700-1708.
- Stone GW, Witzenbichler B, Guagliumi G, et al (2011). Heparin plus a glycoprotein IIb/IIIa inhibitor versus bivalirudin monotherapy and paclitaxel-eluting stents versus bare-metal stents in acute myocardial infarction (HORIZONS-AMI): final 3-year results from a multicentre, randomised controlled trial. *Lancet* 377:2193-2204.
- Subherwal S, Bach RG, Chen AY, et al (2009). Baseline risk of major bleeding in non-ST-segment elevation myocardial infarction: the CRUSADE (Can Rapid risk stratification of Unstable angina patients Suppress Adverse outcomes with Early implementation of the ACC/AHA Guidelines) Bleeding Score. *Circulation* 119:1873-1882.
- Sudhir K, Hermiller JB, Ferguson JM, et al (2013). Risk factors for coronary drug-eluting stent thrombosis: influence of procedural, patient, lesion and stent related factors and dual antiplatelet therapy. *ISRN Cardiol* 2013:748736.
- Sutton JM, Ellis SG, Roubin GS, et al (1994). Major clinical events after coronary stenting. The multicenter registry of acute and elective gianturcoroubin stent placement. *Circulation* 89:1126-1137.
- Sørensen R, Hansen ML, Abildstrom SZ, et al (2009). Risk of bleeding in patients with acute myocardial infarction treated with different combinations of aspirin, clopidogrel, and vitamin K antagonists in Denmark: a retrospective analysis of nationwide registry data. *Lancet* 374:1967-1974.
- Takano M, Murakami D, Yamamoto M, et al (2013). Six month follow-up evaluation for everolimus-eluting stents by intracoronary optical coherence tomography: comparison with paclitaxel-eluting stents. *Int J Cardiol* 166:181-186.
- Takano M, Yamamoto M, Inami S, et al (2009). Appearance of lipid-laden intima and neovascularization after implantation of bare-metal stents extended late-phase observation by intracoronary optical coherence tomography. *J Am Coll Cardiol* 55:26-32.
- Tanabe K, Serruys PW, Grube E, et al (2003). TAXUS III Trial: In-stent restenosis treated with stent-based delivery of paclitaxel incorporated in a slow-release polymer formulation. *Circulation* 107:559-564.
- Tanguay J, Zidar J, Phillips H, et al (1994). Current status of biodegradable stents. *Cardiol Clin* 12:699-713.
- Tanigawa J, Dimopoulos K, Di Mario, et al (2008). Optical coherence tomography to assess malapposition in overlapping drug-eluting stents. *Eurointerv* 3:580-583.
- Taubert D, Kastrati A, Harlfinger S, et al (2004). Pharmacokinetics of clopidogrel after administration of a high loading dose. *Thromb Haemost* 92:311-316.
- Tavris DR, Wang Y, Jacobs S, et al (2012). Bleeding and vascular complications at the femoral access site following percutaneous coronary intervention (PCI): an evaluation of hemostasis strategies. *J Invasive Cardiol* 24:328-34.

- Tearney GJ, Yabushita H, Houser SL, et al (2003). Quantification of macrophage content in atherosclerotic plaques by optical coherence tomography. *Circulation* 107:113-119.
- Thompson KA, Philip KJ, Schwarz ER (2011). Clinical applications of bivalirudin in the cardiac catheterization laboratory. *J Cardiovasc Pharmacol Ther* 16:140-149.
- Thompson PL, Verheugt FW (2014). Managing Antithrombotic Therapy in patients With Both Atrial Fibrillation and Coronary Heart Disease. *Clin Ther* 36:1176-1181.
- Toledano Delgado FJ, Alvarez-Ossorio MP, de Lezo Cruz-Conde JS, et al (2013). Optical coherence tomography evaluation of late strut coverage patterns between first-generation drug-eluting stents and everolimus-eluting stent. *Catheter Cardiovasc Interv* epub ahead of print.
- Toutouzas K, Colombo A, Stefanadis C (2004). Inflammation and restenosis after percutaneous coronary interventions. *Eur Heart J* 25:1679-1687.
- Tricoci P, Huang Z, Held C, et al (2012). Thrombin-receptor antagonist vorapaxar in acute coronary syndromes. *N Eng J Med* 366:20-33.
- Tricoci P, Newby LK, Hasselblad V, et al (2011). Upstream use of small-molecule glycoprotein iib/iiia inhibitors in patients with non-ST-segment elevation acute coronary syndromes: a systematic overview of randomized clinical trials. *Circ Cardiovasc Qual Outcomes* 4:448-458.
- Tsyganov IA, Maitz MF, Richter E, et al (2007). Hemocompatibility of titanium-based coatings prepared by metal plasma immersion ion implantation and deposition. *Nucl Instrum Methods Phys Res B* 257:122-127.
- Tsyganov I, Maitz MF, Wieser E, et al (2005). Correlation between blood compatibility and physical surface properties of titanium-based coatings. *Surface and Coating Tehnology* 200:1041-1044.
- Tuomainen O, Ylitalo A, Niemelä M, et al (2012). Five-year clinical outcome of titanium-nitride-oxide-coated bioactive stents versus paclitaxel-eluting stents in patients with acute myocardial infarction: long-term follow-up from the TITAX AMI trial. *Int J Cardiol* 168:1214-1219.
- Turak O, Canpolat U, Özcan F, et al (2014). Usefulness of preprocedural serum uric acid level to predict restenosis of bare metal stents. *Am J Cardiol* 113:197-202.
- Valdés Chavarri M, Bethencourt A, Pinar E, et al (2012). Titanium-nitride-oxide-coated stents multicenter registry in diaBETic patienTs: The TIBET registry. *Heart Vessels* 2:151-158.
- Valdesuso R, Karjalainen P, Garcia J, et al (2010). The EXTREME registry: titanium-nitride-oxide coated stents in small coronary arteries. *Catheter Cardiovasc Interv* 76:281-287.
- Valgimigli M, Biondi-Zoccai G, Tebaldi M, et al (2010). Tirofiban as adjunctive therapy for acute coronary syndromes and percutaneous coronary intervention: a meta-analysis of randomised trials. *Eur Heart J* 31:35-49.
- Van der Giessen WJ, Lincoff AM, Schwartz RS, et al (1996). Marked inflammatory sequelae to implantation of biodegradable and nonbiodegradable polymers in porcine coronary arteries. *Circulation* 94:1690-1697.
- van Geuns RJ, Tanburino C, Fajadet J, et al (2012). Self-expanding versus balloon-expandable stents in acute myocardial infarction: results from the APPOSITION II study; self-expanding stents in ST-segment elevation myocardial infarction. *JACC Cardiovasc Interv* 5:1209-19.
- van Verkum JW, Heestermans AA, Zomer AC, et al (2009). Predictors of coronary stent thrombosis: the Dutch Stent Thrombolysis Registry. *J Am Coll Cardiol* 53:1399-1409.
- Verhey S, Ramcharitar S, Grube E, et al (2011). Six-month clinical and angiographic results of the STENTYS® self-apposing stent in bifurcation lesions. *Eurointerv* 7:580-587.
- Vink MA, Dirksen MT, Suttorp MJ, et al (2011). 5-year follow-up after primary percutaneous coronary intervention with paclitaxel-eluting stent versus a bare-metal stent in acute ST-segment elevation myocardial infarction. *J Am Coll Cardiol* 4:24-29.
- Virmani R, Guagliumi G, Farb A, et al (2004). Localized hypersensitivity and late coronary thrombosis secondary to a sirolimus-eluting stent: Should we be cautious? *Circulation* 109:701-705.
- Vlaar PJ, Svilaas T, van der Horst IC, et al (2008). Cardiac death and reinfarction after 1 year in the Thrombus Aspiration during Percutaneous coronary intervention in Acute myocardial infarction Study (TAPAS): a 1-year follow-up study. *Lancet* 371:1915-1920.
- vom Dahl J, Dietz U, Haager PK, et al (2002). Rotational atherectomy does not reduce recurrent in-stent restenosis: results of the angioplasty versus rotational atherectomy for treatment of diffuse in-stent restenosis trial (ARTIST). *Circulation* 105:583-588.
- Wallentin L, Becker RC, Budaj A, et al (2009). Ticagrelor versus clopidogrel in patients with acute coronary syndromes. *N Eng J Med* 361:1045-1057.
- Wallentin L, Wilcox RG, Weaver WD, et al (2003). Oral ximelagatran for secondary prophylaxis after

- myocardial infarction: the ESTEEM randomised controlled trial. *Lancet* 362:789-797.
- Welsh RC, Rao SV, Zeymer U, et al (2012). A randomized, double-blind, active-controlled phase 2 trial to evaluate a novel selective and reversible intravenous and oral P2Y12 inhibitor elinogrel versus clopidogrel in patients undergoing nonurgent percutaneous coronary intervention: the INNOVATE-PCI trial. *Circ Cardiovasc Interv* 5:336-346.
- Wenaweser P, Daemen J, Zwahlen M, et al (2008). Incidence and correlates of drug-eluting stent thrombosis in routine clinical practice. 4-year results from a large 2-institutional cohort study. *J Am Coll Cardiol* 52:1134-1140.
- Wijns W, Kohl P, Danchin N, et al (2010). Guidelines on myocardial revascularization. *Eur Heart J* 31:2501-2555.
- Windecker S, Billinger M, Hess OM (2006). Stent coating with titanium-nitride-oxide for prevention of restenosis. *Eurointerv* 2:146-148.
- Windecker S, Kohl P, Alfonso F, et al (2014). 2014 ESC/EACTS Guidelines on myocardial revascularization: The Task Force on Myocardial Revascularization of the European Society of Cardiology (ESC) and the European Association for Cardio-Thoracic Surgery (EACTS) Developed with the special contribution of the European Association of Percutaneous Cardiovascular Interventions (EAPCI). *Eur Heart J* 35:2541-2619.
- Windecker S, Mayer I, De Pasquale G, et al (2001). Stent coating with titanium-nitride-oxide for reduction of neointimal hyperplasia. *Circulation* 104:928-933.
- Wiviott SD, Braunwald E, Angiolillo DJ, et al (2008). Greater clinical benefit of more intensive oral antiplatelet therapy with prasugrel in patients with diabetes mellitus in the trial to assess improvement in therapeutic outcomes by optimizing platelet inhibition with prasugrel-thrombolysis in myocardial infarction 38. *Circulation* 118:1626-1636.
- Wiviott SD, Braunwald E, McCabe CH, et al (2007). Prasugrel versus clopidogrel in patients with acute coronary syndromes. *N Eng J Med* 357:2001-2015.
- Won KB, Lee SH, Chang HJ, et al (2014). Safety and cost-effectiveness of bridge therapies for invasive dental procedures in patients with mechanical heart valves. *Yonsei Med J* 55:937-943.
- Wykrzykowska J, Serruys P, Buszman P, et al (2011). The three year follow-up of the randomized "all-comers" trial of a biodegradable polymer biolimus-eluting stent versus permanent polymer sirolimus-eluting stent (LEADERS). *Eurointerv* 7:789-795.
- Zartner P, Cesnjevar R, Singer H, et al (2005). First successful implantation of biodegradable metal stent into the left pulmonary artery of a preterm baby. *Catheter Cardiovasc Interv* 66:590-594.
- Zhang F, Chen Y, Zheng Z et al (1998). Synthesis and blood compatibility of rutile-type titanium oxide coated LTI-carbon. *China C Life Sci* 41(4):400-405.
- Zheng F, Zheng Z, Chen Y, et al (1998). In vivo investigation of blood compatibility of titanium oxide films. *J Biomed Mater Res* 42(1):128-133.