

**Aleksi Vihanto**

**The Learning Curve and Pitfalls of Arthroscopic Four-Corner Arthrodesis**

**Syventävien opintojen kirjallinen työ**

**Kevätlukukausi 2019**

**Aleksi Vihanto**

**The Learning Curve and Pitfalls of Arthroscopic Four-Corner Arthrodesis**

**Klininen laitos, käsikirurgia**

**Kevätlukukausi 2019**

**Vastuuohjaaja: Hannu Aro**

**Lähiohjaaja: Markus Pääkkönen**

*The originality of this thesis has been checked in accordance with the University of Turku quality assurance system using the Turnitin OriginalityCheck service.*

TURUN YLIOPISTO  
Kliininen laitos

VIHANTO, ALEKSI: Learning Curve and Pitfalls of Arthroscopic Four-Corner Arthrodeses

Syventävien opintojen kirjallinen työ, 13s., 5 liites.  
Käsikirurgia  
Tammikuu 2019

---

Midcarpal “four-corner” wrist arthrodesis is a motion-sparing salvage procedure mainly employed for painful wrist osteoarthritis. In the procedure the scaphoideum is resected along with midcarpal joint surfaces after which lunatum, triquetrum, capitate and hamate are fused together. Unlike total wrist fusion, the operated wrist maintains around 50% of its movement compared to the contralateral wrist. Currently the procedure may be done from an open arthrotomy or arthroscopically.

This study aimed to examine the results of the recently described arthroscopic four-corner arthrodesis and whether the procedure seems to have any merit compared to the open technique. Eight patients were retrospectively identified with nine cases of arthroscopic four-corner arthrodesis performed at Turku University Hospital 2014-2017.

Operating time for the first surgery was 198 minutes while the final one lasted 132 minutes. All patients achieved fusion. Three patients required a reoperation: one for screw malposition with screw removal, one for tendon reconstruction and screw removal due to a tendon injury induced by a retracted screw and one for scaphoid impingement with removal of the scaphoid remnants. One patient experienced a probable superficial radial nerve injury.

The arthroscopic approach is technically extremely demanding and has a learning curve. Thorough resection of the scaphoid and careful placement of screws is recommended to avoid potential complications.

Key words: Four-corner arthrodesis, Wrist arthroscopy, midcarpal joint, SLAC

## **Abstract**

**Background** Midcarpal “four-corner” wrist arthrodesis may be done from an open arthrotomy or arthroscopically.

**Purpose** This study aimed to examine the results of the recently described arthroscopic four-corner arthrodesis and whether the procedure seems to have any merit compared to the open technique

**Patients and Methods** We retrospectively identified eight patients with nine cases of arthroscopic four-corner arthrodesis performed at our institution 2014-2017. The underlying pathologies were scapholunate advanced collapse (N 6), Preiser disease (N 1), radioscaphoid (N 1) or capitolar (N 1) osteoarthritis. Osteosynthesis was done with cannulated compression screws.

**Results** Operating time for the first surgery was 198 minutes while the final one lasted 132 minutes. All patients achieved fusion. Three patients required a reoperation: one for screw malposition with screw removal, one for tendon reconstruction and screw removal due to a tendon injury induced by a retracted screw and one for scaphoid impingement with removal of the scaphoid remnants. One patient experienced a probable superficial radial nerve injury. The follow-up time was 5-16 months.

**Conclusion** The arthroscopic approach is technically extremely demanding and has a learning curve. Thorough resection of the scaphoid is recommended to avoid potential impingement.

**Level of Evidence:** IV (Retrospective case-series)

### **Key words**

Four-corner arthrodesis, Wrist arthroscopy, midcarpal joint, SLAC

## INTRODUCTION

Midcarpal arthrodesis or “Four-corner arthrodesis” (4CA) is a motion-sparing salvage procedure mainly employed for grade II and III stages of scapholunate advanced collapse (SLAC) and scaphoid nonunion advanced collapse (SNAC). [1] [2] [3] [4] [5] The operation has been comprehensively shown to reduce pain, improve grip strength and maintain a useful range of motion (ROM) for up to ten years. [6] [7] [8] [9] [10] [11] [12] [13] [14]

Literature presents numerous techniques utilizing various approaches, types of fixation, use and source of bone graft and combinations of carpal bones fused. [15] [16] [17] [18] [19] [20] [21] [22] The optimal surgical technique is still open for debate. Traditionally 4CA has been done with a ligament sparing dorsal wrist approach introduced by Berger et al. [13] [23] This requires extensive soft tissue dissection which injures the capsule and ligament structures and may lead to postoperative pain, slow rehabilitation, scarring and decreased range of motion.

Typically 50% of the extension-flexion arc, 40% of radioulnar deviation and 50-75% of grip strength is retained following an open 4CA when compared to the contralateral wrist. [22] [24] [25] Complication rates vary between 9-29% with nonunion and hardware problems being the most common. [2] [20] [25] Non-union rates specifically seem to vary greatly from 3% to 31% with some patients remaining asymptomatic. [6] [25] [26] The majority of the complications and resurgeries appear to take place within 2 years of the initial surgery after which the results seem to be long-lasting with little deterioration. [8] [25]

The arthroscopic approaches described by Ho and del Piñal aim to minimize the surgical trauma to the blood supply and structures vital for proprioception and stability such as the dorsal radiocarpal ligament and dorsal intercarpal ligament. [27] [28] [29] [30] Also, the cosmetic result is favorable and unobstructed view of most of the joint structures enable accurate diagnostics and choice of optimal treatment strategy. Disadvantages would be the limited options of fixation, namely K-wires

or cannulated screws, and the technical difficulty of the operation which can initially lead to long operating times. [27] [28]

So far little research has been published about the functional outcomes of A-4CA. del Piñal reported 4 cases of A-4CA with slightly improved range of motion and markedly improved grip strength. [28] Ho published 12 arthroscopic partial wrist arthrodeses (A-PWA) with an 8% revision rate (1/12), 33% total complication rate and an average time to radiological union of 11.7 weeks (range, 5-20 wk). [27] Baur reported 39 A-PWAs with a revision rate of 8/39 (21%) of which 4 were due to nonunion (10%). Complications included 2 screw-related problems and 1 case of neoscaphoid formed from bone graft. [31] To our knowledge no study has examined the long-term results of A-4CA. Ho averaged a follow-up period of 70 months after which little to no wrist pain was reported. [27]

We report 9 cases of arthroscopic 4CA with the purpose of investigating the progression in operating times, postoperative results and complication prevalence and comparing these to the pertinent literature on the open technique.

## **PATIENTS AND METHODS**

Permission to obtain the electronic records of the patients at Turku University Hospital was obtained from the hospital management through the Turku Clinical Research center. We identified eight patients with nine cases of wrist osteoarthritis and subsequent arthroscopic four-corner arthrodesis (A-4CA) conducted during 2014-2017 by a single surgeon with a level 3 expertise. [32] There were seven males and one female with a median age of 54 (range 42-59). All patients underwent conservative treatment including splints, NSAIDs and rest before proceeding to surgical treatment. All patients had severe arthritic changes in wrist radiographs, and had clinical symptoms of wrist osteoarthritis. Panarthrosis of the wrist, ulnar translation and radiolunate arthrosis were ruled out in all patients. Five patients had manual labor jobs, one was in a service profession, one was retired and one was unemployed.

We operated six wrists for SLAC-wrist pathology, one for Preiser disease, one for capitular arthrosis and one for grave radioscaphoidal arthrosis without scapholunate dissociation. Two patients were active smokers at the time of the surgery. We identified no clinically relevant comorbidities.

We extracted data manually on specific sheets, including surgery duration, pre- and postoperative wrist mobility and grip strength, complications, reoperations, bony union progression and total follow-up time. Overall satisfaction was determined by the patient's own subjective opinion at the last clinical control (yes/no). Grip strength was measured with Jamar dynamometer (Jamar, Preston, MI). Dorsal intercalated segment instability (DISI) was measured pre- and postoperatively by two hand surgeons independently and the mean value was reported [Table 1]. No systematic data collection was employed.

### **Technique**

A sterile tourniquet and wrist tower for traction are installed. Arthroscopic portals 3-4, 6R, midcarpal radial and ulnar are created [Fig 1]. The procedure begins with standard wrist arthroscopy. Under continuous irrigation, a soft tissue shaver is used to create visibility. The scaphoid and the articular surfaces of the midcarpal joint are removed with 3.5 and 4.0 mm burrs [Fig 2]. When deemed necessary, a cancellous bone graft is harvested either from the iliac crest or the scaphoid. A trocar is used to insert the bone graft into the midcarpal joint. The lunate is aligned and temporarily fixed to the radius and the midcarpal joint is reduced. Bone alignment is secured with two to three 2.2 or 3.0 mm SpeedTip® cannulated compression screws (Medartis, Basel, Switzerland) percutaneously under fluoroscopic visualization. The wounds are closed with 5-0 nylon sutures. A bandage and a volar plaster of Paris is installed to hold the wrist in 30-40 degrees of extension. The tourniquet is released after 2 hours, or at the end of the operation.

## **Post-operative care and follow-up**

The patients are advised to keep the operated hand elevated. Hand exercises are started on the first post-operative day. A hand therapist meets the patients two weeks from surgery to replace the cast with a volar splint. The wrist is immobilized for 6 weeks after which the patients are instructed to perform light wrist exercises two to three times a day and scar massaging is encouraged.

Follow-up visits with a physician's assessment are routinely scheduled at approximately 6 weeks, 14 weeks and at 6 months post-operatively with X-rays to assess bony union. The arthrodesis is considered fused when convincing signs of capito-lunate union on frontal and lateral plain X-rays are seen and there is an absence of local tenderness at the fusion site. A CT scan is obtained on demand (before any reoperation). Wrist mobility and grip strength are measured at each follow-up visit. Additional follow-ups are arranged on demand.

## **RESULTS**

A summary of the patient demographics and post-operative results can be found in Table 1. One patient went on to have bilateral A-4CA in a time span of one year. One patient's follow-up took place at another hospital.

The longest operating time was 3 hours 18 minutes in the first surgery while the quickest surgery lasted 2 hours 7 minutes in the 6<sup>th</sup> surgery. The mean operating time was 2 hours 32 minutes ( $\pm$  SEM 7) [Fig 3].

Mean follow-up time was 10 months (range: 5-16 months). None of the patients experienced nonunion. The average time to radiological union was 4.9 months (range 1.5-8 months). A summary of follow-up and bony union progression details can be found in [Table 2].

Three major complications occurred. One patient had a capitolar screw protruding into the intra-articular space that was removed 10 months after the primary operation. One patient experienced a



rupture of both index finger extensors due to a retracted, prominent capitolar screw and underwent screw removal and tendon reconstruction with a palmaris longus graft 5 months after the primary operation. One patient experienced a probable nerve injury to superficial radial nerve branch at the site of percutaneous screw insertion resulting in loss of sensation at the dorsal skin over metacarpals II and III and considerable neuropathic pain on the back of the hand. Additionally one asymptomatic patient was found to have a triquetrolunar screw piercing the dorsal cortex of the lunate.

One patient reported prolonged wrist pain which was interpreted to be caused by a distal a piece of scaphoid bone still present after the primary surgery and underwent scaphoid remnant removal 13 months later [Fig 4a and 4b] which had alleviated symptoms at 2 months postoperatively. CT scans were obtained preoperatively from all three patients requiring resurgery to confirm fusion.

All of the patients had shallow shell-like remnants of the scaphoid visible on follow-up X-rays [Fig 5]. None of the patients reported noteworthy bone donor site morbidity at the iliac crest. On four occasions patients reported postoperative ulno-carpal pain.

At the end of the follow-up period the wrist joint ROM (mean  $\pm$  standard error of mean, SEM) was 64% ( $\pm$  8.66) and the grip strength was 76% ( $\pm$  6.41) compared with the contralateral upper limb. The mean DISI-angle postoperatively was -3 degrees (volarly tilted) ( $\pm$ 3.21) while the preoperative mean was 10 degrees ( $\pm$  6.89). Overall patient satisfaction was good in four out of eight wrists that completed follow-up. Two were dissatisfied and two indecisive. One could not be reached.

## **DISCUSSION**

We set out to examine whether the theoretical advantages of the arthroscopic approach, namely minimal surgical insult and accurate visualization of the joint surfaces, carried any merit.

Furthermore we were interested in the development of the surgical expertise by following the progression in operating times and complication prevalence.

The retrospective nature and the low number of patients that were operated on by a single surgeon are the main limitations of this study. Furthermore, we did not employ a systematic data collection and as such could not acquire standardized functional scores. Our mean routine follow-up period was relatively short. Future larger and randomized studies are still needed to establish the efficacy of the arthroscopic approach for 4CAs.

Operation time is a straightforward parameter to track the progress of a surgeon's expertise in a given procedure. In our series the learning curve was steep as the first surgery lasted 3 hours and 18 minutes while the mean of the last four surgeries was 2 hours 16 minutes. The plateau in operating times appears to be achieved after five surgeries [Fig 3]. del Piñal et al. managed to reduce the operating time from 4 hours to under 2 hours in four surgeries after several aborted attempts. [28] Ho's mean operating time was 3 hours 5 minutes for 12 arthroscopic partial wrist arthrodesis (three scaphotrapeziotrapezoid-fusions, four 4CAs, three radioscapolunate fusions, one radiolunate fusion and one lunotriquetral fusion). [27] In our series the decrease in the operation time was probably due to the surgeon getting more used to the changing environment and more determined in the resection of the scaphoid and the articular surfaces of the midcarpal joint especially with the bigger 4.0 mm burr.

All of the complications in our series were related to the percutaneous screw placement and not the arthroscopic removal of the scaphoid or the articular surfaces per se. During the first procedures of the series we encountered one case of incorrect screw placement and one case of screw migration. In the literature 3-8% of patients end up requiring screw removal due to either screw migration or malposition. [15] [20] [33] [34] The correct placement of the capitollunate screw deep in the capitatum has been stressed and should be aspired to in order to avoid extensor tendon injuries. [27] It is evident that in the first procedures the surgeons focus is in the arthroscopic technique. Our preference is to use continuous irrigation, but we aim to restrict the saline flow to as low as possible to avoid unnecessary tissue swelling.

One patient underwent additional surgery for scaphoid remnant removal. We are not aware what the prevalence of resurgery for scaphoid remnant removal is following a 4CA as this complication is rarely reported. Scaphoid articulates with the radial styloid and a remnant can potentially cause impingement. In open procedures dorsal impingement between the capitate and radius is among the most common complications following a 4CA with a 4.4% prevalence. [13] It has also been suggested that the distal part of the scaphoid can be left in place to preserve the scaphotrapezial ligament without impingement issues. [27] Our patient had radial wrist pain consistent with impingement leading us to opt for scaphoid removal. We strive for a meticulous resection of the scaphoid yet even after a thorough removal, an eggshell like fragment of the scaphoid usually remains. We believe this is unlikely to cause symptoms. Another possibility is to perform an open scaphoidectomy from a volar incision. We did not utilize this technique which has the disadvantage of an additional incision but would have most likely shortened the operative time and might have reduced the risk of a significant scaphoideum remnant.

Altogether three out of eight wrists (37.5%) required a reoperation in comparison to 0-44% reported in open surgeries [1] [22] [33] [35] [36] [37] [38] and 8-20% reported in earlier A-PWAs. [27][31] Our overall patient satisfaction compares decently with the prevalences of 60-100% that have been cited. [1] [11] [14] [22] Both of the dissatisfied patients underwent a reoperation, one for ruptured tendon reconstruction and one for scaphoid remnant removal. Additionally they were among the first four to be operated on where most of the complications were observed. It is probable that as the surgeon's experience increases the prevalence of complications diminish which in turn could result in a higher patient satisfaction.

Arthroscopic technique provides better cosmetic results with smaller scars, but it is yet unclear whether arthroscopic 4-CA results in better wrist function due to lack of research. Our means of 64% ROM and 76% grip strength are in line or slightly better with reported open technique results. [25] The mean time of radiological union in our series was 4.9 months (range 1,5-8 months). This is

above Ho's and Cha's mean findings of 11.7 and 9 weeks for A-PWAs and open surgeries, respectively. [8] [27] On the other hand, we did not observe any nonunions.

We acknowledge the relatively high revision rate and initially long operating times in our series. In the final five surgeries, however, no resurgeries were needed while the mean operating time closed in on 2 hours. In these final surgeries the only complication was a nerve injury that was, again, unrelated to the arthroscopic technique itself.

Four-corner arthrodesis can be added to the growing list of pathologies that can be treated arthroscopically. [28] The technique is however most demanding and has a learning curve but allows for minimal surgical insult. We wish to emphasize that this is a very specialized procedure that should be done in only few specialist centers that have overcome their learning curve. In our experience the adequate removal of the scaphoid and the correct positioning of the fixation material should be stressed. The duration of surgery and complications are expected to diminish as experience increases.

Conflict of Interest

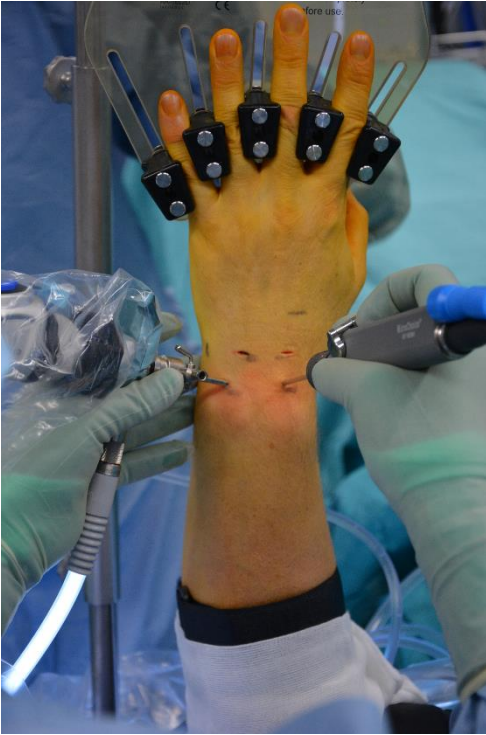None.

## References

- 1** Dacho AK, Baumeister S, Germann G, Sauerbier M. Comparison of proximal row carpectomy and midcarpal arthrodesis for the treatment of scaphoid nonunion advanced collapse (SNAC-wrist) and scapholunate advanced collapse (SLAC-wrist) in stage II. *J Plast Reconstr Aesthet Surg* 2008; 61:1210-1218
- 2** Saltzman BM, Frank JM, Slikker W, Fernandez JJ, Cohen MS, Wysocki RW. Clinical outcomes of proximal row carpectomy versus four-corner arthrodesis for post-traumatic wrist arthropathy: a systematic review. *J Hand Surg Eur Vol* 2015; 40:450-457
- 3** Vender MI, Watson HK, Wiener BD, Black DM. Degenerative change in symptomatic scaphoid nonunion. *J Hand Surg Am* 1987; 12:514-519
- 4** Watson HK, Ballet FL. The SLAC wrist: scapholunate advanced collapse pattern of degenerative arthritis. *J Hand Surg Am* 1984;9:358-365
- 5** Watson HK, Ryu J. Evolution of arthritis of the wrist. *Clin Orthop Relat Res* 1986;57-67
- 6** Ashmead D, Watson HK, Damon C, Herber S, Paly W. Scapholunate advanced collapse wrist salvage. *J Hand Surg Am* 1994; 19:741-750
- 7** Bain GI, Watts AC. The outcome of scaphoid excision and four-corner arthrodesis for advanced carpal collapse at a minimum of ten years. *J Hand Surg Am* 2010; 35:719-725
- 8** Cha SM, Shin HD, Kim KC. Clinical and radiological outcomes of scaphoidectomy and 4-corner fusion in scapholunate advanced collapse at 5 and 10 years. *Ann Plast Surg* 2013; 71:166-169
- 9** Cohen MS, Kozin SH. Degenerative arthritis of the wrist: proximal row carpectomy versus scaphoid excision and four-corner arthrodesis. *J Hand Surg Am* 2001; 26:94-104
- 10** Krakauer JD, Bishop AT, Cooney WP. Surgical treatment of scapholunate advanced collapse. *J Hand Surg Am* 1994; 19:751-759
- 11** Mavrogenis AF, Flevas DA, Raptis K et al. Four-corner fusion of the wrist: clinical and radiographic outcome of 31 patients. *Eur J Orthop Surg Traumatol* 2016; 26:859-866
- 12** Mulford JS, Ceulemans LJ, Nam D, Axelrod TS. Proximal row carpectomy vs four corner fusion for scapholunate (Slac) or scaphoid nonunion advanced collapse (Snac) wrists: a systematic review of outcomes. *J Hand Surg Eur Vol* 2009; 34:256-263
- 13** Shin AY. Four-corner arthrodesis. *J Am Soc Surg Hand* 2001;1:93-111
- 14** Watson HK, Weinzwei J, Guidera PM, Zeppieri J, Ashmead D. One thousand intercarpal arthrodeses. *J Hand Surg Br* 1999; 24:307-315
- 15** Dutly-Guinand M, von Schroeder HP. Three-corner midcarpal arthrodesis and scaphoidectomy: a simplified volar approach. *Tech Hand Up Extrem Surg* 2009; 13:54-58
- 16** Espinoza DP, Schertenleib P. Four-corner bone arthrodesis with dorsal rectangular plate: series and personal technique. *J Hand Surg Eur Vol* 2009; 34:609-613

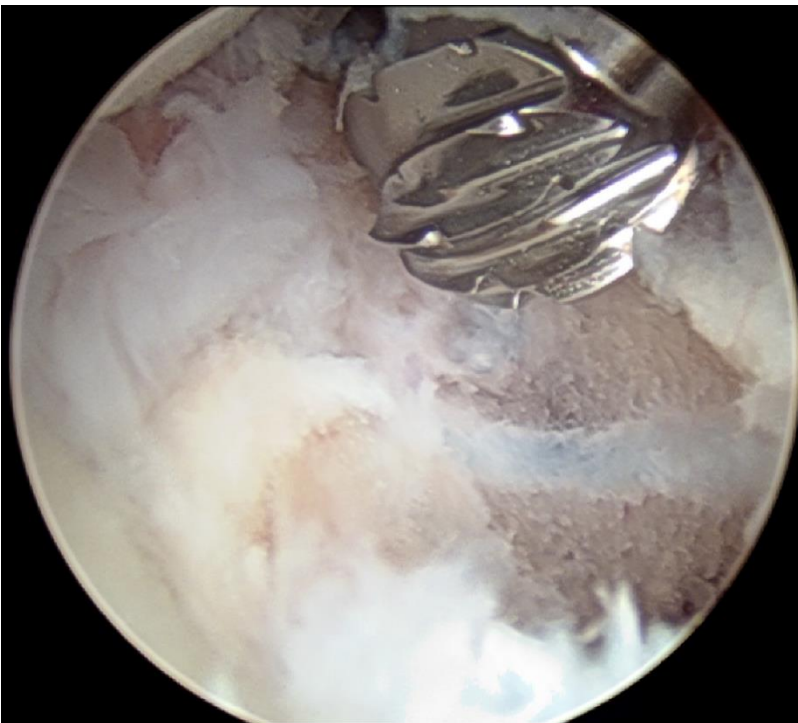
- 17** Gaston RG, Greenberg JA, Baltera RM, Mih A, Hastings H. Clinical outcomes of scaphoid and triquetral excision with capitulunate arthrodesis versus scaphoid excision and four-corner arthrodesis. *J Hand Surg Am* 2009; 34:1407-1412
- 18** Kitzinger HB, Karle B, Prommersberger KJ, van Schoonhoven J, Frey M. Four-corner arthrodesis - does the source of bone graft affect bony union rate? Iliac crest versus distal radius bone graft. *J Plast Reconstr Aesthet Surg* 2012; 65:379-383
- 19** Korus LJ, Ball B, Morhart M. Exclusion of the hamate in 4-corner fusion: technique and outcomes of a novel approach to intercarpal arthrodesis. *Tech Hand Up Extrem Surg* 2013; 17:102-105
- 20** Ozyurekoglu T, Turker T. Results of a Method of 4-Corner Arthrodesis Using Headless Compression Screws. *J Hand Surg Am* 2012; 37:486-492
- 21** Tielemans A, Van Innis F, Troussel S, Detrembleur C, Libouton X, Lequint T. Effect of four-corner fusion with locking plate without bone graft on functional recovery of the wrist: New treatment guidelines. *Hand Surg Rehabil.* 2017; 36:186-191
- 22** Vance MC, Hernandez JD, Didonna ML, Stern PJ. Complications and outcome of four-corner arthrodesis: circular plate fixation versus traditional techniques. *J Hand Surg Am* 2005; 30:1122-1127
- 23** Berger RA, Bishop AT, Bettinger PC. New dorsal capsulotomy for the surgical exposure of the wrist. *Ann Plast Surg* 1995; 35:54-59
- 24** Kendall CB, Brown TR, Millon SJ, Rudisill LE Jr, Sanders JL, Tanner SL. Results of four-corner arthrodesis using dorsal circular plate fixation. *J Hand Surg* 2005; 30:903-907
- 25** Trail IA, Murali R, Stanley JK et al. The long-term outcome of four-corner fusion. *J Wrist Surg* 2015; 4:128-133
- 26** Neubrech F, Mühldorfer-Fodor M, Pillukat T, Schoonhoven JV, Prommersberger KJ. Long-term results after midcarpal arthrodesis. *J wrist Surg* 2012; 1:123-128
- 27** Ho PC. Arthroscopic partial wrist fusion. *Tech Hand Up Extrem Surg* 2008; 12:242-265
- 28** del Piñal F, Klausmeyer M, Thams C, Moraleda E, Galindo C. Early experience with (dry) arthroscopic 4-corner arthrodesis: from a 4-hour operation to a tourniquet time. *J Hand Surg Am* 2012; 37:2389-2399
- 29** del Piñal F, García-Bernal FJ, Pisani D, Regalado J, Ayala H, Studer A. Dry arthroscopy of the wrist: surgical technique. *J Hand Surg Am* 2007; 32:119-123
- 30** Hagert E, Garcia-Elias M, Forsgren S, Ljung BO. Immunohistochemical analysis of wrist ligament innervation in relation to their structural composition. *J Hand Surg Am* 2007; 32:30-36
- 31** Baur EM. Arthroscopic-assisted partial wrist arthrodesis. *Hand Clin* 2017; 33:735-753
- 32** Tang JB. Levels of experience of surgeons in clinical studies. *J Hand Surg Eur Vol* 2009; 34:137-138
- 33** Lordache SD, Nam D, Paylan J, Axelord T. Four-corner arthrodesis using two headless compression screws. *Acta Orthop Belg* 2016; 82:332-338

- 34** Richards AA, Afifi AM, Moneim MS. Four-corner fusion and scaphoid excision using headless compression screws for SLAC and SNAC wrist deformities. *Tech Hand Up Extrem Surg* 2011; 15:99-103
- 35** Hernekamp JF, Reinecke A, Neubrech F, Bickert B, Kneser U, Kremer T. Four-corner fusion: comparison of patient satisfaction and functional outcome of conventional K-wire technique vs. a new locking plate. *Arch Orthop Trauma Surg* 2016; 136:571-578
- 36** Koehler SM, Melon CP. Four-corner arthrodesis employing the native scaphoid as the principal donor graft for advanced collapse deformity of the wrist: technique and outcomes. *J Hand Surg Eur Vol* 2017; 42:246-252
- 37** Merrell GA, McDermott EM, Weiss AP. Four-corner arthrodesis using a circular plate and distal radius bone grafting: a consecutive case series. *J Hand Surg Am* 2008; 33:635-642
- 38** Shindle MK, Burton KJ, Weiland AJ, Domb BG, Wolf SW. Complications of circular plate fixation for four-corner arthrodesis. *J Hand Surg Eur Vol.* 2007; 32:50-53



**Fig 1.**

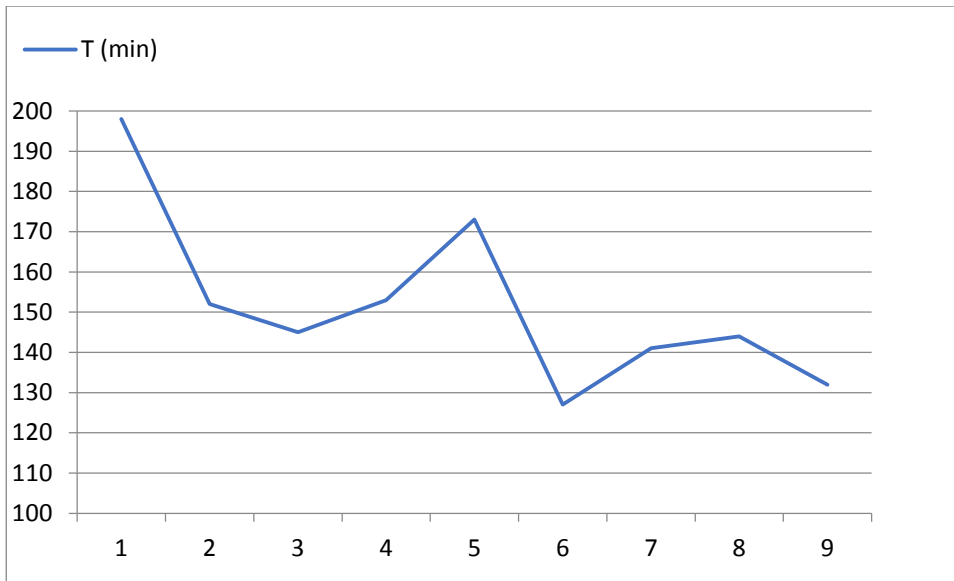
Arthroscopic portals 3-4, 6R, midcarpal radial and ulnar are created.



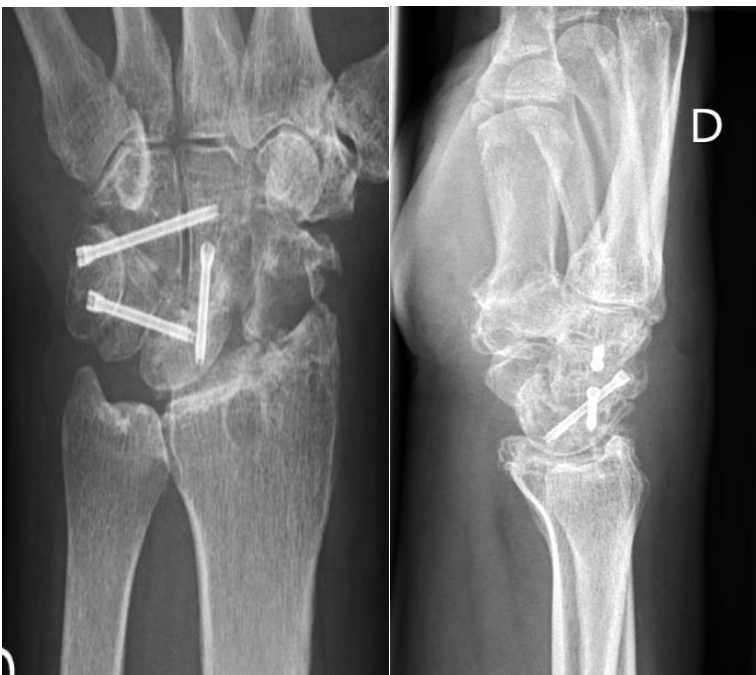**Fig 2.**

A 4.0 mm burr is used to remove the scaphoid and the articular surfaces of the midcarpal joint.

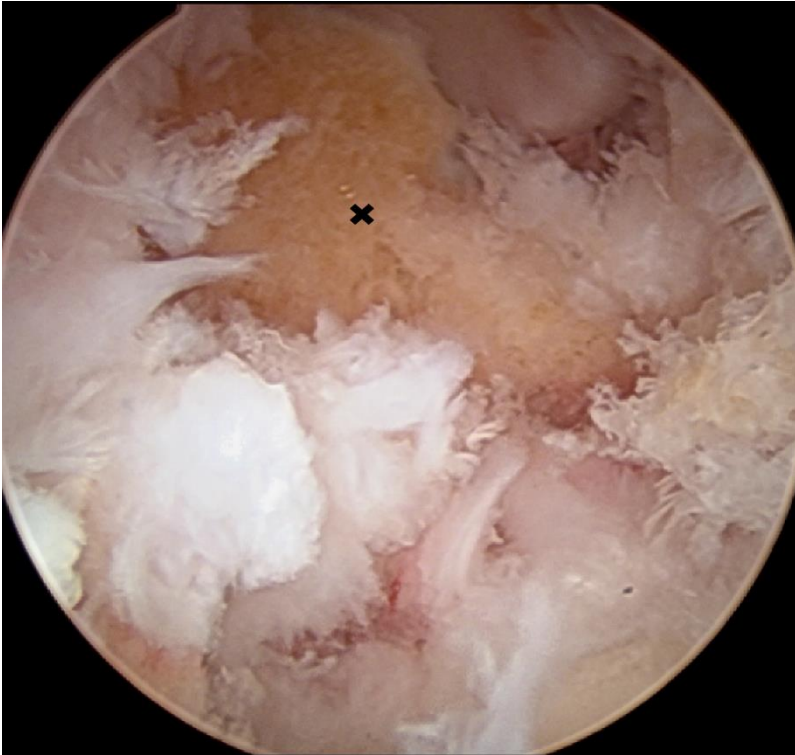



**Fig 3.**  
Operation times in chronological order.



**Fig 4a and 4b.**  
X-rays of a patient operated early in the series. A sizable scaphoid remnant combined with radial wrist pain led to reoperation to remove the entire scaphoid.



**Fig 5.**

An egg shell fragment of the distal tubercle often remains, since the arthroscopic removal of this fragment is extremely difficult. An inexperienced surgeon may cease the dissection prematurely leaving a sizeable scaphoid remnant. Radial wrist pain may occur postoperatively.

**Table 1.**

Patient demographics and results. One patient had bilateral A-4CA (case 5 and 6, interval between surgeries 12 months). Case 8's follow-up was carried out elsewhere.

Case	Age	Hand	Pathology	CL-angle pre-operatively	CL-angle post-operatively	First signs of bony union (months)	Active extension-flexion pre-operatively	Active extension-flexion post-operatively	Active extension-flexion contralaterally	Jamar pre-operatively (Kg)	Jamar post-operatively (Kg)	Jamar contralaterally (Kg)	Complications	Resurgery	Overall satisfied
1	57	D	SLAC III	19	6	7	45-35	35-25	65-60	22	29	46	None	None	y
2	59	D	RS-arthrosis	19	-11	3	50-30	50-15	60-70	29	37	51	None	Screw-removal	y
3	58	D	SLAC II	26	5	2	55-60	35-40	45-40	34	34	38	Tendon injury	Tendon reconstruction	n
4	58	D	SLAC III	3	0	2	40-60	20-30	65-70	26	20	35	None	Scaphoidectomy	n
5	47	ND	SLAC III	28	-6	2	60-65	50-25	45-60	38	30	28	None	None	y
6	48	D	SLAC III	19	7	7	45-60	50-25	50-25	28	32	36	Nerve injury	None	?
7	53	D	SLAC III	-40	-23	2	50-50	40-45	75-75	32	28	50	None	None	?
8	42	D	Preiser	9	-5	N/A	40-55	N/A	50-60	22	N/A	28	N/A	N/A	N/A
9	54	D	CL-arthrosis	3	0	2	N/A	35-30	N/A	28	30	42	None	None	y

D, dominant; ND, nondominant; RS, radioscaphoid; CL-angle, capitulate-angle, positive = extended, negative = volar flexed; ?, indecisive; N/A, not available; y, yes; n, no.

**Table 2.**

Follow-up times and bony union progression details.

<b>Case</b>	<b>Follow-up, 6 weeks</b>	<b>Follow-up, 3 months</b>	<b>Follow-up, 5 months</b>	<b>Additional follow-ups</b>	<b>Total follow-up time (months)</b>
1	N/A	Signs of bony union in CL-interval	CL-interval consolidated	Not needed	7
2	Signs of bony union in CL-interval	No progression	No progression	CL- and TH-interval consolidated (8 months)	13
3	Signs of bony union in CL-interval	CL-interval consolidated	N/A	Signs of bony union in TH-interval (7 months)	7
4	Signs of bony union in CL-interval	N/A	Signs of bony union in TH-interval	TH- and CL-interval consolidated (7 months)	15
5	Signs of bony union in CL-interval	Signs of bony union in TH-interval	CL-interval consolidated	No progression (8 months)	8
6	N/A	No signs of bony union	CL-interval consolidated	No progression (7 months)	10
7	CL-interval consolidated	No progression	Fully consolidated	Not needed	16
8	N/A	N/A	N/A	N/A	N/A
9	Signs of bony union in CL-interval	No progression	CL-interval consolidated	Not needed	5

CL-interval, capitulum-interval; TH-interval, triquetrohamate-interval; N/A, not available

