

SEZ6L2 Antibody–Associated Cerebellar Ataxia Responsive to Sequential Immunotherapy

Ayla Mehdiyeva, MD, Aki Hietaharju, MD, PhD, and Jussi Sipilä, MD, DMSc, BSocSci

Neurol Neuroimmunol Neuroinflamm 2022;9:e1131. doi:10.1212/NXI.0000000000001131

Correspondence

Dr. Mehdiyeva
ayla.mehdiyeva@siunsoite.fi

Abstract

Objectives

Seizure-related 6 homolog like 2 (SEZ6L2) antibody–associated ataxia is an extremely rare disease. Six patients have been reported and none of them improved significantly with immunotherapy. Herein, we present the case of a patient with cerebellar ataxia and SEZ6L2 antibodies who benefited from immunotherapy, which dramatically altered the course of her disease.

Methods

We present a case report of a 73-year-old woman with progressive balance problems. Her condition had rapidly deteriorated in the 2 weeks before the admission to our hospital leading to repeated falls and eventually left her bed-ridden.

Results

She presented with severe trunk ataxia, bidirectional nystagmus, dysarthric speech, and persistent nausea. With the exception of cerebellar atrophy, extensive imaging studies revealed no pathology. SEZ6L2 antibodies were found in both CSF and serum. Over a period of 9 months, our patient received immunotherapy consisting of steroid pulse therapy, IV immunoglobulin infusions, rituximab, and cyclophosphamide. Consequently, her condition improved markedly, and she was discharged home from the neurologic rehabilitation unit.

Discussion

Our case report shows that intense sequential immunotherapy may considerably improve level of functioning in some patients with SEZ6L2 antibody–associated cerebellar ataxia.

Classification of Evidence

This provides Class IV evidence. It is a single observational study without controls.

MORE ONLINE

Class of Evidence

Criteria for rating therapeutic and diagnostic studies

[NPub.org/coe](https://www.npub.org/coe)

Videos

From the Department of Neurology (A.M., J.S.), North Karelia Central Hospital, Joensuu; Department of Neurology (A.M.), University of Eastern Finland, Kuopio, Finland; Department of Neurology (A.H.), Tampere University Hospital; Clinical Neurosciences (J.S.), University of Turku, Turku, Finland.

Go to [Neurology.org/NN](https://www.neurology.org/NN) for full disclosures. Funding information is provided at the end of the article.

The Article Processing Charge was funded by FinELib.

This is an open access article distributed under the terms of the Creative Commons Attribution-NonCommercial-NoDerivatives License 4.0 (CC BY-NC-ND), which permits downloading and sharing the work provided it is properly cited. The work cannot be changed in any way or used commercially without permission from the journal.

Neuroimmunologic advances have recently led to the identification of autoantibodies in patients with progressive cerebellar ataxia. Among these are antibodies against seizure-related 6 homolog like 2 (SEZ6L2), a type 1 transmembrane protein. The symptoms associated with these immunoglobulin (Ig) G4 subclass antibodies also include dysphagia, cognitive impairment, mild extrapyramidal symptoms, retinopathy, apraxia, and spastic paraparesis.^{1,2} Six patients¹⁻³ with SEZ6L2 autoimmunity have been reported, and they have all had little or no treatment response. Here, we report a patient who markedly improved following sequential immunotherapy.

A 73-year-old woman was admitted to our hospital. She had been using escitalopram for depression for 19 years. Otherwise, her medical history was unremarkable, and she had no previous functional impairment. Her balance problems began 6 months before the admission leading eventually to several falls. A persistent nausea had also developed. Nevertheless, she had been able to walk unaided even outdoors until her condition began to deteriorate more rapidly a couple of weeks before the admission. Eventually, she was found lying in bed, with severe back pain. She said that she had fallen a couple of days earlier and had to crawl to bed because of severe postural instability.

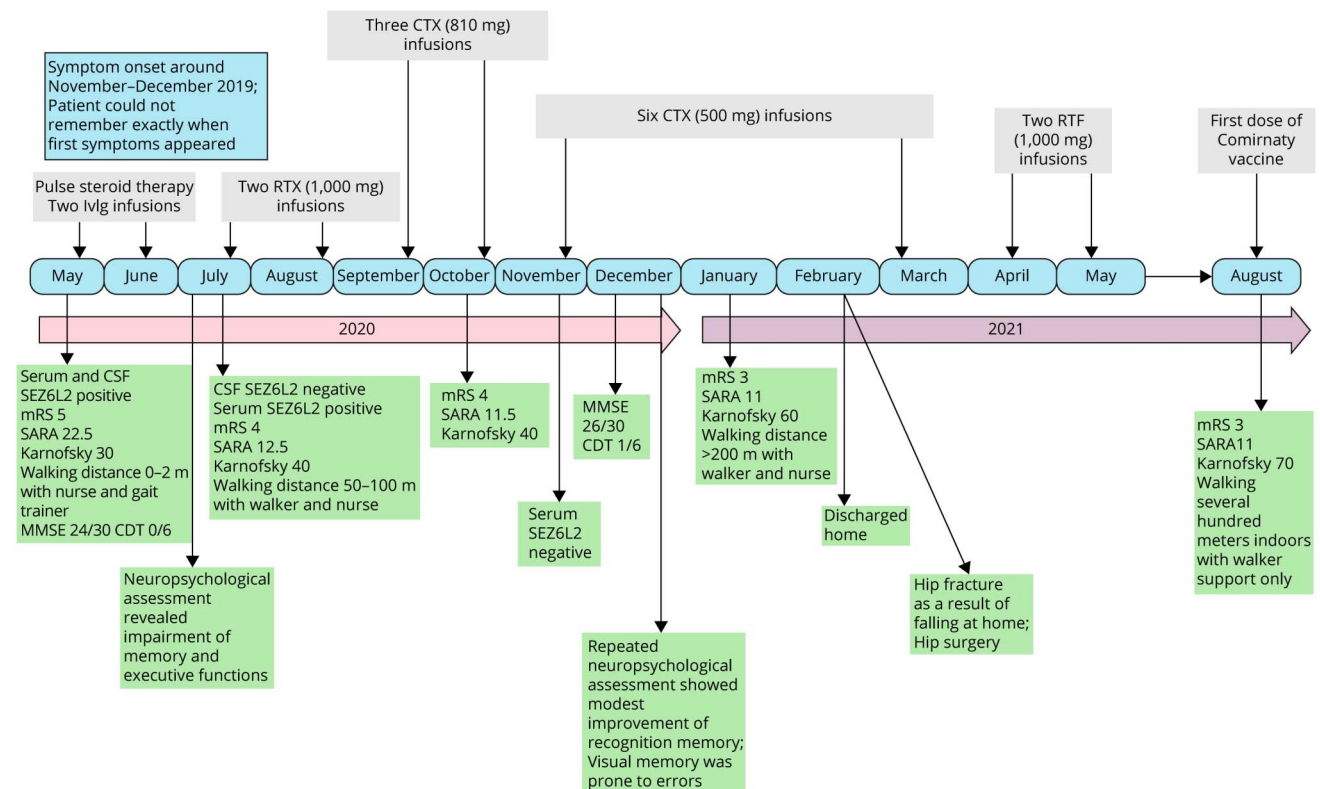
On admission, she had persistent bilateral gaze-evoked nystagmus, dysarthric speech, and severe truncal ataxia. There was dysmetria in

the finger chase test on the right. She was unable to stand or even sit without support. Mild bradykinesia and hypophonia were also observed (Videos 1 and 2). The disease course along with relevant clinical assessments and therapies is presented in the Figure.

Brain and spinal cord MRIs were unremarkable with the exception of cortical cerebellar atrophy (eFigures 1 and 2, links.lww.com/NXI/A680). Whole-body CT and PET-CT investigations revealed no pathology. Lumbosacral radiography showed a compression fracture at L1. Vitamin B1, B6, and B12 levels were within the normal range. Antibodies against tissue transglutaminase, glutamic acid decarboxylase, HIV, and *Treponema pallidum* were negative. A cell-based indirect immunofluorescence assay conducted at Stöcker Clinical Immunological Laboratory revealed SEZ6L2 antineuronal antibodies in both CSF (titer 1:3.2) and serum (1:100).

Over a period of 9 months, the patient received sequential immunotherapy. Steroid pulse therapy and 2 IVIg infusions resulted in slight improvement, but despite markedly improved scores on clinical scales, her overall condition remained poor with persistent nausea and poor mobility even after rituximab (RTX). Consistent improvement commenced following cyclophosphamide (CTX) initiation with steady recovery thereafter (Videos 3 and 4). Repeat brain MRI was unchanged (eFigures 3 and 4, links.lww.com/NXI/A680).

Figure June and July 2021 Were Not Included in the Timeline as No Specific Medication Was Administered in That Time



CDT = Clock Drawing Test; CTX = cyclophosphamide; IVIg = intravenous immunoglobulin infusion; Karnofsky = Karnofsky Performance Status Scale (0-100); MMSE = Mini-Mental State Examination; mRS = modified Rankin Scale (0-6); RTX = rituximab; SARA = Scale for the Assessment and Rating of Ataxia (0-40).

She was discharged from the neurologic rehabilitation ward to her own home 5 months after starting CTX. At a follow-up visit 5 months after the final CTX infusion, she reported slow but continuous improvement, which was also clinically noticeable (Videos 5 and 6), despite the fact that she had sustained a hip fracture in the meantime (Figure). She now lived at home requiring only 1 daily visit by home care.

SEZ6L2 antibody-associated cerebellar ataxia is an ultra-rare disease, therefore our case is interesting because of the substantial treatment response.

The symptoms caused by SEZ6L2 antibodies stem from their known predilection against cerebellar and hippocampal neuronal cell surface antigens.⁴ This is in accordance with our patient's initial symptoms, consisting of ataxia, oculomotor disturbances, dysarthria, mild bradykinesia, and mild cognitive impairment, which were also manifested in previously published cases.¹⁻³ Contrary to prior reports, our patient showed substantial improvement following immunotherapy, culminating in her return home.

Four of the 6 previously published patients did not benefit from immunotherapy, whereas the remaining 2 patients stabilized and showed mild improvement.^{1,3} Notably, immunotherapy was initiated within 2 months of symptom onset in only 1 of these patients and more than a year after the onset of symptoms in 2.²

In our patient, clinical improvement cannot be solely attributed to CTX because it was started only 2 months after RTX. It is feasible that the sustained response was due to combined medication.

At some point, 2 previously published patients had received CTX without clear treatment response.² Two other patients^{2,3} had been given RTX with treatment response in only 1, whose symptoms (less severe than in our patient) stabilized.³ The reasons for these differences in treatment response are unknown.

Previous reports on SEZ6L2 antibody-associated syndrome have suggested that even without treatment, the symptom progression may slow down or cease, but spontaneous improvement has not been reported. Our case report shows that intense sequential immunotherapy may considerably improve level of functioning in some patients.

Study Funding

No targeted funding reported.

Disclosure

A. Mehdiyeva and A Hietaharju report no disclosures relevant to the study from the past 2 years. J. Sipilä has received honoraria (Merck, Pfizer, and Sanofi), consultancy fees (Rinneke Foundation and Medaffcon), and travel grants and congress sponsorship (AbbVie, Orion Pharma, Merck Serono, Sanquin, Lundbeck, and Novartis) and holds shares (Orion Corporation). Go to [Neurology.org/NN](https://www.neurology.org/NN) for full disclosures.

Publication History

Received by *Neurology: Neuroimmunology & Neuroinflammation* September 26, 2021. Accepted in final form November 24, 2021.

Appendix Authors

Name	Location	Contribution
Ayla Mehdiyeva, MD	Department of Neurology, North Karelia Central Hospital, Joensuu, Finland; Department of Neurology, University of Eastern Finland, Kuopio, Finland	Drafting/revision of the manuscript for content, including medical writing for content; major role in the acquisition of data; and analysis or interpretation of data
Aki Hietaharju, MD, PhD	Department of Neurology, Tampere University Hospital, Finland	Drafting/revision of the manuscript for content, including medical writing for content; study concept or design; and analysis or interpretation of data
Jussi Sipilä, MD, DMSc, BSocSci	Department of Neurology, North Karelia Central Hospital, Joensuu, Finland; Clinical Neurosciences, University of Turku, Turku, Finland	Drafting/revision of the manuscript for content, including medical writing for content; study concept or design; and analysis or interpretation of data

References

1. Yaguchi H, Yabe I, Takahashi H, et al. Identification of anti-Sez6l2 antibody in a patient with cerebellar ataxia and retinopathy. *J Neurol*. 2014;261(1):224-226. doi:10.1007/s00415-013-7134-5.
2. Landa J, Guasp M, Petit-Pedrol M, et al. Seizure-related 6 homolog like 2 autoimmunity Neurologic syndrome and antibody effects. *Neurol Neuroimmunol Neuroinflamm*. 2021;8(1):e916. doi:10.1212/NXI.0000000000000916.
3. Borsche M, Hahn S, Hanssen H, Münchau A, Wandinger KP, Brüggemann N. Sez6l2-antibody-associated progressive cerebellar ataxia: a differential diagnosis of atypical parkinsonism. *J Neurol*. 2019;266(2):S22-S24. doi:10.1007/s00415-018-9115-1.
4. Qiu WQ, Luo S, Ma SA, et al. The Sez6 family inhibits complement by facilitating factor I cleavage of C3b and accelerating the decay of C3 convertases. *Front Immunol*. 2021;12:607641. doi:10.3389/fimmu.2021.607641.

Neurology® Neuroimmunology & Neuroinflammation

SEZ6L2 Antibody–Associated Cerebellar Ataxia Responsive to Sequential Immunotherapy

Ayla Mehdiyeva, Aki Hietaharju and Jussi Sipilä
Neurol Neuroimmunol Neuroinflamm 2022;9;
DOI 10.1212/NXI.0000000000001131

This information is current as of January 14, 2022

Neurol Neuroimmunol Neuroinflamm is an official journal of the American Academy of Neurology. Published since April 2014, it is an open-access, online-only, continuous publication journal. Copyright © 2022 The Author(s). Published by Wolters Kluwer Health, Inc. on behalf of the American Academy of Neurology.. All rights reserved. Online ISSN: 2332-7812.



Updated Information & Services	including high resolution figures, can be found at: http://nn.neurology.org/content/9/2/e1131.full.html
References	This article cites 4 articles, 0 of which you can access for free at: http://nn.neurology.org/content/9/2/e1131.full.html##ref-list-1
Subspecialty Collections	This article, along with others on similar topics, appears in the following collection(s): All Immunology http://nn.neurology.org/cgi/collection/all_immunology Autoimmune diseases http://nn.neurology.org/cgi/collection/autoimmune_diseases Class IV http://nn.neurology.org/cgi/collection/class_iv Encephalitis http://nn.neurology.org/cgi/collection/encephalitis Gait disorders/ataxia http://nn.neurology.org/cgi/collection/gait_disorders_ataxia
Permissions & Licensing	Information about reproducing this article in parts (figures, tables) or in its entirety can be found online at: http://nn.neurology.org/misc/about.xhtml#permissions
Reprints	Information about ordering reprints can be found online: http://nn.neurology.org/misc/addir.xhtml#reprintsus

Neurol Neuroimmunol Neuroinflamm is an official journal of the American Academy of Neurology. Published since April 2014, it is an open-access, online-only, continuous publication journal. Copyright © 2022 The Author(s). Published by Wolters Kluwer Health, Inc. on behalf of the American Academy of Neurology. All rights reserved. Online ISSN: 2332-7812.

