


# Multiple Cranial Nerve Gadolinium Enhancement in Norrie Disease

Manu Jokela, MD, PhD <sup>1,2</sup>, Jari Karhu, MD,<sup>3</sup> Janne Nurminen, MD, PhD,<sup>3</sup> and Mika H. Martikainen, MD, PhD<sup>1,2,4</sup>

Norrie disease is a recessive x-linked genetic disorder (MIM# 310600) that is associated with early childhood blindness due to vascular proliferative changes in the retina, as well as cognitive impairment, seizures, and sometimes sensorineural hearing loss with onset later in life. We describe here a 45-year-old Finnish male with Norrie disease, who lived in a nursing home due to visual impairment, learning disability, and epilepsy and was referred to an otolaryngologist because of progressive impairment of hearing. A brain MRI showed gadolinium enhancement of several cranial nerves (CN): III; V, VII, VIII, IX, X, and XI as an unexpected finding. 1 displays gadolinium enhancement of CNs III, V, VIII and X in T1 weighted axial (A–D) images. A and B represent 5 mm maximum intensity projection reformatted sections. Imaging was repeated 9 months later, with similar findings. Cerebrospinal fluid investigation revealed elevated protein (1,066 mg/l; reference range 150–450 mg/l), but no pleocytosis and no oligoclonal immunoglobulin G bands.

On investigation, the patient walked with assistance, there was no tremor, deep tendon reflexes were intact, and muscle strength and tone were normal. There were no signs of meningeal irritation. He was congenitally blind, used a hearing aid, and was able to hear loud speech. Except for the slowly progressive hearing loss, the patient's clinical condition had remained unchanged over recent years, and his epilepsy was well controlled.

The diagnosis of Norrie disease was genetically confirmed by demonstrating a hemizygotic and previously reported c.182 T > C, p.(Leu61Pro) mutation in the *NDP*<sup>1,2</sup> gene. This variant was not found in the GnomAD population reference database, and it was classified as pathogenic by *in silico* prediction algorithms SIFT and CADD.

Despite considerable inter-individual variation, the core phenotype of Norrie disease is well established. It consists of congenital blindness, progressive hearing loss as well as cognitive and psychosocial disturbances, including autism spectrum features.<sup>3</sup> Seizures or epilepsy are reported in nearly 10% of patients with Norrie disease.<sup>3</sup>

There is little published information on the brain MR findings in patients with Norrie syndrome. *NDP* gene codes for the Norrin protein, the function of which relate to vascular architecture and development, as well as integrity of the blood–brain barrier (BBB).<sup>4</sup> We suggest that the imaging findings in our patient reflect the defective BBB function in Norrie syndrome. This information may be useful in the clinical care of patients with Norrie disease, so that unnecessary extensive diagnostic investigations might be avoided.

## Author Contributions

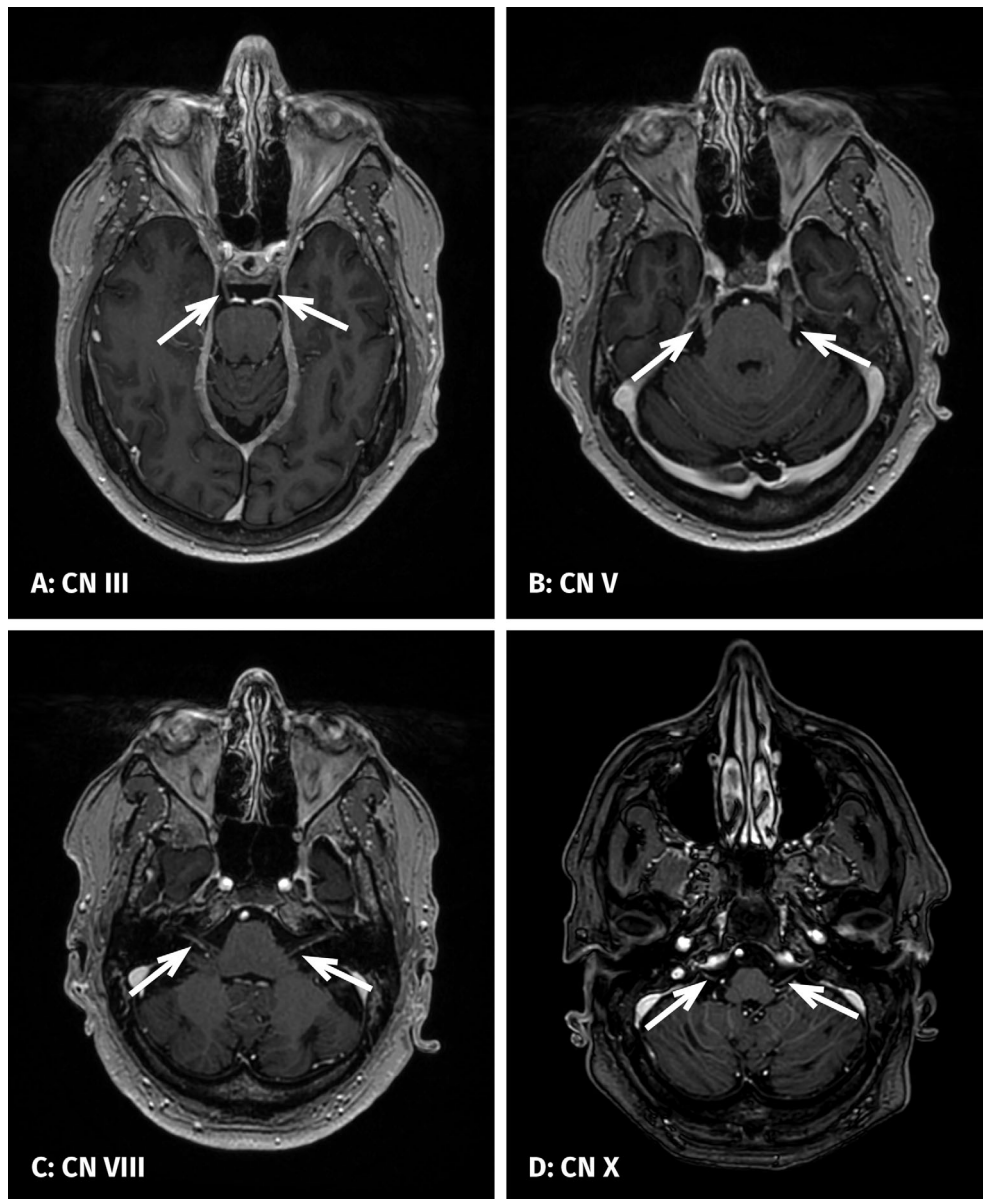
1) conception and design of the study: M.J., M.H.M., 2) acquisition and analysis of data M.J., J.K., J.N., M.H.M., 3) drafting a significant portion of the manuscript or figures (M.J., J.K., J.N., M.H.M.).

View this article online at [wileyonlinelibrary.com](https://onlinelibrary.wiley.com/doi/10.1002/ana.26274). DOI: 10.1002/ana.26274

Received Sep 25, 2021, and in revised form Nov 8, 2021. Accepted for publication Nov 13, 2021.

Address correspondence to Jokela, Department of Neurology, Turku University Hospital, 20520 Turku, Finland. E-mail: mejoke@utu.fi

From the <sup>1</sup>Neurology, Clinical Medicine, University of Turku, Turku, Finland; <sup>2</sup>Neurocenter, Turku University Hospital, Turku, Finland; <sup>3</sup>Department of Radiology, Turku University Hospital, Turku, Finland; and <sup>4</sup>Department of Neurology, Satasairaala Hospital, Pori, Finland



**FIGURE:** Gadolinium enhancement of CNs III, V, VIII and X in T1 weighted axial (A–D) images. A and B represent 5 mm maximum intensity projection reformatted sections.

**Potential Conflicts of Interest**

Nothing to report.

**References**

1. Berger W, Meindl A, van de Pol TJ, et al. Isolation of a candidate gene for Norrie disease by positional cloning. *Nat Genet* 1992;1: 199–203.
2. Schuback DE, Chen ZY, Craig IW, et al. Mutations in the Norrie disease gene. *Hum Mutat* 1995;5:285–292.
3. Smith SE, Mullen TE, Graham D, et al. Norrie disease: extraocular clinical manifestations in 56 patients. *Am J Med Genet A* 2012;158A: 1909–1917.
4. Wang Y, Rattner A, Zhou Y, et al. Norrin/Frizzled4 signaling in retinal vascular development and blood brain barrier plasticity. *Cell* 2012; 151:1332–1344.