




Sinonasal inverted papilloma – malignant transformation and non-sinonasal malignancies

Sanna Viitasalo, MD ; Taru Ilmarinen, MD, PhD;

Leena-Maija Aaltonen, MD, PhD; Jaana Hagström, DDS, PhD; Maija Hytönen, MD, PhD ;

Sari Hammarén-Malmi, MD, PhD; Petra Pietarinen, MD, PhD; Pia Järvenpää, MD, PhD;

Teemu Kinnari, MD, PhD; Ahmed Geneid, MD, PhD ; Markus Lilja, MD, PhD 

Objectives: To assess malignant transformation rate, non-sinonasal malignancies, and factors contributing to recurrence in patients treated for sinonasal inverted papilloma (SNIP).

Study Design: Retrospective study.

Methods: We retrospectively reviewed medical records of all patients treated for SNIP ($n = 296$) between the years 1984–2014 at Helsinki University Hospital. Data from the Finnish Cancer Registry confirmed the number of those patients with sinonasal and non-sinonasal malignancies.

Results: Only 2 of 296 (0.7%) patients primarily diagnosed with benign SNIP developed sinonasal cancer in a mean follow-up of 5.8 years. The most common non-sinonasal cancer sites were similar to those reported for the whole Finnish population. None of the patients presented with an HPV-associated non-sinonasal malignancy. The recurrence rate among patients who underwent attachment-oriented surgery was significantly lower compared to those operated on with other approaches (40.2% vs. 56.6%, $p = 0.006$). Dysplasia in SNIP was associated with a higher recurrence rate ($p < 0.001$).

Conclusions: Malignant transformation of SNIP was rare. Patients with SNIP were not prone to HPV-associated non-sinonasal malignancies. Endoscopic resection and attachment-oriented surgery have become predominant approaches in the treatment of SNIP; meanwhile, the total number of SNIP recurrences has decreased.

Key Words: inverted papilloma, operative treatment, sinonasal carcinoma, sinonasal neoplasm, sinonasal papilloma.

Level of Evidence: 3

Laryngoscope, 133:506–511, 2023

INTRODUCTION

Sinonasal inverted papilloma (SNIP) is a benign epithelial tumor characterized by a locally aggressive growth pattern, the propensity to recur, and the potential for malignant transformation. Krouse staging system is used to define the extent of SNIP at diagnosis.¹ According to a meta-analysis, Krouse stage T3 is more likely to recur than stage T2. However, the difference between stages T1

and T2, and also between T3 and T4, is insignificant.² A higher prevalence of HPV infection, and also increased risk for SNIP recurrence have been observed in smokers.^{3,4} The risk for SNIP recurrence may also depend on surgical technique. The preferred method for treatment of SNIP is endoscopic surgery.^{5,6} Identifying and removing the tumor attachment site along with periosteum, followed by drilling or removing the underlying bone, may reduce the risk for recurrence.^{4,7} Few studies have assessed whether the risk of SNIP recurrence has declined over the course of time, due to the improvements in endoscopic instrumentation and techniques. The estimated rate of malignant transformation in SNIP is 10%.⁸ Squamous cell carcinoma (SCC) is the most common type, and it may present simultaneously with the primary SNIP tumor (synchronous), or after previous treatments for benign SNIP (metachronous). According to a review by Mirza et al. the rate of synchronous malignant transformation is 7.1% and metachronous 3.6%.⁹ Malignant transformation of SNIP may be associated with high-risk HPV infection.¹⁰ The risk for non-sinonasal malignancies in patients with SNIP is unclear.

We assessed the malignant transformation rate, the occurrence of non-sinonasal malignancies, and factors associated with recurrence in patients with SNIP.

This is an open access article under the terms of the [Creative Commons Attribution-NonCommercial License](https://creativecommons.org/licenses/by-nc/4.0/), which permits use, distribution and reproduction in any medium, provided the original work is properly cited and is not used for commercial purposes.

From the Department of Otorhinolaryngology - Head and Neck Surgery (S.V., T.I., L.-M.A., M.H., S.H.-M., P.P., P.J., T.K., A.G., M.L.), University of Helsinki and Helsinki University Hospital, Helsinki, Finland; Department of Pathology (J.H.), Helsinki University Hospital, Helsinki, Finland; and the Department of Oral Pathology and Radiology (J.H.), University of Turku, Turku, Finland.

Editor's Note: This Manuscript was accepted for publication on March 14, 2022.

This work was supported by the Helsinki University Hospital research funds.

The authors have no other funding, financial relationships, or conflicts of interest to disclose.

Send correspondence to Sanna Viitasalo, ENT Specialist, Department of Otorhinolaryngology – Head and Neck Surgery, Helsinki University Hospital, P.O.Box 263, Helsinki FI-00029 HUS, Finland.

E-mail: sanna.viitasalo@hus.fi

DOI: 10.1002/lary.30128

MATERIALS AND METHODS

Patients

A comprehensive search for patients diagnosed with SNIP between the years 1984–2014 was conducted from the data register held by the Department of Pathology, Helsinki University Hospital, using the search word “papilloma inversum.” Medical records and pathology reports were retrospectively reviewed from all patients. SNIP histology, with endophytic or inverted growth patterns and thickened squamous epithelial proliferation, growing downward into the underlying connective tissue stroma, was confirmed in 296 patients. Presenting symptoms and preoperative imaging studies (CT, MRI) were reported, and Krouse classification at diagnosis was determined based on endoscopy and imaging. We registered the SNIP attachment site, type of surgery (endoscopic vs. open surgery, or combined), and treatment of the attachment site. Medical records were reviewed for the number of recurrences and surgeries, as well as the date of the last recurrence-free follow-up visit. Patients with an unknown date of diagnosis, missing pathology reports, or only one biopsy specimen without indisputable SNIP histology, were excluded. The study was approved by the Ethics Committee, Surgery and the Research Administration of Helsinki University Hospital.

Non-Sinonasal Malignancies and Malignant Transformation of SNIP

Approval from the National Institute for Health and Welfare was obtained to access the Finnish Cancer Registry, which has maintained a nationwide database on all cancer patients in Finland since 1953. Thus, both sinonasal and non-sinonasal malignancies diagnosed in Finland between 1953 and 2015 were reported for all study patients. Medical records were re-reviewed for patients with metachronous malignancy to analyze risk factors, treatment of sinonasal SCC, follow-up, recurrences, and survival.

Statistical Analyses

IBM SPSS Statistics software version 27 (SPSS, Inc., Chicago, IL, USA) was run for the statistical analyses. The Chi-Square test and Fisher’s Exact Test were used to evaluate the differences in categorical variables between groups. T-test was used in continuous variables with normal distribution, and Mann–Whitney U-test for continuous variables without normal distribution. Kaplan–Meier method and log rank test were used to compare the association of different variables on SNIP recurrence in a 5-year follow-up. Cox regression was used in multivariate analysis. Statistical significance was set at 0.05.

RESULTS

Patients

The study material comprised 296 patients with SNIP. Table I presents the baseline characteristics of all study patients. The mean age at diagnosis was 54.2 years (median 54.4 years, range 17.5–89.4 years), and 71.3% of the patients were males. Nasal obstruction was the most common presenting symptom of SNIP, whereas nasal discharge and nasal bleed were less common. At diagnosis, most of the tumors were Krouse stage T3, followed by stages T1, T2, and T4. SNIP was operated on in 293 of

TABLE I.
Baseline Characteristics of All Study Patients.

Characteristics	Number of patients (%)
Number of patients	296
Sex	
Female	85 (28.7)
Male	211 (71.3)
Diagnosis of nasal polyps before SNIP	57 (19.3)
Presenting symptoms of SNIP	
Nasal obstruction	208 (70.3)
Nasal discharge	66 (22.3)
Nasal bleed	32 (10.8)
Imaging before operation	
CT	252 (85.1)
MRI	35 (11.8)
Krouse classification	
T1	74 (25)
T2	63 (21.3)
T3	157 (53)
T4	2 (0.7)
Highest grade of dysplasia during follow-up	
NO	262 (88.5)
Mild	27 (9.1)
Moderate	3 (1)
Severe	4 (1.4)
Operated	
YES	293 (99.0)
NO	3 (1.0)
Attachment oriented surgery at 1 st operation	
YES	97 (32.8)
NO or not mentioned	199 (67.2)
SNIP attachment site	
Not available	122 (41.2)
Nasal cavity	74 (25.0)
Maxillary sinus	48 (16.2)
Ostiomeatal complex	16 (5.4)
Multifocal	15 (5.1)
Ethmoid	12 (4.1)
Frontal sinus or -ductus	6 (2.0)
Sphenoid sinus	3 (1.0)
Recurrences	
NO	143 (48.3)
1–2	90 (30.4)
3 or more	60 (20.3)
Persistent*	3 (1.0)
Malignant transformation of SNIP	2 (0.7)
Non-sinonasal malignancy	
YES	52 (17.6)
NO	244 (82.4)

SNIP = sinonasal inverted papilloma.

*Three patients were inoperable due to poor overall health status.

296 patients, whereas in 3 of 296 patients an attempt to remove SNIP was not feasible due to poor overall health status.

TABLE II.
Non-Sinonasal Malignancies in 52 of 296 (17.6%) Patients with SNIP.

Cancer site	Males (n)	Females (n)
Prostate	12	0
Colorectal	5	3
Breast	0	5
Lymphoma	3	1
Lung	3	1
Bladder	4	0
Pancreas	4	0
Gastric	3	0
Kidney	3	0
Liver	0	2
Thyroid gland	1	1
Ovario	0	1
Melanoma	0	1
Myeloma	0	1
Plasmacytoma	1	0
Uterus (corpus)	0	1
Spinocellular carcinoma (skin)	1	0
Dermatofibrosarcoma protuberans (skin)	1	0
Meninges	0	1
Brain	1	0
Undefined	1	0

These also include malignancies diagnosed before SNIP diagnosis.

Malignant Transformation of SNIP

During the follow-up (mean 69.3, range 1.6–1132.1 months from diagnosis), two of 296 patients (0.7%) developed metachronous sinonasal SCC. Both patients with SCC (age at SNIP diagnosis 52.6 and 51.4 years) were males. Both patients had one SNIP recurrence before SCC, and the time between the first SNIP diagnosis and SCC was 16.7 and 25.5 months respectively.

Non-Sinonasal Malignancies

According to the data from the Finnish Cancer Register, 52 of 296 (17.6%) patients were diagnosed with cancer other than sinonasal carcinoma (basal cell carcinomas excluded) by the end of the follow-up (Table II). In patients with SNIP, the most common non-sinonasal cancer sites of origin, prostate, breast, and colorectal were similar to what is reported for the whole Finnish population. None of the patients presented with a high-risk HPV-associated non-sinonasal malignancy.

Factors Associated with SNIP Recurrence

Of 296 patients with SNIP 293 (99%) were operated on. Among these 293 patients, SNIP never recurred in 143 (48.8%) patients, 90 (30.7%) had 1 to 2 recurrences and 60 (20.5%) had 3 or more recurrences. The overall recurrence rate among all 293 operated patients with SNIP was 51.2%. The mean follow-up time after diagnosis among the non-recurrent patients was 45.7 months

TABLE III.
Factors Associated with Recurrence in 293 Operated Patients with SNIP.

	All patients	Non-recurrent	1–2 recurrences	3 or more recurrences	p value
Sex, n (%)					0.17
Male	211	100 (47.4)	62 (29.4)	49 (23.2)	
Female	82	43 (52.4)	28 (34.1)	11 (13.4)	
Age at diagnosis					0.39
Mean	53.9	54.6	54.2	51.6	
Range	17.5–87.4	21.8–81.9	20.1–87.4	17.5–82.8	
Krouse					0.09
T1–T2	136	75 (55.1)	39 (28.7)	22 (16.2)	
T3–T4	157	68 (43.3)	51 (32.5)	38 (24.2)	
Dysplasia					<0.001
NO	259	136 (52.5)	78 (30.1)	45 (17.4)	
YES*	34	7 (20.6)	12 (35.3)	15 (44.1)	
Primary surgery					0.04
Endoscopic	173	86 (49.7)	59 (34.1)	28 (16.2)	
Open or combined	117	56 (47.9)	29 (24.8)	32 (27.4)	
Not applicable	3	1 (33.3)	2 (66.7)	0 (0)	
Attachment-oriented surgery					0.03
YES	97	58 (59.8)	25 (25.8)	14 (14.4)	
NO or not reported	196	85 (43.4)	65 (33.2)	46 (23.5)	

*Presence of dysplasia in primary SNIP, recurrent SNIP, or both.

TABLE IV.
Comparison of the Operative Treatment at Different Time Periods
Among 293 Patients with SNIP.

	Year	Year	<i>p</i>
	1984–2009	2010–2014	
	Number of patients (%)		
All patients	191 (65.2)	102 (34.8)	
Primary surgery			<0.001
Endoscopic	88 (46.1)	85 (83.3)	
Open or combined	100 (52.4)	17 (16.7)	
Not applicable	3 (1.6)	0 (0)	
Attachment oriented surgery			<0.001
YES	46 (24.1)	51 (50.0)	
NO or not mentioned	145 (75.9)	51 (50.0)	

(median 34.8 months; range 1.6–281.2 months). Krouse stage, surgical approach, tumor location, and treatment of SNIP attachment site for patients with non-recurrent and recurrent SNIP are presented in Table III. The absence of dysplasia in SNIP ($p < 0.001$), exclusively endoscopic approach during first surgery ($p = 0.04$), and attachment-oriented surgery ($p = 0.03$) were statistically significantly associated with fewer recurrences (non-recurrent vs. 1 or 2 recurrences vs. 3 or more recurrences, Table III).

Year of Diagnosis

Table IV presents how the treatment of SNIP has evolved over time. In patients diagnosed between 2010 and 2014, endoscopic technique and attachment-oriented surgery were significantly more often applied at primary surgery compared to patients diagnosed before 2010. SNIP recurrence rate was 54.5% in patients treated

before the year 2010, and 45.1% in patients treated between 2010 and 2014. SNIP diagnosis before the year 2010 was statistically significantly associated with a higher total number of recurrences (Mann–Whitney $p = 0.005$). Figure 1 presents the comparison of patients with SNIP recurrences diagnosed between the two time periods. The median follow-up time after diagnosis among the patients (whose SNIP was operated) diagnosed before the year 2010 and between the years 2010–2014 was 60.3 (range 1.6–1132.1) months and 38.8 (range 3.5–212.8) months, respectively ($p < 0.001$).

Attachment Site

In 196 of 296 patients (66.2%), removal of SNIP during primary surgery was considered successful, but the tumor was not operated on in an attachment-oriented manner according to the surgery report. Among these 196 patients, SNIP did not recur in 85 (43.4%) patients, 65 (33.2%) had 1 to 2 recurrences, and 46 (23.5%) had 3 or more recurrences (Table III). The recurrence rate among these 196 patients was 56.6%. The mean follow-up time after diagnosis among the non-recurrent patients was 50.4 months (median 37.6 months; range 1.6–281.2 months).

In 97 of 296 patients (32.8%), removal of macroscopic SNIP during primary surgery was accomplished by attachment-oriented excision (tumor attachment site was treated by drilling, by bone removal or with a sharp instrument). Of these 97 patients, 72 (74.2%) underwent an endoscopic procedure, whereas an open approach was used in 1 (1%), and a combined technique in 24 (24.7%) patients. SNIP did not recur in 58 (59.8%) of these patients (Table III). The mean follow-up time after diagnosis among the non-recurrent patients was 38.8 months (median 32.3; range 2.3–160.4 months). Among these 97 patients, 25 (25.8%) had 1 to 2 recurrences, and 14 (14.4%) of 97 patients had 3 or more recurrences

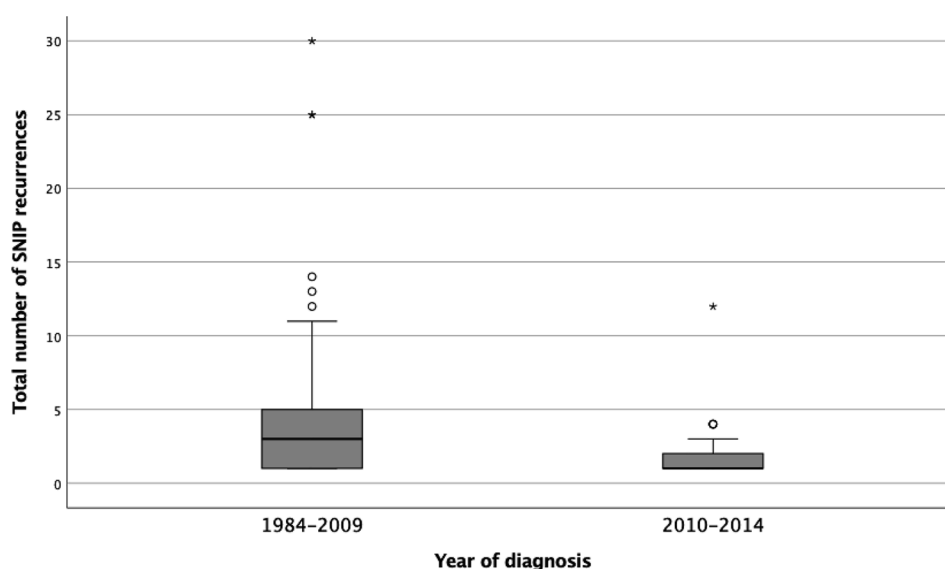

Fig. 1. Comparison of patients with SNIP recurrences diagnosed between 1984 and 2009 ($n = 104$) versus 2010–2014 ($n = 46$). SNIP, sinonasal inverted papilloma

Covariate	HR	95% CI	p-value
Dysplasia			
NO	1.0 (reference)		
YES	2.0	1.3–3.2	0.001
Attachment-oriented surgery			
YES	1.0 (reference)		
NO or not reported	1.4	1.0–2.1	0.08
Year of diagnosis			
2010–2014	1.0 (reference)		
Before 2010	1.0	0.7–1.4	1.00
Krouse stage			
1–2	1.0 (reference)		
3–4	1.2	0.8–1.6	0.35

(Table III). The recurrence rate among the patients who underwent attachment-oriented excision was 40.2%.

Among all 293 patients, whose tumor was operated on, the recurrence rate (non-recurrent vs. recurrent SNIP) was significantly lower among the patients whose tumor was operated in an attachment-oriented manner compared with the patients whose tumor excision was not attachment-oriented ($p = 0.006$). The difference between groups remained statistically significant ($p = 0.03$) when patients with recurrent SNIP were further divided according to the number of recurrences (1 or 2 recurrences versus 3 or more recurrences, Table III).

Factors Associated with 5-Year Recurrence

Kaplan–Meier with log rank test was used to further analyze differences between recurrent and non-recurrent SNIP with varying follow-up periods: the risk for SNIP recurrence in 5-year follow-up was significantly higher in patients not operated in an attachment-oriented manner ($p = 0.03$), and in patients whose SNIP harbored dysplasia at some point during follow-up ($p < 0.001$). However, Kaplan–Meier with log rank test showed no significant difference in the risk of recurrence in a 5-year follow-up between the patients diagnosed before the year 2010 and the patients diagnosed between 2010 and 2014. SNIP recurrence in a 5-year follow-up was not associated with an exclusively endoscopic approach during the first surgery. Multivariate analysis showed that dysplasia at some point during follow-up was an independent risk factor for SNIP recurrence in a 5-year follow-up ($p = 0.001$). Other used covariates included an attachment-oriented resection, year of diagnosis, and Krouse stage (Table V).

DISCUSSION

To our knowledge, this is the largest patient series having all malignancies of patients with SNIP searched from a national cancer registry. Mean age at diagnosis and male to female ratio correspond to previous

studies.^{11,12} The metachronous malignant transformation rate in our study was only 0.7%. This is lower than reported in the literature and may be beneficial information in patient counseling. However, patients with SNIP are sometimes diagnosed with a simultaneous SCC (synchronous carcinoma), but this study included only those with a benign SNIP lesion at diagnosis. HPV-associated non-sinonasal cancers were not overrepresented among our study patients. Instead, the most common non-sinonasal cancer types in our patients were similar to the most frequent cancers in the Finnish population.¹³

The risk of recurrence in a 5-year follow-up was not significantly associated with the year of diagnosis. However, in patients diagnosed before the year 2010 the total number of SNIP recurrences was significantly higher. This finding must be interpreted with caution since the length of follow-up in patients diagnosed before 2010 was longer. The decrease in the number of recurrences may be associated with the changes in the treatment protocols at our clinic during the years examined. Previously, an etiological role for HPV was suspected in SNIP. Possibly, this led to a misconception of SNIP being viral neoplasia that cannot be eradicated by surgery. The involvement of imaging, endoscopic techniques and the introduction and advancement of surgical navigators and monitors may have an impact. In addition, an important explanation presumably is the attachment-oriented tumor removal that has become the preferred method in our clinic as well as endoscopic technique. We compared patients diagnosed between years 2010 and 2014 to patients diagnosed before the year 2010 because the last 5-year period best compares to the present era in terms of surgical technique and instrumentation (navigators, monitors, endoscopes).

Attachment-oriented surgery significantly decreased the risk for SNIP recurrence among our patients. There is increasing evidence supporting attachment-oriented removal of SNIP in recent literature.^{14,15} Adriaensen et al. concluded that identification of the attachment site and the completeness of the tumor resection in the first operation are the most important factors decreasing the recurrence risk.¹⁶ The average recurrence rate of SNIP ranges from 5 to 50 percent in literature.¹¹ The recurrence rate of 40.2 among our patients who underwent attachment-oriented surgery and 51.2 among all operated patients with SNIP are similar to previous studies.

Dysplasia of primary SNIP, recurrent SNIP, or both were significantly associated with the recurrence risk in patients with SNIP. A recent study by Lee et al. and a review by Safadi et al. also concluded that dysplasia is a risk factor for recurrence of SNIP.^{17,18} In contrast, studies by Lin et al., Mortuaire et al. and Kaufman et al. found no significant association between dysplasia and recurrence of SNIP.^{19–21}

Krouse classification was not significantly associated with the risk of recurrence in patients with SNIP in our study. This is in accordance with previous studies. However, a recent meta-analysis found a significant increase in recurrence rate when Krouse stage T3 was compared to stage T2, but no significant difference in the recurrence risk was found between Krouse stage T1 and T2 or T3 and

T4.² Nakayama et al. did not find a significant difference in disease-free survival between stages defined by Krouse.²² Interestingly, the vast majority of the multifocal tumors in our study recurred. Krouse classification does not consider the multicentricity of the tumor. Ethmoidal tumors are an interesting group also, as almost half of the ethmoidal tumors in our study recurred.

Limitations of our study are inherent to the retrospective setting. Data on tumor attachment sites and the exact method for SNIP removal were often inadequately described. Furthermore, the division between recurrent versus persistent SNIP was not completely clear in some patients. However, to our best knowledge, this is one of the largest single-center retrospective series of SNIP patients to date.

CONCLUSIONS

According to our data, metachronous sinonasal malignancies were infrequent and sites of origin of non-sinonasal malignancies were similar to the Finnish population. Moreover, patients with SNIP were not prone to HPV-associated non-sinonasal malignancies. Surgical management and instrumentation have clearly advanced over time, and patients presenting with multiple recurrences are rare. Attachment-oriented excision should be the preferred method in the first operation. Patients may benefit from a closer follow-up if there is uncertainty in the meticulousness of the treatment of the tumor attachment site in the first operation.

REFERENCES

1. Krouse JH. Development of a staging system for inverted papilloma. *Laryngoscope*. 2000;110(6):965-968. <https://doi.org/10.1097/00005537-200006000-00015>.
2. Lisan Q, Moya-Plana A, Bonfils P. Association of Krouse classification for sinonasal inverted papilloma with recurrence: a systematic review and meta-analysis. *JAMA Otolaryngol - Head Neck Surg*. 2017;143(11):1104-1110. <https://doi.org/10.1001/jamaoto.2017.1686>.
3. Viitasalo S, Ilmarinen T, Lilja M, et al. HPV-positive status is an independent factor associated with Sinonasal inverted papilloma recurrence. *Laryngoscope*. 2021. <https://doi.org/10.1002/lary.29910>.
4. Gamrot-Wrzoł M, Sowa P, Lisowska G, Ęcierski W, Misiótek M. Risk factors of recurrence and malignant transformation of Sinonasal inverted papilloma. *Biomed Res Int*. 2017;2017:9195163. <https://doi.org/10.1155/2017/9195163>.
5. Peng R, Thamboo A, Choby G, Ma Y, Zhou B, Hwang PH. Outcomes of sinonasal inverted papilloma resection by surgical approach: an updated systematic review and meta-analysis. *Int Forum Allergy Rhinol*. 2019; 9(6):573-581. <https://doi.org/10.1002/alr.22305>.
6. Busquets JM, Hwang PH. Endoscopic resection of sinonasal inverted papilloma: a meta-analysis. *Otolaryngol Head Neck Surg*. 2006;134(3):476-482. <https://doi.org/10.1016/j.otohns.2005.11.038>.
7. Healy DY, Chhabra N, Metson R, Holbrook EH, Gray ST. Surgical risk factors for recurrence of inverted papilloma. *Laryngoscope*. 2016;126(4):796-801. <https://doi.org/10.1002/lary.25663>.
8. Re M, Gioacchini FM, Bajraktari A, et al. Malignant transformation of sinonasal inverted papilloma and related genetic alterations: a systematic review. *Eur Arch Oto-Rhino-Laryngol*. 2017;274(8):2991-3000. <https://doi.org/10.1007/s00405-017-4571-2>.
9. Mirza S, Bradley PJ, Acharya A, Stacey M, Jones NS. Sinonasal inverted papillomas: recurrence, and synchronous and metachronous malignancy. *J Laryngol Otol*. 2007;121(09):857-864. <https://doi.org/10.1017/S002221510700624X>.
10. Ding R, Sun Q, Wang Y. Association between human papilloma virus infection and malignant Sinonasal inverted papilloma. *Laryngoscope*. 2020; 131:lary.29125. <https://doi.org/10.1002/lary.29125>.
11. Anari S, Carrie S. Sinonasal inverted papilloma: Narrative review. *J Laryngol Otol*. 2010;124(7):705-715. <https://doi.org/10.1017/S0022215110000599>.
12. Wang M-J, Noel JE. Etiology of sinonasal inverted papilloma: a narrative review. *World J Otorhinolaryngol - Head Neck Surg*. 2017;3(1):54-58. <https://doi.org/10.1016/J.WJORL.2016.11.004>.
13. Tilastoja ja tutkimusta - Syöpärekisteri. <https://syoparekisteri.fi/>. Accessed May 11, 2021.
14. Landsberg R, Cavell O, Segev Y, Khafif A, Fliss DM. Attachment-oriented endoscopic surgical strategy for sinonasal inverted papilloma. *Am J Rhinol*. 2008;22(6):629-634. <https://doi.org/10.2500/ajr.2008.22.3243>.
15. Pagella F, Pusateri A, Giourgos G, Tinelli C, Matti E. Evolution in the treatment of Sinonasal inverted papilloma: pedicle-oriented endoscopic surgery. *Am J Rhinol Allergy*. 2014;28(1):75-81. <https://doi.org/10.2500/ajra.2014.28.3985>.
16. Adriaensens GFJPM, Lim K-H, Georgalas C, Reinartz SM, Fokkens WJ. Challenges in the Management of Inverted Papilloma: a review of 72 revision cases. *Laryngoscope*. 2016;126(2):322-328. <https://doi.org/10.1002/lary.25522>.
17. Lee JJ, Roland LT, Licata JJ, et al. Morphologic, intraoperative, and histologic risk factors for sinonasal inverted papilloma recurrence. *Laryngoscope*. 2020;130(3):590-596.
18. Safadi A, Yafit D, Abu-Ghanem S, et al. The clinical behavior of sinonasal inverted papilloma with cellular dysplasia: case series and review of the literature. *Eur Arch Oto-Rhino-Laryngol*. 2017;274(9):3375-3382. <https://doi.org/10.1007/s00405-017-4629-1>.
19. Lin GC, Akkina S, Chinn S, et al. Sinonasal inverted papilloma: prognostic factors with emphasis on resection margins. *J Neurol Surgery Part B Skull Base*. 2014;75(2):140-146. <https://doi.org/10.1055/s-0033-1363169>.
20. Kaufman MR, Brandwein MS, Lawson W. Sinonasal Papillomas: Clinicopathologic review of 40 patients with inverted and Oncocytic Schneiderian Papillomas. *Laryngoscope*. 2002;112(8):1372-1377. <https://doi.org/10.1097/00005537-200208000-00009>.
21. Mortuaire G, Arzul E, Darras JA, Chevalier D. Surgical management of sinonasal inverted papillomas through endoscopic approach. *Eur Arch Oto-Rhino-Laryngol*. 2007;264(12):1419-1424. <https://doi.org/10.1007/s00405-007-0401-2>.
22. Nakayama T, Tsunemi Y, Kashiwagi T, et al. Comparison of current staging Systems for Sinonasal Inverted Papilloma. *Am J Rhinol Allergy*. 2021;35(1):64-71.