Journal of Plastic, Reconstructive & Aesthetic Surgery 84 (2023) 147–156

Review

Inferior gluteal artery perforator (IGAP) flap in autologous breast reconstruction: A proportional meta-analysis of surgical outcomes

Jérôme Martineau [a,1], Matteo Scampa [a,1], Juan A. Viscardi [a], Salvatore Giordano [b], Daniel F. Kalbermatten [a], Carlo M. Oranges [a,*]

[a] *Department of Plastic, Reconstructive, and Aesthetic Surgery, Geneva University Hospitals, Geneva University, 1205 Geneva, Switzerland*
[b] *Department of General and Plastic Surgery, Turku University Hospital, University of Turku, 20521 Turku, Finland*

Received 25 January 2023; Accepted 15 May 2023

KEYWORDS
IGAP;
Proportional meta-analysis;
Breast;
Reconstruction

Summary *Background:* The inferior gluteal artery perforator (IGAP) flap is an alternative technique for autologous breast reconstruction. In contrast to other commonly used techniques, there is a paucity of literature on the safety and efficacy of the IGAP flap. The aim of this study was to perform a systematic literature review and meta-analysis of postoperative outcomes and complications associated with the IGAP in autologous breast reconstructions to validate its safety.
Methods: A systematic review of literature was performed following PRISMA guidelines. Articles reporting post-operative outcomes of IGAP flaps in autologous breast reconstruction were included. A proportional meta-analysis of post-operative complications was performed to obtain their proportions with 95% confidence intervals (CIs).
Results: Seven studies met the inclusion criteria, which represented a total of 239 IGAP flaps in 181 patients The total flap loss rate was 3% (95% CI 0–8%), partial flap loss rate was 2% (95% CI 0–4%), haematoma rate was 3% (95% CI 0–7%), overall donor-site complication rate was 15% (95% CI 5–28%), overall recipient-site complication rate was 24% (95% CI 15–34%), and the overall complication rate was 40% (95% CI 23–58%).

* Correspondence to: Department of Plastic, Reconstructive, and Aesthetic Surgery, Geneva University Hospitals, Rue Gabrielle-Perret-Gentil 5, 1205 Geneva, Switzerland.
E-mail address: Carlo.oranges@hcuge.ch (C.M. Oranges).
[1] The two authors contributed equally to the manuscript elaboration.

https://doi.org/10.1016/j.bjps.2023.05.018
1748-6815/© 2023 British Association of Plastic, Reconstructive and Aesthetic Surgeons. Published by Elsevier Ltd.

Conclusions: This meta-analysis provides comprehensive knowledge on the safety and efficacy of the IGAP flap in autologous breast reconstruction. It evidences the IGAP flap in autologous breast reconstruction's overall safety and validates its role as an effective option in breast reconstruction.
© 2023 British Association of Plastic, Reconstructive and Aesthetic Surgeons. Published by Elsevier Ltd.

Contents

Method . . . 148
Search strategy . . . 148
Article selection . . . 149
Data extraction and outcomes definition . . . 149
Statistical analysis . . . 150
Results . . . 150
Discussion . . . 151
Conclusion . . . 154
Funding . . . 154
Ethical approval . . . 154
Declaration of Competing Interest . . . 154
References . . . 154

According to the American Cancer Society, an estimated 287,000 new cases of invasive breast cancer in women will be diagnosed in the United States' states alone in 2022, giving women a lifetime risk of 1 in 8 of having the disease.[1]

Despite being the second leading cause of death for women in the U.S. with more than 43,000 deaths in 2022, breast cancer mortality in women has been consistently declining since the 1980s.[2,3]

Breast cancer diagnosis and its treatment can lead to debilitating symptoms such as chronic pain, fatigue, anxiety, insomnia, impaired body image, and decreased sexual functioning and satisfaction, which results in a significant decrease in self-esteem and quality of life.[4-6]

Breast reconstruction has been found to improve patients' aesthetic satisfaction and quality of life following mastectomy and can be performed immediately or in a delayed fashion.[7-10] Both implant-based and autologous reconstruction techniques can be used in either situation. While technically more challenging and more time-consuming compared to implant-based reconstructions, autologous tissue reconstruction has several advantages, including longer-lasting postoperative results, a more natural breast shape, higher patient satisfaction in the long term, and no need for replacement over time.[9,11-14] Furthermore, in cases where the patient has received radiation therapy, autologous breast reconstruction significantly reduces the risk of reconstructive failure and complications.[15-21]

There are numerous procedures available for autologous breast reconstruction nowadays, but the deep inferior epigastric perforator (DIEP) flap remains the gold standard flap for most plastic surgeons.[22-25] However, the DIEP flap is not appropriate for every patient requiring breast reconstruction, typically due to limited abdominal tissue, past abdominal surgical procedures, donor site scar acceptance, or patient desire.

If abdominal flaps are not suitable, other reconstructive options include thigh-based flaps such as the profunda artery perforator (PAP) and the transverse myocutaneous gracilis (TMG), and buttock-based flaps such as the inferior gluteal artery perforator (IGAP) or superior gluteal artery perforator (SGAP).

Allen and Tucker described the superior gluteal artery perforator (SGAP) flap for breast reconstruction in 1995.[26] In the years that followed, Higgins et al. in 2002 and Guerra et al. in 2004 both used the inferior gluteal artery perforator (IGAP) flap for the repair of ischial pressure sores and consecutively for breast reconstruction.[27,28]

The current literature on the use of the IGAP is extensive, however information on outcomes is limited. The purpose of this study was to conduct a systematic review and meta-analysis of the literature on the IGAP flap and its outcomes in terms of safety and reliability of postoperative outcomes in breast reconstruction.

Method

PRISMA guidelines for reporting study results were followed. Our systematic review and meta-analysis study protocol was prospectively registered on PROSPERO (registration ID: CRD42022376927).

Search strategy

The review question was defined using the PICO principles: Evaluate the safety and efficacy of the IGAP flap in

Table 1 Search strategy.

Database	Date	Search query	N articles
Pubmed	18th Nov	(("Mammaplasty"[Mesh]) OR (Breast reconstruction)) AND ((IGAP) OR (Gluteal perforator) OR (Inferior Gluteal perforator) OR (gluteal flap))	207
Embase, MEDLINE, Preprints	18th Nov	('breast reconstruction'/exp OR 'breast reconstruction') AND ('inferior gluteal artery perforator flap' OR 'gluteal flap' OR 'gluteal perforator')	74
Web of Science	18th Nov	((ALL=(breast reconstruction)) OR ALL= (mammaplasty)) AND ((((ALL=(Igap)) OR ALL= (inferior gluteal artery perforator)) OR ALL= (gluteal flap)) OR ALL= (gluteal perforator))	245
Cochrane library	18th Nov	ID search hits #1MeSH descriptor: [Mammaplasty] explode all trees #2(breast reconstruction):ti,ab,kw #3(IGAP):ti,ab,kw OR ("inferior gluteal artery perforator"):ti,ab,kw OR (Gluteal flap):ti,ab,kw OR (inferior gluteal perforator):ti,ab,kw #4(#1 OR #2) AND #3	5

autologous breast reconstruction in terms of postoperative outcomes. To answer this question, a systematic review of PubMed, Embase/MEDLINE/Preprint, Web of Science and Cochrane Library was conducted on November 18, 2022. A combination of Mesh terms and keywords synonyms of "breast reconstruction", "Inferior Gluteal Artery Perforator", linked with Booleans operators were used to develop a search strategy (Table 1).

Article selection

Inclusion and exclusion criteria were defined using the PICOS principles before starting the review process (Table 2). We sought to include studies of patients who benefited from breast reconstruction and excluded animal and cadaveric studies. To be considered for inclusion, the flap had to be an IGAP flap. Studies on bilateral flap reconstruction procedures were included. All other gluteal flaps, that were not inferior gluteal artery perforator based, such as the superior gluteal artery perforator (SGAP) flap or the fasciocutaneous infragluteal (FCI) free flap were excluded. The main outcome had to be reported in all selected articles. As we aimed at assessing safety and efficacy of the procedure, total flap failure rate was selected as the primary study outcome. Definition was complete flap loss, or reconstructive failure. Studies reporting surgical outcomes in a prospective and retrospective fashion were included. While we decided to include cases series, case reports were excluded. Systematic reviews, meta-analysis, reviews, letters and congress abstracts were also excluded. No language or publication restriction date were applied.

Articles retrieved from the search query were processed through Rayyan (https://www.rayyan.ai/; accessed on 21 November 2022) to allow independent, blind screening by 2 authors (J.M.; M.S.).[29] Articles were first screened by title and abstract, and in case of a divergent opinion, it was solved after consultation with the senior author (C.M.O.). Selected articles were then fully read by the 2 authors and if they matched selection criteria, they were incorporated in a standardised spreadsheet file.

Data extraction and outcomes definition

Data on studies characteristics and clinical outcomes were then independently collected and included in an Excel file (version 16.30, Microsoft Corp., Redmond, WA, USA) by the 2 authors (J.M.; M.S.) and results were compared to detect potential reporting errors. Demographic variables, main outcome and secondary outcomes were recorded – the main outcome being total flap failure rate, and secondary outcomes being post-operative complications reported in the articles. To be considered for inclusion in the meta-analysis a complication had to be reported in 3 or more articles, otherwise they would only be described in the results section. Complications were reported on a per-flap basis. Furthermore, overall complication rate was computed by adding all complications reported, and further subdivided in donor site and recipient site complications rates.

Table 2 Selection criterion.

PICOS	Inclusion	Exclusion
Population	Adult with breast reconstruction	Cadaver, Animal
Intervention	IGAP	Other flaps
Comparator	Not applicable	
Outcomes	Primary: Total flap loss rate. Secondary: Post-operative complications	If primary outcome not reported
Studies	Prospective, Retrospective, Comparative, case series.	Reviews, meta-analysis, letters, abstracts only, case reports.

Statistical analysis

Data was processed for proportional meta-analysis using R software version 4.2.1 (R Foundation for Statistical Computing, Vienna, Austria) and its meta-package.[30] A random effect DerSimonian-Laird model was used to obtain pooled complication rates. Heterogeneity between studies was evaluated with the I^2 statistic along with the Q-statistic p-value, with I^2 with values below 30% considered as low heterogeneity and over 70% as significant heterogeneity.[31] Results are presented as forest plots with proportions and their 95% Confidence Intervals (CI).

Results

A total of 531 studies were identified through the initial database query (Figure 1). After excluding duplicates and screening titles and abstracts, 19 articles were fully read, yielding a total of 7 studies that fully met the inclusion criteria.[32-38] A total of 239 IGAP procedures were performed in 181 patients. Clinical characteristics of the included studies are detailed in Table 3. All studies were of retrospective nature, except for Beshlian et al. that included prospective data after December 2006.[33] All studies cohort included surgical procedures conducted after the year 2001 and were of monocentric nature, apart from one study that was conducted across 2 major medical centres.[34] All studies focused primarily on IGAP, except for Jandali et al. where the primary aim was to test patency with venous coupler in different free flaps for breast reconstruction. Even if the primary aim was not the assessment of post-operative outcomes of the IGAP, its failure rate was reported, allowing for inclusion of the study. However, no specific details on Jandali et al. study population were available.

Mean patient age ranged from 35.7 to 50 years across selected studies. Mean BMI ranged from 20.8 to 24 kg/m^2.[33,35-38]

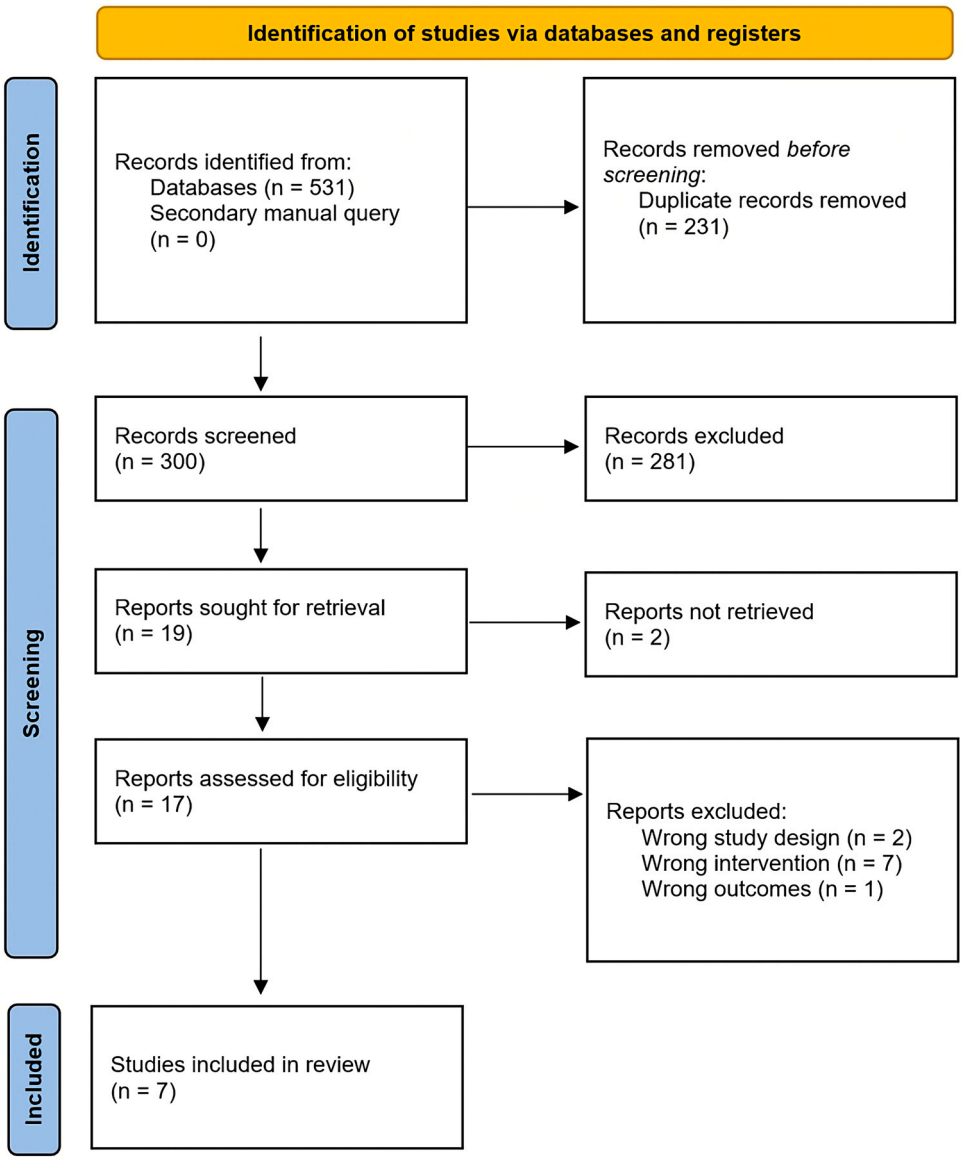

Figure 1 PRISMA flow-chart.

Table 3 Characteristics of the included studies.

Reference	Study design	Study period	Patients	Flaps	Mean age	Mean BMI [kg/m^2] (SD or range)	Reconstruction timing	Mean flap weight
Allen RJ 2006[32]	Retrospective	March-December 2004	31	31	49.4 (33-61)	NS	16 Immediate, 15 delayed	407 g (137-806)
Beshlian KM 2008[33]	Retrospective before December 2006-prospective after	July 2001- March 2007	14	19	45.1 (36-61)	22.8 (18.6-29.3)	6 immediate 13 delayed	NS
Levine JL 2009[35]	Retrospective	January 2005-December 2007	22	44	43 (33-56)	24 (19-30)	19 immediate, 25 delayed	Bilateral 366 g (174-684)
Jandali S 2010[34]	Retrospective	July 2002 - July 2008	5	5	NS	NS	NS	NS
Mirzabeigi MN 2011[36]	Retrospective	August 2005 - October 2010	24	31	50 (10.6)	23.5 (3.1)	15 immediate, 16 delayed	NS
Satake T 2015*#[38]	Retrospective	June 2007- March 2010	22	22	NS	20.8 (2.5)	20 Immediate, 2 Delayed	244.3 g (114-380)
Satake T 2015*§[38]	Retrospective	November 2007 - December 2012	20	40	35,7 (24-48)	21.3 (2.8)	13 Immediate, 7 Delayed	231.2 g (142-397)
Murphy DC 2022[37]	Retrospective	September 2008 - December 2016	43	47	47 (7.1)	22 (2.2)	14 Immediate, 29 Delayed	335 (95%CI 305-370)

*Data reported separately for #unilateral and §bilateral IGAP / NS: Not specified.

When reported, the mean operative times ranged from 318 to 671.1 min.[32,33,35,36,38] Mean flap weights varied between 244.3 and 407 g, including unilateral and bilateral flaps.[32,35,37,38]

Total flap loss was reported in all the studies, and the pooled total flap loss rate was 3% (95% CI: 0-8%) (Figure 2).[32-38] Six studies reported on partial flap loss, with a pooled partial flap loss rate of 2% (95% CI: 0-4%).[32,33,35-38] Haematoma rate was described in 6 studies, resulting in a pooled rate of 3% (95% CI: 0-7%).[32,33,35-38] Six studies reported the seroma rate, with a pooled rate of 9% (95% CI: 0-23%).[32,33,35-38] Wound dehiscence rate was disclosed in 6 studies and the pooled rate was 7% (95% CI: 2-14%).[32,33,35-38] Infection rate was reported in 6 studies, and the pooled rate was 1% (95% CI: 0-5%).[32,33,35-38] Details on the site of complications are disclosed in Table 4. Fat necrosis was reported in 6 studies, with a pooled rate of 2% (95% CI: 0-6%).[32,33,35-38] Donor-site complications were reported in 6 studies, and the pooled donor-site complication rate was 15% (95% CI: 5-28%) (Figure 3).[32,33,35-38] The recipient-site complication rate (Figure 4) and overall complication rate (Figure 5) reported in 6 studies, were 24% (95% CI: 15-34%) and 40% (95% CI: 23-58%) respectively.[32,33,35-38] Significant heterogeneity across studies ($I2 > 70\%$) was observed for in the seroma rate, the donor-site complication rate, and the overall complication rate.

Satake et al. reported other recipient-site complications that were not described in other studies, with partial nipple-areola-complex necrosis and hypertrophic scaring each occurring in 2 cases (3.2%). Sensory complaints at the donor site were reported in 7 patients (11.3%) in Satake et al. study and in 7 patients (23%) in Mirzabeigi et al. study. Paraesthesia at the donor site was reported in 1 case (2.2%) in Levine et al. study, while Satake et al. described the presence of paraesthesia in 3 cases out of 20 cases of bilateral IGAP flap reconstruction.

Discussion

To the best of our knowledge, this study is the first systematic review and proportional meta-analysis evaluating surgical outcomes of the IGAP flap.

The IGAP total failure rate and partial failure rate were 3% and 2%, respectively. This rate remains comparable to other buttock and thigh flaps used in autologous breast reconstruction. A recent analysis on safety and efficacy of the SGAP flap showed pooled total and partial flap failure rates both at 1%.[39] Similarly, in thigh-based flaps - Qian et al. reported a pooled total flap loss rate of 1% and partial necrosis rate of 2% in their meta-analysis of the PAP flap, and a 2% pooled flap failure rate was reported by Siegwart et al. in their review of the TMG flap.[40,41] A large retrospective review of 265 PAP flaps by Haddock et al. describes a 3% flap loss rate.[42] Another systematic review of the lumbar artery perforator (LAP) flap reported total and partial flap loss rates of 2.6% and 7.6%.[43] A further safe alternative is the fascio-cutaneous infra-gluteal (FCI) flap with less than 1% flap failures described in 2 large studies.[44,45] Large retrospective series of breast reconstruction with abdominally based flaps describe total flap failure rates ranging from 0.5% to 1.1% and partial flap loss rates ranging from 1.4% to 2.5%.[46-50]

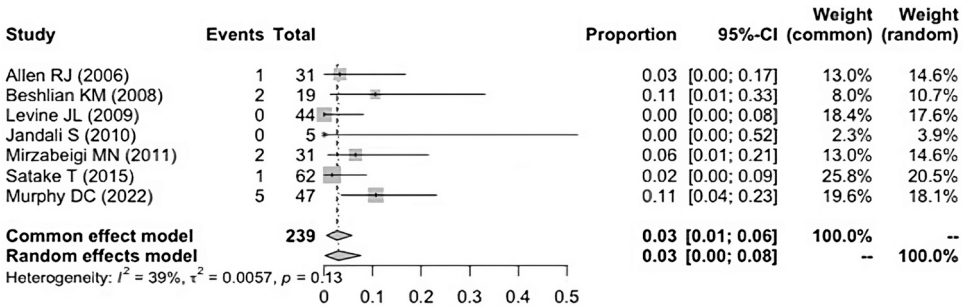

Figure 2 Forest plot of pooled IGAP total flap loss rate.[32–38]

Table 4 Site of complication for seroma, wound infection, and wound dehiscence.

	Gluteal donor-site *n = 234*	Breast recipient site *n = 234*
Seroma	21 (9.0%)	6 (2.6%)
Wound Infection	3 (1.3%)	3 (1.3%)
Wound dehiscence	10 (4.3%)	7 (3.0%)

In the present meta-analysis, significant heterogeneity was evidenced in seroma rate, donor-site complication rate, and overall complication rate – that may be explained by a lack of standardisation in the reporting and definition of surgical complications and outcomes. It could also be explained by differences in surgeons experience with IGAP across different centres, with 2 included studies reporting the lowest complication rate coming from a centre that first described and previously studied the IGAP flap.[32,35] The pooled donor-site complication rate of 15% (95% CI: 5–28%) was similar to those reported in abdominally based flaps, thigh based flaps, and the SGAP flap.[39–42,46,47,51]

The pooled overall complication rate was 40%, comparable to the 36% overall complication rate reported in a SGAP flap meta-analysis, and the 38.9% rate reported in studies on the FCI flap.[39,44] However, it remains higher than the 23% rate of PAP flaps, and higher than the 30% rate reported by Gill et al. in their study of DIEP flaps.[41,47] Beshlian et al. noted that while complications with the IGAP flaps are frequent, they often resolve without the need for surgical intervention with only 2 surgical revisions for 8 complications out of 19 flaps.[33] Noteworthily, the IGAP pooled fat necrosis rate was low at 2%, testifying the reliability of the flap perfusion, and favourably comparing to fat necrosis rates (10.4–12.9%) reported in large retrospective studies evaluating DIEP flap breast reconstruction.[47,50]

Indeed, the IGAP vascular anatomy was described as reliable, with an adequate pedicle size, which varied across studies. Murphy et al. describe a median pedicle size of

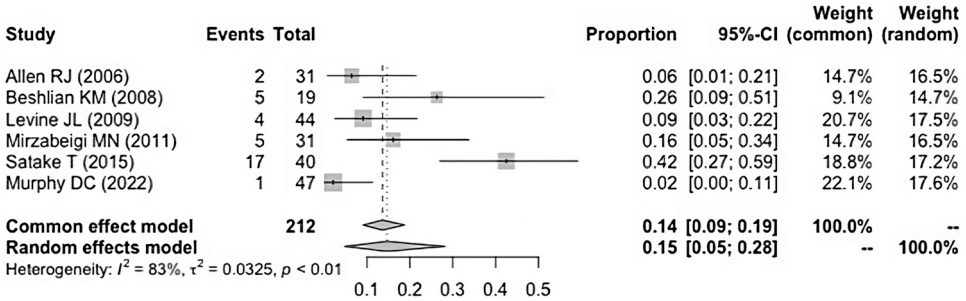

Figure 3 Forest plot of pooled IGAP donor site complication rate.[32,33,35–38]

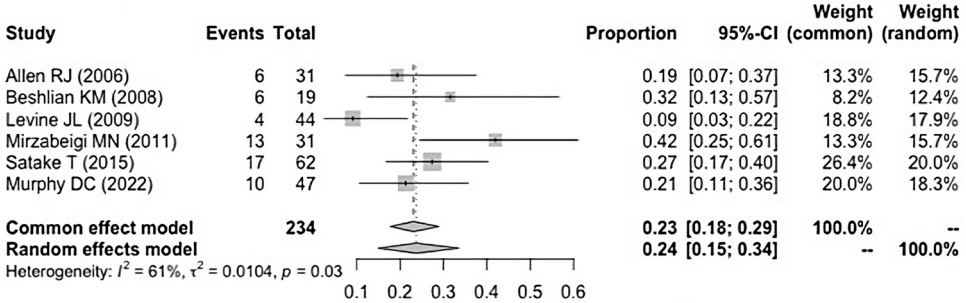

Figure 4 Forest plot of pooled IGAP recipient site complication rate.[32,33,35–38]

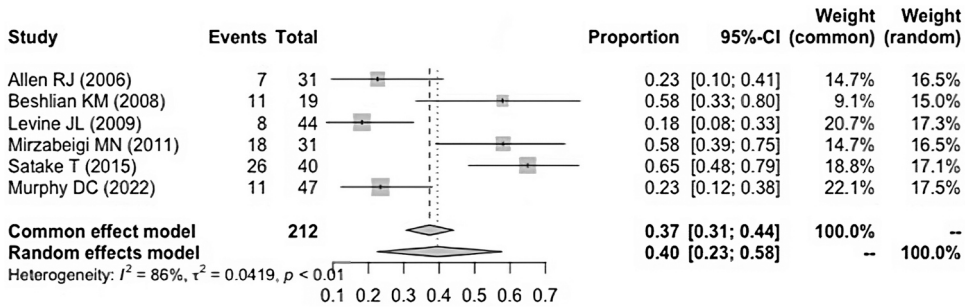

Figure 5 Forest plot of pooled IGAP overall complication rate.[32,33,35-38]

7 cm (range: 6- 9 cm), Satake et al. report an average pedicle length of 4.6 cm (range: 3-6.2 cm) and an average artery diameter of 1.4 mm (0.6-2.5 mm) while Allen et al. mention that the typical pedicle length ranges between 8 and 12 cm with an arterial diameter of more than 2 mm.[32,37,38] Variance in pedicle length and diameter across studies may be explained by differences in desired pedicle length and differences in patient's BMI. Extension of dissection influences the length and diameter of the flap pedicle, with the caveat that deeper dissection increases operative difficulty and risk. Furthermore, the IGAP pedicle length can be increased by favouring lateral perforators.[32,52] According to Levine et al. the IGAP flap offers a more satisfactory pedicle length compared to the SGAP.[35] The FCI flap provides comparable results to the SGAP and IGAP flaps, using a similar donor site but based on the vascular pedicle that accompanies the posterior femoral cutaneous nerve. The posterior femoral cutaneous pedicle is consistent and allows for greater lengths of up to 18 cm.[44] Furthermore, it has the added benefit of avoiding intramuscular dissection, resulting in a less challenging surgery compared to the IGAP flap.

Use of preoperative imaging was reported inconsistently across studies - Murphy et al. and Satake et al. report the use of 3D computed tomography angiography (CTA) in the preoperative setting, while Mirzabeigi et al. note that while they do not routinely use it in breast reconstruction with abdominal flaps, they often use preoperative CTA or magnetic resonance angiography for gluteal flaps.[36-38]

Drawbacks highlighted by most authors include a technically demanding dissection and the necessity of position change.[33,36-38] Some authors also mention vessel size mismatch as a disadvantage, that they address by exercising more caution when dissecting proximally, aiming to harvest smaller calibre veins to match recipient internal mammary vein.[36,38] Another pitfall reported by authors is sensory complaints in the posterior thigh region by patients following reconstruction that is a consequence of dissection and manipulation of the posterior femoral cutaneous nerve during surgery - although the symptoms were usually self-limiting and resolved without intervention.[35,36,38]

Two of the included studies in this meta-analysis were of comparative nature.[36,37] Murphy et al. compared the outcomes following breast reconstruction with IGAP and PAP flaps and found that there were significantly more complications and revision surgeries in patients undergoing reconstruction with an IGAP flap.[37] They argue that the harvest and inset is more difficult with the IGAP flap due to a shorter pedicle, a smaller pedicle diameter and firmer fat.[37] Mirzabeigi et al. compared IGAP to DIEP and found that vascular complications were significantly more frequent in patients who underwent breast reconstruction with an IGAP flap.[36] They explain this phenomenon by the technical difficulty of the IGAP flap and its role in tertiary free flap breast reconstruction.[36] Nevertheless, they state that they consider the IGAP flap as an excellent alternative option in patients unsuitable for abdominally based flap reconstruction.[36]

All authors consider the IGAP flap as a second-line option for autologous breast reconstruction in patients with an inadequate abdominal donor site, in patients with previous abdominal surgeries or in patients preferring a gluteal based flap.[32,33,35-38]

Regarding aesthetic outcomes, authors report that most patients are satisfied. Interestingly, Allen et al. note that when asked where excess tissue might be removed, many women with excess buttock tissue will indicate the lower portion of the buttocks.[32] Similarly, authors highlight the added aesthetic benefit of correcting a saddlebag deformity when performing an IGAP flap.[32,35,36,53] Another aesthetic advantage over abdominally based flap reconstruction is the high fat-to-skin ratio and density of the IGAP flap, allowing for good breast projection.[36-38] Authors suggest that IGAP flap reconstruction offers better aesthetic results at the donor-site compared to SGAP flap reconstruction, due to its scar being located in the inferior buttock crease, making it less visible when nude. In contrast, SGAP flap scars are more prominent when not wearing underwear/bikini.[35] Another major advantage of the IGAP flap compared to the SGAP flap is a better donor site appearance, with no depression in the superior part of the buttock and thus less disturbance of the superior fullness.[35,36] Levine et al. investigated patient satisfaction after bilateral IGAP flap breast reconstruction.[35] Patients rated their buttock scar as satisfactory and their breast scar as good, and the buttock contour as somewhere between satisfactory and good. 72% of the surveyed patients indicated that they would undergo the same procedure again, while 14% stated they would have chosen the SGAP flap instead due to better coverage of the scar with a bathing suit. [35]

Revision procedures at the donor site varied across studies, with Mirzabeigi et al. reporting that 39% of patients required local tissue rearrangement at the donor site, Murphy et al. noted a 17% donor site revision rate.[36,37] In contrast, Satake et al. report that only 5% of their patients underwent donor-site touch-up surgery procedures.[38] They hypothesise that the fact they used 2 IGAP flaps in unilateral

breast reconstruction may have reduced donor-site aesthetic complications.[38] Similarly, revision procedures at the breast in Mirzabeigi et al. study were relatively high, with 31% of patients undergoing a local tissue rearrangement, compared to 10.5% in Satake et al. study.[36,38]

This meta-analysis offers interesting insights. It indicates that the IGAP flap is safe in autologous breast reconstruction, with total and partial flap loss rates that are similar to other alternatives. While thigh-based flaps have grown in popularity over the last decade and have gradually replaced gluteal free flaps as a second-line option, the IGAP flap remains a valuable option for autologous breast reconstruction in patients with an inadequate abdominal donor site.[54,55]

However, several limitations must be considered in this meta-analysis. The sample size was limited, and significant heterogeneity was evidenced in some of the analysed outcomes. Most of the included studies in this meta-analysis did not include objective and subjective assessments of the aesthetic results and overall patient satisfaction. Additionally, comparison between different flaps was performed using other proportional meta-analysis and retrospective studies. Further large comparative studies are required to draw definitive conclusions.

Conclusion

This meta-analysis provides comprehensive knowledge of surgical outcomes and complications of the IGAP flap. It demonstrates that it is both a safe and effective technique for autologous breast reconstruction.

Funding

None.

Ethical approval

Not required.

Declaration of Competing Interest

None.

References

1 American Cancer Society. *Cancer facts & statistics*. ⟨http://cancerstatisticscenter.cancer.org/⟩ [Accessed 4 January 2023].
2 *Cancer of the breast (female) - cancer stat facts*. SEER. ⟨https://seer.cancer.gov/statfacts/html/breast.html⟩ [Accessed 4 January 2023].
3 Hendrick RE, Helvie MA, Monticciolo DL. Breast cancer mortality rates have stopped declining in U.S. women younger than 40 years. *Radiology* 2021;**299**(1):143–9. https://doi.org/10.1148/radiol.2021203476.
4 Montazeri A, Vahdaninia M, Harirchi I, Ebrahimi M, Khaleghi F, Jarvandi S. Quality of life in patients with breast cancer before and after diagnosis: an eighteen months follow-up study. *BMC Cancer* 2008;**8**(1):330. https://doi.org/10.1186/1471-2407-8-330.
5 Karakoyun-Celik O, Gorken I, Sahin S, Orcin E, Alanyali H, Kinay M. Depression and anxiety levels in woman under follow-up for breast cancer: relationship to coping with cancer and quality of life. *Med Oncol* 2010;**27**(1):108–13. https://doi.org/10.1007/s12032-009-9181-4.
6 Hamer J, McDonald R, Zhang L, et al. Quality of life (QOL) and symptom burden (SB) in patients with breast cancer. *Support Care Cancer J Multinatl Assoc Support Care Cancer* 2017;**25**(2):409–19. https://doi.org/10.1007/s00520-016-3417-6.
7 Eltahir Y, Werners LLCH, Dreise MM, et al. Quality-of-life outcomes between mastectomy alone and breast reconstruction: comparison of patient-reported BREAST-Q and other health-related quality-of-life measures. *Plast Reconstr Surg* 2013;**132**(2):201e–9e. https://doi.org/10.1097/PRS.0b013e31829586a7.
8 Eltahir Y, Werners LLCH, Dreise MM, Zeijlmans van Emmichoven IA, Werker PMN, de Bock GH. Which breast is the best? Successful autologous or alloplastic breast reconstruction: patient-reported quality-of-life outcomes. *Plast Reconstr Surg* 2015;**135**(1):43–50. https://doi.org/10.1097/PRS.0000000000000804.
9 Hu ES, Pusic AL, Waljee JF, et al. Patient-reported aesthetic satisfaction with breast reconstruction during the long-term survivorship Period. *Plast Reconstr Surg* 2009;**124**(1):1–8. https://doi.org/10.1097/PRS.0b013e3181ab10b2.
10 Jeevan R, Cromwell DA, Browne JP, et al. Findings of a national comparative audit of mastectomy and breast reconstruction surgery in England. *J Plast Reconstr Aesthet Surg* 2014;**67**(10):1333–44. https://doi.org/10.1016/j.bjps.2014.04.022.
11 Pirro O, Mestak O, Vindigni V, et al. Comparison of patient-reported outcomes after implant versus autologous tissue breast reconstruction using the BREAST-Q. *Plast Reconstr Surg Glob Open* 2017;**5**(1):e1217. https://doi.org/10.1097/GOX.0000000000001217.
12 Toyserkani NM, Jørgensen MG, Tabatabaeifar S, Damsgaard T, Sørensen JA. Autologous versus implant-based breast reconstruction: a systematic review and meta-analysis of Breast-Q patient-reported outcomes. *J Plast Reconstr Aesthet Surg* 2020;**73**(2):278–85. https://doi.org/10.1016/j.bjps.2019.09.040.
13 Pusic AL, Matros E, Fine N, et al. Patient-reported outcomes 1 year after immediate breast reconstruction: results of the mastectomy reconstruction outcomes consortium study. *J Clin Oncol J Am Soc Clin Oncol* 2017;**35**(22):2499–506. https://doi.org/10.1200/JCO.2016.69.9561.
14 Yueh JH, Slavin SA, Adesiyun T, et al. Patient satisfaction in postmastectomy breast reconstruction: a comparative evaluation of DIEP, TRAM, latissimus flap, and implant techniques. *Plast Reconstr Surg* 2010;**125**(6):1585–95. https://doi.org/10.1097/PRS.0b013e3181cb6351.
15 Billig J, Jagsi R, Qi J, et al. Should immediate autologous breast reconstruction be considered in women who require post-mastectomy radiation therapy? A prospective analysis of outcomes. *Plast Reconstr Surg* 2017;**139**(6):1279–88. https://doi.org/10.1097/PRS.0000000000003331.
16 Fischer JP, Basta MN, Shubinets V, Serletti JM, Fosnot J. A systematic meta-analysis of prosthetic-based breast reconstruction in irradiated fields with or without autologous muscle flap coverage. *Ann Plast Surg* 2016;**77**(1):129–34. https://doi.org/10.1097/SAP.0000000000000288.
17 Clemens MW, Kronowitz SJ. Current perspectives on radiation therapy in autologous and prosthetic breast reconstruction.

Gland Surg 2015;**4**(3):222–31. https://doi.org/10.3978/j.issn.2227-684X.2015.04.03.
18 Lee KT, Mun GH. Prosthetic breast reconstruction in previously irradiated breasts: a meta-analysis. *J Surg Oncol* 2015;**112**(5):468–75. https://doi.org/10.1002/jso.24032.
19 Nelson JA, Disa JJ. Breast reconstruction and radiation therapy: an update. *Plast Reconstr Surg* 2017;**140**:60S–8S. https://doi.org/10.1097/PRS.0000000000003943. (5S Advances in Breast Reconstruction).
20 Lemaine V, Schilz SR, Van Houten HK, Zhu L, Habermann EB, Boughey JC. Autologous breast reconstruction versus implant-based reconstruction: how do long-term costs and health care use compare? *Plast Reconstr Surg* 2020;**145**(2):303–11. https://doi.org/10.1097/PRS.0000000000006422.
21 Matros E, Albornoz CR, Razdan SN, et al. Cost-effectiveness analysis of implants versus autologous perforator flaps using the BREAST-Q. *Plast Reconstr Surg* 2015;**135**(4):937–46. https://doi.org/10.1097/PRS.0000000000001134.
22 Lee BT, Agarwal JP, Ascherman JA, et al. Evidence-based clinical practice guideline: autologous breast reconstruction with DIEP or pedicled TRAM abdominal flaps. *Plast Reconstr Surg* 2017;**140**(5):651e. https://doi.org/10.1097/PRS.0000000000003768.
23 Hofer SOP, Damen THC, Mureau MAM, Rakhorst HA, Roche NA. A critical review of perioperative complications in 175 free deep inferior epigastric perforator flap breast reconstructions. *Ann Plast Surg* 2007;**59**(2):137. https://doi.org/10.1097/01.sap.0000253326.85829.45.
24 Macadam SA, Zhong T, Weichman K, et al. Quality of life and patient-reported outcomes in breast cancer survivors: a multicenter comparison of four abdominally based autologous reconstruction methods. *Plast Reconstr Surg* 2016;**137**(3):758. https://doi.org/10.1097/01.prs.0000479932.11170.8f.
25 Erdmann-Sager J, Wilkins EG, Pusic AL, et al. Complications and patient-reported outcomes after abdominally based breast reconstruction: results of the mastectomy reconstruction outcomes consortium study. *Plast Reconstr Surg* 2018;**141**(2):271. https://doi.org/10.1097/PRS.0000000000004016.
26 Allen RJ, Tucker C. Superior gluteal artery perforator free flap for breast reconstruction. *Plast Reconstr Surg* 1995;**95**(7):1207–12. https://doi.org/10.1097/00006534-199506000-00010.
27 Higgins JP, Orlando GS, Blondeel PN. Ischial pressure sore reconstruction using an inferior gluteal artery perforator (IGAP) flap. *Br J Plast Surg* 2002;**55**(1):83–5. https://doi.org/10.1054/bjps.2001.3713.
28 Guerra AB, Metzinger SE, Bidros RS, Gill PS, Dupin CL, Allen RJ. Breast reconstruction with gluteal artery perforator (GAP) flaps: a critical analysis of 142 cases. *Ann Plast Surg* 2004;**52**(2):118. https://doi.org/10.1097/01.sap.0000095437.43805.d1.
29 Ouzzani M, Hammady H, Fedorowicz Z, Elmagarmid A. Rayyan-a web and mobile app for systematic reviews. *Syst Rev* 2016;**5**(1):210. https://doi.org/10.1186/s13643-016-0384-4.
30 Wang N. *How to conduct a meta-analysis of proportions in R: a comprehensive tutorial*; 2018. DOI: ⟨10.13140/RG.2.2.27199.00161⟩.
31 Higgins JPT, Thompson SG. Quantifying heterogeneity in a meta-analysis. *Stat Med* 2002;**21**(11):1539–58. https://doi.org/10.1002/sim.1186.
32 Allen RJ, Levine JL, Granzow JW. The in-the-crease inferior gluteal artery perforator flap for breast reconstruction. *Plast Reconstr Surg* 2006;**118**(2):333–9. https://doi.org/10.1097/01.prs.0000227665.56703.a8.
33 Beshlian KM, Paige KT. Inferior gluteal artery perforator flap breast reconstruction. *Am J Surg* 2008;**195**(5):651–3. https://doi.org/10.1016/j.amjsurg.2007.12.041.
34 Jandali S, Wu LC, Vega SJ, Kovach SJ, Serletti JM. 1000 consecutive venous anastomoses using the microvascular anastomotic coupler in breast reconstruction. *Plast Reconstr Surg* 2010;**125**(3):792–8. https://doi.org/10.1097/PRS.0b013e3181cb636d.
35 Levine JL, Miller Q, Vasile J, et al. Simultaneous bilateral breast reconstruction with in-the-crease inferior gluteal artery perforator flaps. *Ann Plast Surg* 2009;**63**(3):249–54. https://doi.org/10.1097/SAP.0b013e31818c4ace.
36 Mirzabeigi MN, Au A, Jandali S, Natoli N, Sbitany H, Serletti JM. Trials and tribulations with the inferior gluteal artery perforator flap in autologous breast reconstruction. *Plast Reconstr Surg* 2011;**128**(6):614e–24e. https://doi.org/10.1097/PRS.0b013e318230c2d8.
37 Murphy DC, Razzano S, Wade RG, Haywood RM, Figus A. Inferior gluteal artery perforator (IGAP) flap versus profunda artery perforator (PAP) flap as an alternative option for free autologous breast reconstruction. *J Plast Reconstr Aesthet Surg JPRAS* 2022;**75**(3):1100–7. https://doi.org/10.1016/j.bjps.2021.09.043.
38 Satake T, Muto M, Ogawa M, et al. Unilateral breast reconstruction using bilateral inferior gluteal artery perforator flaps. *Plast Reconstr Surg Glob Open* 2015;**3**(3):e314. https://doi.org/10.1097/GOX.0000000000000287.
39 Martineau J, Kalbermatten DF, Oranges CM. Safety and efficacy of the superior gluteal artery perforator (SGAP) flap in autologous breast reconstruction: systematic review and meta-analysis. *Cancers* 2022;**14**(18):4420. https://doi.org/10.3390/cancers14184420.
40 Siegwart LC, Bolbos A, Tapking C, et al. Safety and donor site morbidity of the transverse musculocutaneous gracilis (TMG) flap in autologous breast reconstruction—a systematic review and meta-analysis. *J Surg Oncol* 2021;**124**(4):492–509. https://doi.org/10.1002/jso.26559.
41 Qian B, Xiong L, Li J, et al. A systematic review and meta-analysis on microsurgical safety and efficacy of profunda artery perforator flap in breast reconstruction. *J Oncol* 2019;**2019**:9506720. https://doi.org/10.1155/2019/9506720.
42 Haddock NT, Teotia SS. Consecutive 265 profunda artery perforator flaps: refinements, satisfaction, and functional outcomes. *Plast Reconstr Surg Glob Open* 2020;**8**(4):e2682. https://doi.org/10.1097/GOX.0000000000002682.
43 Vonu PM, Chopan M, Sayadi L, Chim HW, Leyngold M. Lumbar artery perforator flaps: a systematic review of free tissue transfers and anatomical characteristics. *Ann Plast Surg* 2022;**89**(4):465–71. https://doi.org/10.1097/SAP.0000000000003216.
44 Struckmann V, Peek A, Wingenbach O, Harhaus L, Kneser U, Holle G. The free fasciocutaneous infragluteal (FCI) flap: Outcome and patient satisfaction after 142 breast reconstructions. *J Plast Reconstr Aesthet Surg JPRAS* 2016;**69**(4):461–9. https://doi.org/10.1016/j.bjps.2015.12.010.
45 Papp C, Windhofer C, Gruber S. Breast reconstruction with the fasciocutaneous infragluteal free flap (FCI). *Ann Plast Surg* 2007;**58**(2):131–6. https://doi.org/10.1097/01.sap.0000237635.05337.a1.
46 Chang DW, Wang B, Robb GL, et al. Effect of obesity on flap and donor-site complications in free transverse rectus abdominis myocutaneous flap breast reconstruction. *Plast Reconstr Surg* 2000;**105**(5):1640–8. https://doi.org/10.1097/00006534-200004050-00007.
47 Gill PS, Hunt JP, Guerra AB, et al. A 10-year retrospective review of 758 DIEP flaps for breast reconstruction. *Plast Reconstr Surg* 2004;**113**(4):1153–60. https://doi.org/10.1097/01.prs.0000110328.47206.50.
48 He WY, El Eter L, Yesantharao P, et al. Complications and patient-reported outcomes after TRAM and DIEP flaps: a systematic review and meta-analysis. *Plast Reconstr Surg Glob Open* 2020;**8**(10):e3120. https://doi.org/10.1097/GOX.0000000000003120.

49 Knox ADC, Ho AL, Leung L, et al. Comparison of outcomes following autologous breast reconstruction using the DIEP and pedicled TRAM flaps: a 12-year clinical retrospective study and literature review. *Plast Reconstr Surg* 2016;**138**(1):16. https://doi.org/10.1097/PRS.0000000000001747.

50 Ochoa O, Chrysopoulo M, Nastala C, Ledoux P, Pisano S. Abdominal wall stability and flap complications after deep inferior epigastric perforator flap breast reconstruction: does body mass index make a difference? Analysis of 418 patients and 639 flaps. *Plast Reconstr Surg* 2012;**130**(1):21e–33e. https://doi.org/10.1097/PRS.0b013e3182547d09.

51 Weitgasser L, Mahrhofer M, Schwaiger K, et al. Lessons learned from 30 years of transverse myocutaneous gracilis flap breast reconstruction: historical appraisal and review of the present literature and 300 cases. *J Clin Med* 2021;**10**(16):3629. https://doi.org/10.3390/jcm10163629.

52 Georgantopoulou A, Papadodima S, Vlachodimitropoulos D, Goutas N, Spiliopoulou C, Papadopoulos O. The microvascular anatomy of superior and inferior gluteal artery perforator (SGAP and IGAP) flaps: a fresh cadaveric study and clinical implications. *Aesthet Plast Surg* 2014;**38**(6):1156–63. https://doi.org/10.1007/s00266-014-0398-z.

53 LoTempio MM, Allen RJ. Breast reconstruction with SGAP and IGAP flaps. *Plast Reconstr Surg* 2010;**126**(2):393–401. https://doi.org/10.1097/PRS.0b013e3181de236a.

54 Myers PL, Nelson JA, Allen Jr RJ. Alternative flaps in autologous breast reconstruction. 44459-44459 *Gland Surg* 2021;**10**(1). https://doi.org/10.21037/gs.2020.03.16.

55 Healy C, Allen RJ. The evolution of perforator flap breast reconstruction: twenty years after the first DIEP flap. *J Reconstr Microsurg* 2014;**30**(2):121–5. https://doi.org/10.1055/s-0033-1357272.