

REVIEW ARTICLE

Diagnostic Performance of Ultrasonography for Identification of Small Bowel Obstruction; a Systematic Review and Meta-analysis

Mohsen Motavaselian¹, Mehrdad Farrokhi^{2*}, Parisa Jafari Khouzani³, Atousa Moghadam Fard¹, Fatemeh Daeizadeh¹, Mahya Pourrahimi⁴, Reyhaneh Mehrabani³, Reza Amani-Beni³, Masoud Farrokhi¹, Faezeh Jalayer Sarnaghy⁵, Asal Mir⁶, Reza Tavakoli³, Heidar Fadavian⁷, Reza Mehdinezhad⁸, Parisa Masoudikabir⁹, Maoumeh Moallem¹⁰, Tohid Karami¹¹, Roozbeh Roohinezhad¹², Yalda Yazdani¹³, Didar Ghasemi¹, Farideh Rezaeizadeh¹, Alireza Hadizadeh¹⁴, Rojin Sarallah¹⁴, Ashkan Shafigh¹⁵, Solmaz Aminpour¹⁶, Amirhossein Esfahani¹, Seyedsaber Mirabdali¹⁷, Zahrasadat Hosseini¹, Farahnaz Saharkhiz¹, Mehrzad Khodsiani¹, Fahimeh Ebrahimi Tirtashi¹⁸, Shabnam Esmailian Dehkordi¹, Nafise Sadat Amini¹, Mahsa Aran¹, Zohreh Abolghasemfard¹, Nazanin Sanjarinia¹, Zeynab Abdollahi¹⁹, Fatemeh Abediankenari²⁰, Erfan Ghadirzadeh²¹, Mehran Khodashenas¹, Ali Jahanshahi¹

1. ERIS Research Institute, Tehran, Iran.
2. Student Research Committee, Department of Epidemiology, School of Public Health and Safety, Shahid Beheshti University of Medical Sciences, Tehran, Iran.
3. School of Medicine, Isfahan University of Medical Sciences, Isfahan, Iran.
4. Department of Medical Sciences, Faculty of Medicine, Tehran Medical Sciences, Islamic Azad University, Tehran, Iran.
5. School of Medicine, Tehran University of Medical Sciences, Tehran, Iran.
6. Department of Medicine, Mashhad University of Medical Sciences, Mashhad, Iran.
7. Department of Electrical and Computer Engineering, Tarbiat Modares University, Tehran, Iran.
8. Department of Anesthesiology, School of Medicine, Urmia University of Medical Sciences, Urmia, Iran.
9. Department of Hematology and Blood Banking, School of Allied Medical Sciences, Shahid Beheshti University of Medical Sciences, Tehran, Iran.
10. Department of Emergency Medicine, Tehran Medical Sciences Branch, Islamic Azad University, Tehran, Iran.
11. Department of Anesthesiology, School of Medicine, Urmia University of Medical Sciences, Urmia, Iran.
12. School of Medicine, Iran University of Medical Sciences, Tehran, Iran.
13. Immunology Research Center, Tabriz University of Medical Sciences, Tabriz, Iran.
14. Female Pelvic Medicine and Reconstructive Surgery (FPMRS), Division of Urogynecology, University of Chicago, Northshore University Health System, Skokie, IL, USA.
15. Research Center for Evidence-Based Medicine, Iranian EBM Center: A Joanna Briggs Institute Center of Excellence, Tabriz University of Medical Sciences, Tabriz, Iran.
16. Research Centre of Applied and Preventive Cardiovascular Medicine, University of Turku, Turku, Finland.
17. Department of Pharmaceutical Sciences, North Dakota State University, Fargo, North Dakota, USA.
18. Department of Food Science and Technology, National Nutrition and Food Technology Research Institute, Faculty of Nutrition and Food Technology, Shahid Beheshti University of Medical Sciences, Tehran, Iran.
19. Department of Radiology, School of Medicine Ahvaz Jundishapur University of Medical Sciences, Ahvaz, Iran.
20. Immunogenetics Research Center, Mazandaran University of Medical Sciences, Sari, Iran.
21. School of Medicine, Mazandaran University of Medical Sciences, Sari, Iran.

Received: January 2024; Accepted: February 2024; Published online: 3 March 2024

Abstract: **Introduction:** Small bowel obstruction (SBO) is known as a common cause of acute abdominal complaints in the emergency department (ED). The modality of choice for the diagnosis of SBO has not yet been established. This systematic review and meta-analysis aimed to investigate the accuracy of ultrasonography for the diagnosis of SBO. **Methods:** Systematic search was performed on five electronic databases including Medline, Scopus, Web of Sciences, Embase, and Cochrane Library, and the retrieval period was from the inception of each database to November 2023. The quality of the included studies were investigated using the Quality Assessment of Diagnostic Accuracy Studies 2 (QUADAS-2). The pooled values of diagnostic characteristics for ultrasonography were estimated using meta-Disc and Stata statistical software. **Results:** Twenty-one studies with a total of 1977 patients were included in the meta-analysis. The pooled estimate for sensitivity, specificity, positive likelihood ratio (PLR), negative likelihood ratio (NLR), diagnostic odds ratio (DOR), and area under the summary ROC curve of ultrasonography for diagnosing SBO were 0.93 (95% CI: 0.91–0.95), 0.8 (95% CI: 0.77–0.83), 5.69 (95% CI: 3.64–8.89), 0.1 (95% CI: 0.07–0.16), 83.51 (95% CI: 18.12–182.91) and 0.96, respectively. **Conclusion:** The findings of this meta-analysis showed that the utilization of ultrasonography holds promise as a diagnostic imaging for SBO with high accuracy. However, additional worldwide studies are essential to get more evidence on the value of ultrasonography for the diagnosis of SBO.

Keywords: Diagnosis; Intestinal Obstruction; Ultrasonography; Meta-analysis

Cite this article as: Motavaselian M, Farrokhi M, Jafari Khouzani P, et al. Diagnostic Performance of Ultrasonography for Identification of Small Bowel Obstruction; a Systematic Review and Meta-analysis. Arch Acad Emerg Med. 2024; 12(1): e33. <https://doi.org/10.22037/aaem.v12i1.2265>.

1. Introduction

Small bowel obstruction (SBO) is known as a common cause of acute abdominal complaints in the emergency department (ED) (1). It has been reported that SBOs comprise approximately 15% of hospital admissions due to acute non-traumatic abdominal pain and in the United States, more than 300,000 cases are hospitalized annually for the possible diagnosis of SBO (2-4). Adhesions from previous surgical interventions account for approximately 80% of SBO in developed countries followed by hernias, malignancies, intussusceptions, volvulus, and inflammatory bowel diseases (5-7). SBO is commonly characterized by abdominal pain, nausea, vomiting, constipation, inability to pass flatus or stools, and abdominal distention. Past medical history and physical examinations are not reliable for diagnosis of SBO, as there are some other differential diagnoses with similar presentations (8, 9). The patients with the diagnosis of SBO need early surgical consultation for the management of obstruction. Diagnostic delay of SBO can be correlated with a higher risk of complications such as strangulation, necrosis, intestinal perforation, peritonitis, sepsis, and death (10-12). Radiologic imaging has a pivotal role in the diagnosis and in directing the treatment of cases with SBO.

Supine and upright abdominal radiographs are commonly used for SBO diagnosis, but relatively low sensitivity and inconclusive results limit their utility and, in most cases, a computed tomography (CT) scan is required to diagnose or rule out SBO (13-15). CT scan of the abdomen has high diag-

nostic performance for the identification of SBO and continues to be the gold standard. However, imaging with CT entails radiation exposure, risks of contrast administration, increased overall health care costs, and transfer to the radiology suite (14, 15). Previous investigations have revealed that ultrasonography outperforms abdominal radiographs for the diagnosis of SBO (16, 17). Recently, point-of-care ultrasound (POCUS) has grown for the evaluation of SBO by emergency physicians and is increasingly being touted as the primary imaging method for suspected cases. However, there is still a great deal of uncertainty regarding the diagnostic performance of ultrasonography for the diagnosis of SBO. Recently published papers have shown variable accuracy of ultrasonography for early identification of SBO. This systematic review and meta-analysis aimed to investigate and update our knowledge regarding the accuracy of ultrasonography for the diagnosis of SBO.

2. Methods

2.1. Search Strategy

The systematic review and meta-analysis regarding the accuracy of ultrasonography for diagnosis of SBO was conducted according to the Diagnostic Test Accuracy Preferred Reporting Items for Systematic Reviews and Meta-analysis (DTA-PRISMA) guidelines (18). Two independent investigators performed a systematic search on five electronic databases including Medline, Scopus, Web of Sciences, Embase, and Cochrane Library, and the retrieval period was from the inception of each database to November 2023. Medical subject headings (MeSH) terms and keywords used for the search were “Ultrasonography” OR “Ultrasound” OR “Sonography” OR “US” OR “Point-of-care Ultrasound” OR “POCUS” AND “Small bowel obstruction” OR “Bowel obstruction” OR “SBO” OR “Intestinal Obstruction” OR “Small intestinal obstruc-

*Corresponding Author: Mehrdad Farrokhi: Student Research Committee, Department of Epidemiology, School of Public Health and Safety, Shahid Beheshti University of Medical Sciences, Tehran, Iran. Email: drfarrokhi2024@gmail.com, Phone number: +989138727606.

Running Head: Ultrasonography and Small Bowel Obstruction.

tion". Furthermore, the reference lists of the included publications and Google Scholar were manually searched to include additional pertinent studies. Our systematic search was limited to only studies in English.

2.2. Study Selection

Published papers were included in this review if they met the following criteria: 1) true positive (TP), true negative (TN), false positive (FP), and false negative (FN) could be retrieved to form a 2x2 table; 2) CT scan or surgical diagnosis was used as the gold standard; 3) at least 10 patients were assessed for possible diagnosis of SBO using ultrasonography; and 4) study was published in English. Case reports, case series with less than 10 cases, comments, narrative reviews, and animal studies were excluded. Moreover, Studies were disqualified for inclusion if they overlapped with other studies included in databases.

2.3. Data Extraction and Quality Assessment

Two independent authors extracted the data using a pre-designed extraction form. A third author reviewed the entered data and resolved disagreements between two data collectors. The following data were extracted from the included studies: the surname of the first author, publication year, the origin country, sample size, bibliographic information, ultrasound criteria for SBO, gold standard for diagnosis of SBO, TP, TN, FP, and FN. The quality of the included studies including the risk of bias and applicability were investigated using the Quality Assessment of Diagnostic Accuracy Studies 2 (QUADAS-2).

2.4. Data Synthesis and Statistical Analysis

The pooled values of diagnostic characteristics for ultrasonography were estimated using meta-Disc software version 1.4 (Ramona Cajal Hospital, Madrid, Spain) and Stata statistical software package (Stata Corp., College Station, TX, USA) (version 17.0). The p-value of Cochran's Q statistic and the I² were used to evaluate heterogeneity. The I² > 50% and p < 0.05 both showed the presence of heterogeneity, suggesting the need for the random-effect model for meta-analysis. On the contrary, p > 0.05 and I² < 50% proposed the need for a fixed-effect model. Publication bias was assessed using Egger's and Begg's tests and funnel plots. The pooled results of diagnostic characteristics were presented using the area under the summary ROC curve and forest plots. Subgroup analyses were performed to evaluate sources of heterogeneity.

3. Results

3.1. Search Results

A total of 889 studies were retrieved using the keywords and MeSH terms in the databases and gray literature, of which 426 were duplicates, resulting in 463 titles and abstracts assessed according to the eligibility criteria. Of these studies, 84 papers were selected for the full-text review. Finally, 21

studies met the inclusion criteria and were included in the systematic review and twenty of them were included in the meta-analysis. Figure 1 depicts study identification, inclusion, and exclusion in the PRISMA flow diagram.

3.2. Characteristics of the Included Studies

Twenty-one studies with a total of 1977 patients from 13 countries with a mean age ranging from 33 to 71 years were included in this meta-analysis. All studies were published in English between 1984 and 2023. Most studies were conducted in the USA (7 studies), France (2 studies), Italy (2 studies), and Iran (2 studies). CT scans, surgical pathology, and clinical follow-up were most commonly used as the gold standard among the included studies. Other characteristics of the included studies are summarized in Table 1.

3.3. Results of Quality Assessment and Publication Bias

The methodological quality evaluation of the included studies for the potential sources of bias and applicability concerns was performed using QUADAS-2. Table 2 shows that the quality of the assessed publications was relatively high. However, some studies had a high risk of bias for patient selection and flow and timing domains. All included studies had a low risk of bias for index tests. The Egger test showed a significant publication bias in the included studies (P=0.04). Similarly, the funnel plot revealed an asymmetrical distribution of the studies suggesting significant publication bias across the studies (Figure 2).

3.4. Meta-analysis

The I² value and Cochran Q test revealed significant heterogeneity between included studies for the sensitivity (I² = 62%, P < 0.01), specificity (I² = 88%, P < 0.01), PLR (I² = 87.7%, P < 0.01), NLR (I² = 63.9%, P < 0.01), and DOR (I² = 73.1%, P < 0.01); therefore, meta-analysis was carried out using the random-effects model. The pooled estimate for sensitivity, specificity, PLR, NLR, DOR and AUC of the SROC of ultrasonography for diagnosing SBO was 0.93 (95% CI: 0.91–0.95), 0.8 (95% CI: 0.77–0.83), 5.69 (95% CI: 3.64–8.89), 0.1 (95% CI: 0.07–0.16), 83.51 (95% CI: 18.12–182.91) and 0.96, respectively (Figures 3-5). Furthermore, the results of subgroup analyses concerning the gold standard and sample size revealed similar findings (Table 3).

4. Discussion

This systematic review and meta-analysis investigated the sensitivity and specificity of ultrasonography for detecting SBO. We included 21 studies in the meta-analysis and the findings showed an excellent sensitivity (0.93) and a good specificity (0.8). The pooled accuracy of ultrasonography for the diagnosis of SBO was 0.96. The results of this study suggest that ultrasonography can be used as a means for early and rapid identification of SBO. However, significant heterogeneity between included studies for sensitivity and speci-

ficity made the findings less credible.

In a recent systematic review and meta-analysis by Shokoohi et al. (17), the accuracy of point-of-care ultrasonography for the diagnosis of SBO was investigated using a multi-center analysis of recently published studies. In this systematic review, they included only recent prospective observational or randomized control trials to have access to original patient-level data. Their systematic search was limited to studies published from 2011 to 2022. They showed that ultrasonography had 0.83 sensitivity and 0.93 specificity for the diagnosis of SBO. A possible explanation for these inconsistencies may lie in the fact that Shokoohi et al. included a small number of studies and their systematic search had different limitations. The type of their analyses was also different from ours as they used the data that were obtained from the corresponding authors of their included studies. They found that the overall accuracy of ultrasonography for the diagnosis of SBO is 0.88, which is lower than the accuracy found in our study (0.96). Similar to our study, they found significant heterogeneity among the included studies, which may be due to differences between studies with respect to the clinician experience level. As they had access to original patient-level data, their comparative analysis revealed that residents performing ultrasonography have lower values of sensitivity and specificity compared to fellow and attending clinicians. Their findings showed that ultrasonography for diagnosis of SBO in patients with higher BMI is accompanied by lower values of sensitivity and specificity. Since the majority of our included studies did not report the results of diagnostic characteristics in different categories of BMI, we could not perform the same subgroup analysis.

Another systematic review by Pourmand et al. (19) was performed to evaluate the accuracy of ultrasonography for the diagnosis of SBO. In this study, they assessed four databases from 1990 to 2017. Finally, they included five studies in their qualitative analysis. While they did not conduct a meta-analysis, their qualitative results revealed that ultrasonography has high sensitivity with a range of 94-100 percent and specificity ranging from 81-100 percent. In addition, their study could not provide a definite answer to the question of whether ultrasonography can replace CT scans in suspected cases of SBO.

In a meta-analysis conducted by Lin et al. (year), a similar methodology was employed, albeit on a smaller number of studies, to investigate the diagnostic accuracy of ultrasonography for identifying SBO. Their pooled sensitivity (0.92) and specificity (0.93) values differed from those found in our study. This discrepancy may be partly explained by the results of the subgroup analysis conducted in our study, specifically concerning the variable of the sample size. Indeed, the results of the subgroup analysis indicate that with an increase in sample size, sensitivity tends to increase while specificity tends to decrease.

The modality of choice for the definite diagnosis of SBO has not yet been established (20, 21). Findings from CT scans,

pathology evaluations, histology, surgical interventions, and clinical follow-ups are all used for the diagnosis of SBO. The included studies used different gold standards or combinations of different modalities, which may be a cause of significant heterogeneity in the diagnostic characteristics of ultrasonography.

Although ultrasonography is easily accessible, provides a rapid diagnosis, is less expensive, and has lower radiation exposure compared to CT scans, potential surgical candidates of SBO are still commonly diagnosed using CT scans in the emergency departments (22, 23). Moreover, it should be noted that the majority of our included studies used CT scans and surgery as their gold standards, highlighting the significant dependence of physicians on this modality of imaging. Therefore, the establishment of ultrasonography as a promising imaging substitute for CT scans requires further well-designed prospective studies with larger sample sizes (22). Since the value of specificity was lower than sensitivity in our study, the results of ultrasonography should be interpreted with caution to prevent unnecessary surgical interventions in false-positive cases (24).

5. Limitations

The present meta-analysis had some limitations. First, the included studies were conducted in a limited number of countries, which may reduce the generalizability of the results to other countries with different healthcare systems. Second, the included studies had different gold standards, and CT scans or surgical findings were not considered in all studies, which may reflect uncertainty regarding the reliability of the results. Third, the high degree of heterogeneity among the diagnostic characteristics of included studies may affect the interpretation of the findings. Finally, this systematic review included studies on adults and its findings may not be generalizable to pediatric cases.

6. Conclusions

The findings of this meta-analysis showed that the utilization of ultrasonography holds promise as diagnostic imaging for SBO with high accuracy. However, since our investigation had some limitations regarding the included studies, additional worldwide studies are essential to get more evidence on the value of ultrasonography for the diagnosis of SBO.

7. Declarations

7.1. Acknowledgments

The authors thank all those who contributed to this study.

7.2. Conflict of interest

None.

7.3. Funding

None.

7.4. Authors' contribution

All authors contributed to the study design, data collection, and writing the draft of the study. All authors read and approved the final version of the manuscript.

7.5. data availability

Not applicable.

7.6. Using Artificial Intelligence Chatbots

None.

References

1. Becker BA, Lahham S, Gonzales MA, Nomura JT, Bui MK, Truong TA, et al. A prospective, multicenter evaluation of point-of-care ultrasound for small-bowel obstruction in the emergency department. *Academic Emergency Medicine*. 2019;26(8):921-30.
2. Guttman J, Stone MB, Kimberly HH, Rempell JS. Point-of-care ultrasonography for the diagnosis of small bowel obstruction in the emergency department. *Canadian Journal of Emergency Medicine*. 2015;17(2):206-9.
3. Hastings RS, Powers RD. Abdominal pain in the ED: a 35 year retrospective. *The American journal of emergency medicine*. 2011;29(7):711-6.
4. Scott FI, Osterman MT, Mahmoud NN, Lewis JD. Secular trends in small-bowel obstruction and adhesiolysis in the United States: 1988–2007. *The American journal of surgery*. 2012;204(3):315-20.
5. Barzegari H, Delirrooyfard A, Moatamedfar A, Sohani S, Sohani M. A New Point of Care Ultrasound in disposition of patients with small bowel obstruction in Emergency Department. *International Journal of Pharmaceutical Research Allied Sciences*. 2016;5(2).
6. Delabrousse E, Destrumelle N, Brunelle S, Clair C, Man tion G, Kastler B. CT of small bowel obstruction in adults. *Abdominal imaging*. 2003;28:0257-66.
7. Ogata M, Mateer JR, Condon RE. Prospective evaluation of abdominal sonography for the diagnosis of bowel obstruction. *Annals of surgery*. 1996;223(3):237.
8. Frasure SE, Hildreth AF, Seethala R, Kimberly HH. Accuracy of abdominal ultrasound for the diagnosis of small bowel obstruction in the emergency department. *World Journal of Emergency Medicine*. 2018;9(4):267.
9. Liaqat R, Majeed AI, Liaqat B, Shafi A, Riaz R, Akhtar S. Diagnostic Accuracy of Ultrasound for Small Bowel Obstruction in Paediatric Population Undergoing Laparotomy Keeping Surgical Findings as the Gold Standard. *Pakistan Armed Forces Medical Journal*. 2022;72(4):1351-54.
10. Bickell NA, Federman AD, Aufses Jr AH. Influence of time on risk of bowel resection in complete small bowel obstruction. *Journal of the American College of Surgeons*. 2005;201(6):847-54.
11. Hwang U, Aufses Jr AH, Bickell NA. Factors associated with delays to emergency care for bowel obstruction. *The American journal of surgery*. 2011;202(1):1-7.
12. Fevang BT, Fevang J, Stangeland L, Søreide O, Svanes K, Viste A. Complications and death after surgical treatment of small bowel obstruction: a 35-year institutional experience. *Annals of surgery*. 2000;231(4):529.
13. Maglinte D, Kelvin F, Sandrasegaran K, Nakeeb A, Romano S, Lappas J, et al. Radiology of small bowel obstruction: contemporary approach and controversies. *Abdominal imaging*. 2005;30:160-78.
14. Mallo RD, Salem L, Lalani T, Flum DR. Computed tomography diagnosis of ischemia and complete obstruction in small bowel obstruction: a systematic review. *Journal of Gastrointestinal Surgery*. 2005;9:690-4.
15. Zalcmán M, Sy M, Donckier V, Closset J, Gansbeke DV. Helical CT signs in the diagnosis of intestinal ischemia in small-bowel obstruction. *American journal of roentgenology*. 2000;175(6):1601-7.
16. Shokoohi H, Boniface KS, Loesche MA, Duggan NM, King JB. Development of a nomogram to predict small bowel obstruction using point-of-care ultrasound in the emergency department. *The American Journal of Emergency Medicine*. 2020;38(11):2356-60.
17. Shokoohi H, Mayes KD, Peksa GD, Loesche MA, Becker BA, Boniface KS, et al. Multi-center analysis of point-of-care ultrasound for small bowel obstruction: A systematic review and individual patient-level meta-analysis. *The American Journal of Emergency Medicine*. 2023.
18. McInnes MD, Moher D, Thombs BD, McGrath TA, Bossuyt PM, Clifford T, et al. Preferred reporting items for a systematic review and meta-analysis of diagnostic test accuracy studies: the PRISMA-DTA statement. *Jama*. 2018;319(4):388-96.
19. Pourmand A, Dimbil U, Drake A, Shokoohi H. The accuracy of point-of-care ultrasound in detecting small bowel obstruction in emergency department. *Emergency medicine international*. 2018;2018.
20. Paulson EK, Thompson WM. Review of small-bowel obstruction: the diagnosis and when to worry. *Radiology*. 2015;275(2):332-42.
21. Danse E, Kichouh M, Laterre PF. Small bowel obstruction: is sonography contributive for its diagnosis in difficult cases? *Jbr-btr*. 2007;90(6):535-9.
22. Furukawa A, Yamasaki M, Takahashi M, Nitta N, Tanaka T, Kanasaki S, et al. CT diagnosis of small bowel obstruction: scanning technique, interpretation and role in the diagnosis. *Semin Ultrasound CT MR*. 2003;24(5):336-52.
23. Wale A, Pilcher J. Current Role of Ultrasound in Small Bowel Imaging. *Semin Ultrasound CT MR*. 2016;37(4):301-12.
24. Hefny AF, Corr P, Abu-Zidan FM. The role of ultrasound in the management of intestinal obstruction. *Journal of emergencies, trauma, and shock*. 2012;5(1):84.
25. Ko YT, Lim JH, Lee DH, Lee HW, Lim JW. Small

- bowel obstruction: sonographic evaluation. *Radiology*. 1993;188(3):649-53.
26. Czechowski J. Conventional Radiography and Ultrasonography in the Diagnosis of Small Bowel Obstruction and Strangulation. *Acta Radiologica*. 1996;37(2):186-9.
 27. Schmutz G, Benko A, Fournier L, Peron J, Morel E, Chiche L. Small bowel obstruction: role and contribution of sonography. *European radiology*. 1997;7:1054-8.
 28. Kohn A, Cerro P, Milite G, De Angelis E, Prantera C. Prospective evaluation of transabdominal bowel sonography in the diagnosis of intestinal obstruction in Crohn's disease: comparison with plain abdominal film and small bowel enteroclysis. *Inflammatory bowel diseases*. 1999;5(3):153-7.
 29. Suri S, Gupta S, Sudhakar P, Venkataramu N, Sood B, Wig J. Comparative evaluation of plain films, ultrasound and CT in the diagnosis of intestinal obstruction. *Acta radiologica*. 1999;40(4):422-8.
 30. Grunshaw N, Renwick I, Scarisbrick G, Nasmyth D. Prospective evaluation of ultrasound in distal ileal and colonic obstruction. *Clinical radiology*. 2000;55(5):356-62.
 31. Musoke F, Kawooya M, Miguli-Malwadde E. Comparison between sonographic and plain radiography in the diagnosis of small bowel obstruction at Mulago Hospital, Uganda. *East African medical journal*. 2003;80(10):540-5.
 32. Lin C-K, Chiu H-M, Lien W-C, Liu Y-P, Chang C-Y, Wang H-P. Ultrasonographic bisection approximation method for gastrointestinal obstruction in ER. *Hepato-gastroenterology*. 2006;53(70):547-51.
 33. Ünlüer EE, Yavasi Ö, Eroglu O, Yilmaz C, Akarca FK. Ultrasonography by emergency medicine and radiology residents for the diagnosis of small bowel obstruction. *European Journal of Emergency Medicine*. 2010;17(5):260-4.
 34. Jang TB, Schindler D, Kaji AH. Bedside ultrasonography for the detection of small bowel obstruction in the emergency department. *Emergency Medicine Journal*. 2010.
 35. Tamburrini S, Lugarà M, Iaselli F, Saturnino PP, Liguori C, Carbone R, et al. Diagnostic accuracy of ultrasound in the diagnosis of small bowel obstruction. *Diagnostics*. 2019;9(3):88.
 36. Boniface KS, King JB, LeSaux MA, Haciski SC, Shokoohi H. Diagnostic accuracy and time-saving effects of point-of-care ultrasonography in patients with small bowel obstruction: a prospective study. *Annals of emergency medicine*. 2020;75(2):246-56.
 37. Singer D, Larson J, Reardon L, Lohse M, Fernandes R, Sbayi S, et al. Can point-of-care ultrasound speed up time to diagnosis for small bowel obstruction? *Academic Emergency Medicine*. 2022;29(11):1379-80.
 38. Biggs D, Kolster L, Patwa A, Graziano A, Pandey D, Heiney J, et al. Utilizing Point of Care Ultrasound to Evaluate for Small Bowel Obstruction in Emergency Department Patients. *European Journal of Medical and Health Sciences*. 2022;4(5):85-8.
 39. Alsufyani DS, Bagabas S, Alhamdi A, Basulaib N, Aleid M, Alkhulaif AH. Accuracy of point-of-care ultrasonography compared to abdominal X-ray in the diagnosis of small bowel obstruction in emergency patients. *Saudi Journal of Emergency Medicine*. 2022;3(3):181-.
 40. Sabzghabaei A, Shojaei M, Chavoshzadeh M. Diagnostic Accuracy of Ultrasonography by Emergency Medicine Resident in Detecting Intestinal Obstruction; a Pilot Study. *Archives of Academic Emergency Medicine*. 2022;10(1).
 41. Amimer S, Le Bastard Q, Berranger C, Batard E, Le Conte P. Abdominal point-of-care ultrasound for the exclusion of bowel obstruction: prospective multicentre observational study. *European Journal of Emergency Medicine*. 2023;30(4):298-9.

Table 1: Detailed characteristics of the included studies

| Author | Year | Country | No. | Male | Age | Ultrasound Criteria | Standard | TP | FP | FN | TN |
|-------------------------|------|----------------|-----|------|------|--|---|-----|----|----|----|
| Ko et al. (25) | 1993 | South Korea | 54 | 59.2 | 45 | 1) Lumen of the fluid-filled small bowel loops was dilated more than 3 cm 2) The length of a segment of the dilated small bowel was over 10 cm 3) Peristalsis of the dilated segment was increased 4) Colon was collapsed. | Surgery | 48 | 0 | 6 | 0 |
| Czechowski et al. (26) | 1996 | Sweden | 96 | 46 | 39 | 1) ≥ 25 mm 2) Abnormal peristalsis | Surgery | 18 | 1 | 1 | 76 |
| Ogata et al. (7) | 1996 | United States | 50 | 46 | 54 | 1) ≥ 25 mm 2) Abnormal peristalsis 3) Present free fluid | Surgery or clinical diagnosis | 21 | 1 | 3 | 25 |
| Schmutz et al. (27) | 1997 | France | 123 | 57.7 | 59 | 1) ≥ 25 mm 2) Dilated bowel loops > 3 | Clinical Follow Up, Surgery, pathology, other imaging Techniques, and chart reviews | 77 | 5 | 4 | 23 |
| Kohn et al. (28) | 1999 | Italy | 44 | 75 | 44 | 1) ≥ 30 mm 2) Abnormal peristalsis 3) Collapsed colonic lumen 4) Increased bowel wall thickness 5) Present free fluid | Surgery | 23 | 0 | 5 | 16 |
| Suri et al. (29) | 1999 | India | 32 | 66 | 35 | 1) Present free fluid 2) Transition point | Surgery, contrast studies, or clinical follow-up | 25 | 0 | 5 | 2 |
| Grunshaw et al. (30) | 2000 | United Kingdom | 60 | 50 | 71 | 1) ≥ 20 mm (upper to mid-small bowel) 2) ≥ 15 mm (distal small bowel) 3) Present free fluid | Surgery, contrast enema, colonoscopy, CT, postmortem, or clinical follow-up | 44 | 3 | 1 | 12 |
| Musoke et al. (31) | 2003 | Uganda | 70 | 60 | 33 | 1) ≥ 25 mm (jejunum) 2) ≥ 15 mm (ileum) 3) Dilated bowel loops > 3 | Surgery, pathology, or clinical follow-up | 51 | 0 | 4 | 15 |
| Lin et al. (32) | 2006 | Taiwan | 229 | NR | NR | 1) ≥ 25 mm 2) Collapsed colonic lumen 3) Presence of free fluid 4) Valvulae conniventes | Surgery or CT | 147 | 10 | 5 | 67 |
| Unltier et al. (33) | 2010 | Turkey | 174 | 61 | 56 | 1) ≥ 25 mm (jejunum) 2) ≥ 15 mm (ileum) 3) Dilated bowel loops > 3 4) Abnormal peristalsis | Surgical pathology or clinical follow-up | 84 | 6 | 2 | 76 |
| Jang et al. (34) | 2011 | United States | 76 | NR | NR | 1) ≥ 25 mm 2) Abnormal peristalsis 3) Present free fluid | CT | 12 | 0 | 5 | 27 |
| Barzegari et al. (5) | 2016 | Iran | 133 | NR | NR | 1) ≥ 25 mm 2) Abnormal peristalsis 3) Presence of free fluid 4) Bowel wall thickness | CT | 64 | 26 | 0 | 43 |
| Frasure et al. (8) | 2018 | United States | 64 | 34.4 | 63 | 1) ≥ 25 mm 2) Abnormal peristalsis 3) Presence of free fluid | CT | 33 | 1 | 2 | 20 |
| Becker et al. (1) | 2019 | United States | 217 | 47.5 | 55 | 1) ≥ 25 mm 2) Abnormal peristalsis 3) Bowel wall thickness 4) Presence of free fluid 5) Transition point | CT | 82 | 57 | 11 | 67 |
| Tamburrini et al. (35) | 2019 | Italy | 43 | 60 | 63 | 1) ≥ 25 mm 2) Abnormal peristalsis 3) Collapsed colonic lumen 4) Increased bowel wall thickness 5) Presence of free fluid | CT | 24 | 1 | 2 | 16 |
| Boniface et al. (36) | 2020 | United States | 125 | 46 | 54 | 1) ≥ 25 mm 2) Abnormal peristalsis | CT | 17 | 36 | 4 | 83 |
| Singer et al. (37) | 2022 | United States | 35 | 37 | 59 | 1) Small bowel diameter ≥ 25 mm 2) Abnormal peristalsis | CT | 15 | 6 | 2 | 12 |
| Biggs et al. (38) | 2022 | United States | 101 | 35 | 65 | 1) ≥ 25 mm 2) Abnormal peristalsis | CT | 26 | 6 | 3 | 66 |
| Alsufyani et al. (39) | 2022 | Saudi Arabia | 77 | 53 | 56.8 | 1) ≥ 25 mm 2) To-and-fro movement of bowel contents 3) Presence of free fluid 4) Edematous small bowel wall > 3 mm | CT and Follow Up | 60 | 4 | 7 | 6 |
| Sabzghabaei et al. (40) | 2022 | Iran | 24 | 58.3 | 57.5 | 1) ≥ 25 mm 2) Wall thickness ≥ 3 mm 3) Presence of free fluid | Surgery | 17 | 4 | 1 | 2 |
| Amimer et al. (41) | 2023 | France | 150 | 44 | 69 | 1) Dilated incompressible fluid-filled intestinal loop (> 25 mm) with back-and-forth fluid movements | CT | 82 | 11 | 1 | 56 |

TP: true positive, TN: true negative, FP: false positive, FN: false negative, CT: computed tomography, NR: not reported, SBO: small bowel obstruction. No: sample size. Age is presented as mean (year). Gender is presented as male percentage.

Table 2: Quality assessment of the include studies using QUADAS-2 tool

| Study | Risk of bias | | | | Applicability concerns | | |
|--------------------|-------------------|------------|--------------------|-----------------|------------------------|------------|--------------------|
| | Patient selection | Index test | Reference standard | Flow and timing | Patient selection | Index test | Reference standard |
| Ko et al. | ☺ | ☺ | ☺ | ☺ | ☺ | ☺ | ☺ |
| Czechowski et al. | ? | ☺ | ? | ☺ | ? | ☺ | ☺ |
| Ogata et al. | ? | ☺ | ☺ | ? | ? | ☺ | ☺ |
| Schmutz et al. | ☺ | ☺ | ? | ? | ☺ | ☺ | ☺ |
| Kohn et al. | ☺ | ☺ | ☺ | ? | ☺ | ☺ | ☺ |
| Suri et al. | ☺ | ☺ | ☺ | ? | ☺ | ☺ | ☺ |
| Grunshaw et al. | ☺ | ☺ | ☺ | ? | ☺ | ☺ | ☺ |
| Musoke et al. | ☺ | ☺ | ☺ | ? | ☺ | ☺ | ☺ |
| Lin et al. | ☺ | ☺ | ☺ | ? | ☺ | ☺ | ☺ |
| Unlüter et al. | ? | ☺ | ☺ | ? | ? | ☺ | ☺ |
| Jang et al. | ? | ☺ | ☺ | ☺ | ? | ☺ | ☺ |
| Barzegari et al. | ☺ | ☺ | ☺ | ☺ | ☺ | ☺ | ☺ |
| Frasure et al. | ☺ | ☺ | ☺ | ☺ | ☺ | ☺ | ☺ |
| Becker et al. | ? | ☺ | ☺ | ☺ | ? | ☺ | ☺ |
| Tamburrini et al. | ☺ | ☺ | ☺ | ☺ | ☺ | ☺ | ☺ |
| Boniface et al. | ? | ☺ | ☺ | ☺ | ? | ☺ | ☺ |
| Singer et al. | ? | ☺ | ☺ | ☺ | ? | ☺ | ☺ |
| Biggs et al. | ☺ | ☺ | ☺ | ☺ | ☺ | ☺ | ☺ |
| Alsufyani et al. | ☺ | ☺ | ☺ | ☺ | ☺ | ☺ | ☺ |
| Sabzghabaei et al. | ☺ | ☺ | ☺ | ☺ | ☺ | ☺ | ☺ |
| Amimer et al. | ☺ | ☺ | ☺ | ☺ | ☺ | ☺ | ☺ |

☺: Low Risk; ☹: High Risk; ?: Unclear Risk.

Table 3: Subgroup analysis of the pooled diagnostic performance of ultrasonography for SBO

| Subgroups | Covariates | No. | Sensitivity | Specificity | PLR | NLR | Accuracy | DOR | rDOR | P |
|-------------|--------------------------------|-----|------------------|------------------|-------------------|------------------|----------|-----------------------|-------------------|------|
| Standard | CT or CT + Follow up | 10 | 0.92 (0.89-0.94) | 0.73 (0.69-0.76) | 3.94 (2.53-6.11) | 0.14 (0.08-0.23) | 0.94 | 47.58 (17.40-130.15) | 3.39 (0.47-24.69) | 0.2 |
| | Surgery or Surgery + Follow up | 6 | 0.93 (0.89-0.96) | 0.95 (0.91-0.97) | 15.21 (2.5-92.42) | 0.09 (0.05-0.19) | 0.97 | 206.48 (53.68-794.18) | | |
| Sample Size | <100 | 12 | 0.9 (0.87-0.93) | 0.92 (0.87-0.95) | 8.48 (3.46-20.79) | 0.14 (0.1-0.21) | 0.95 | 81.45 (31.58-210.05) | 1.4 (0.25-7.9) | 0.68 |
| | 100 | 8 | 0.95 (0.93-0.97) | 0.75 (0.72-0.79) | 4.82 (2.81-8.27) | 0.07 (0.03-0.15) | 0.93 | 83.66 (23.72-295.07) | | |

CT: computed tomography, DOR: diagnostic odds ratio, PLR: positive likelihood ratio, NLR: negative likelihood ratio.

All measures are presented with 95% confidence interval.

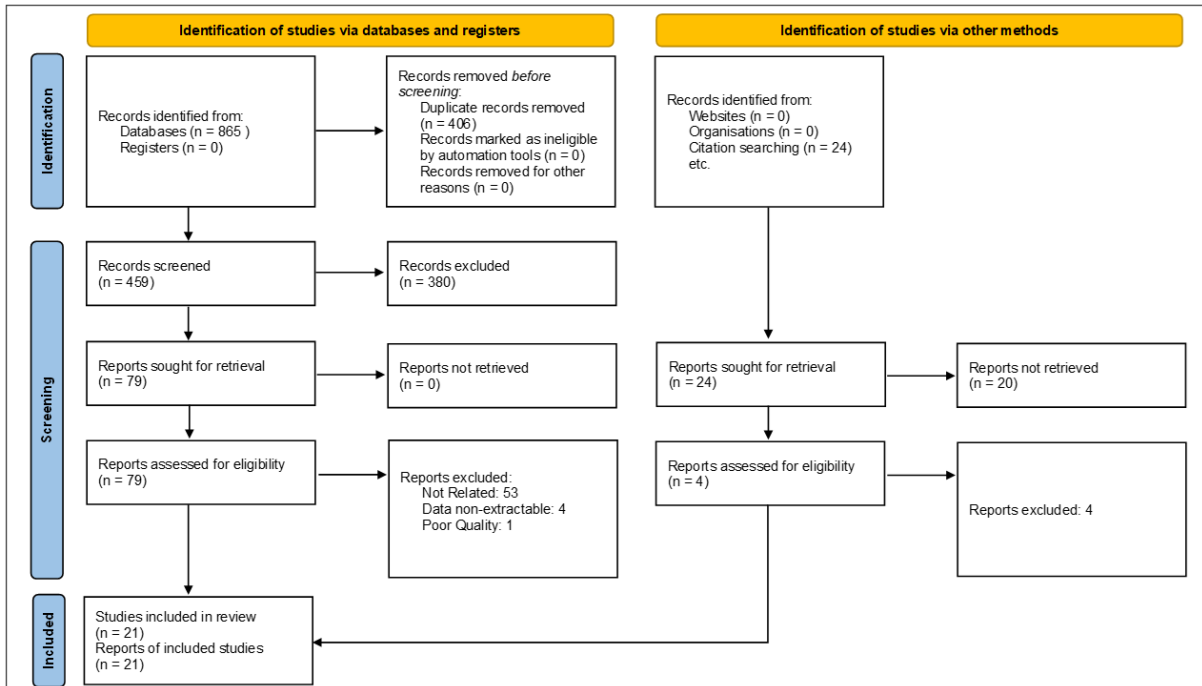


Figure 1: PRISMA flowchart of the literature search and selection of studies that evaluated accuracy of ultrasonography for the diagnosis of small bowel obstruction.

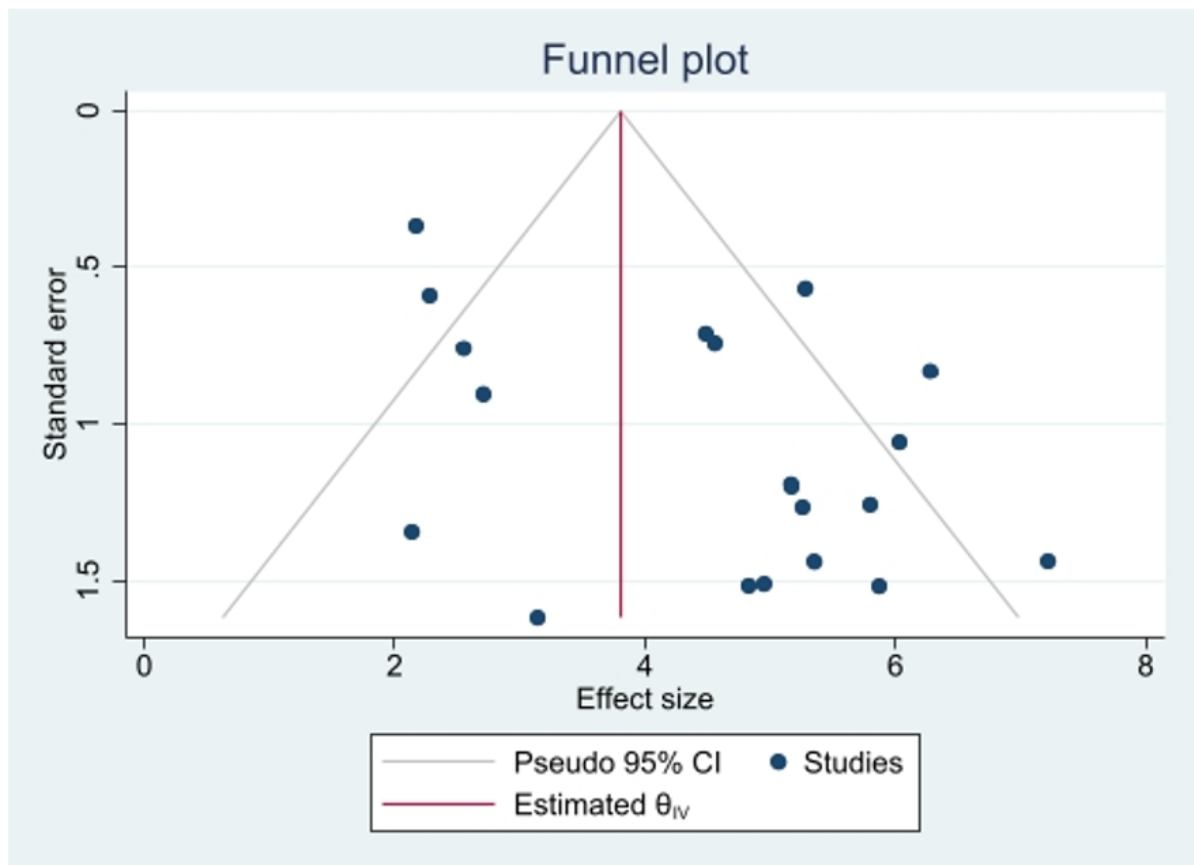


Figure 2: Funnel plot of publication bias on the pooled DOR of ultrasonography for diagnosis of small bowel obstruction.

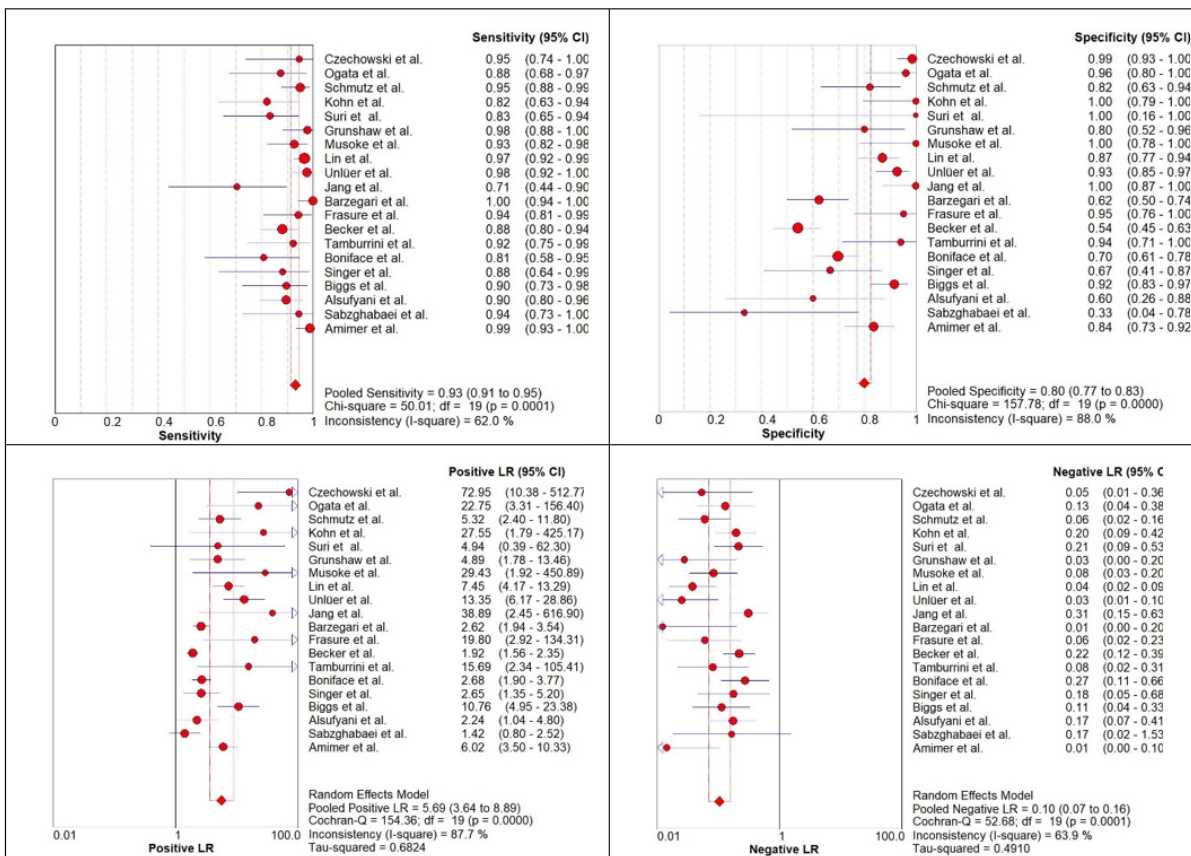


Figure 3: Forest plot of the pooled sensitivity, specificity, positive likelihood ratio (LR), negative LR, of ultrasonography for diagnosis of small bowel obstruction.

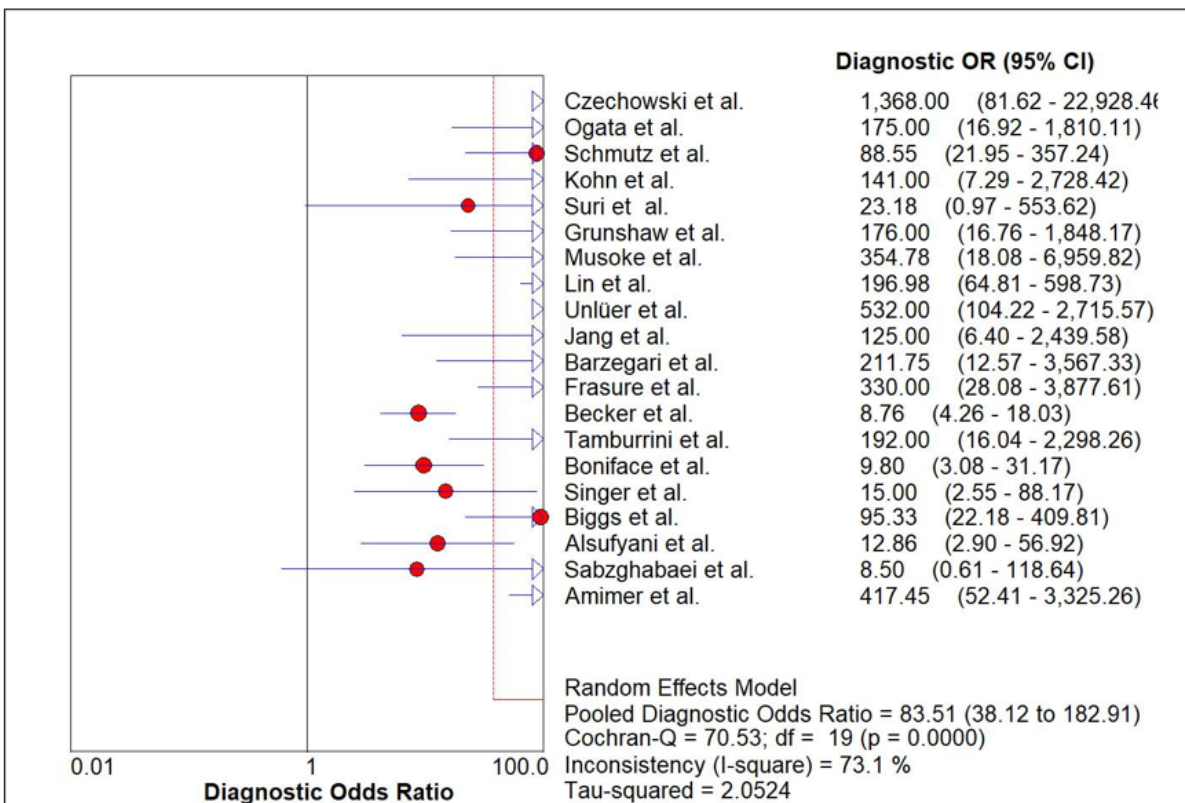


Figure 4: Forest plot of the diagnostic OR (DOR) of ultrasonography for diagnosis of small bowel obstruction.

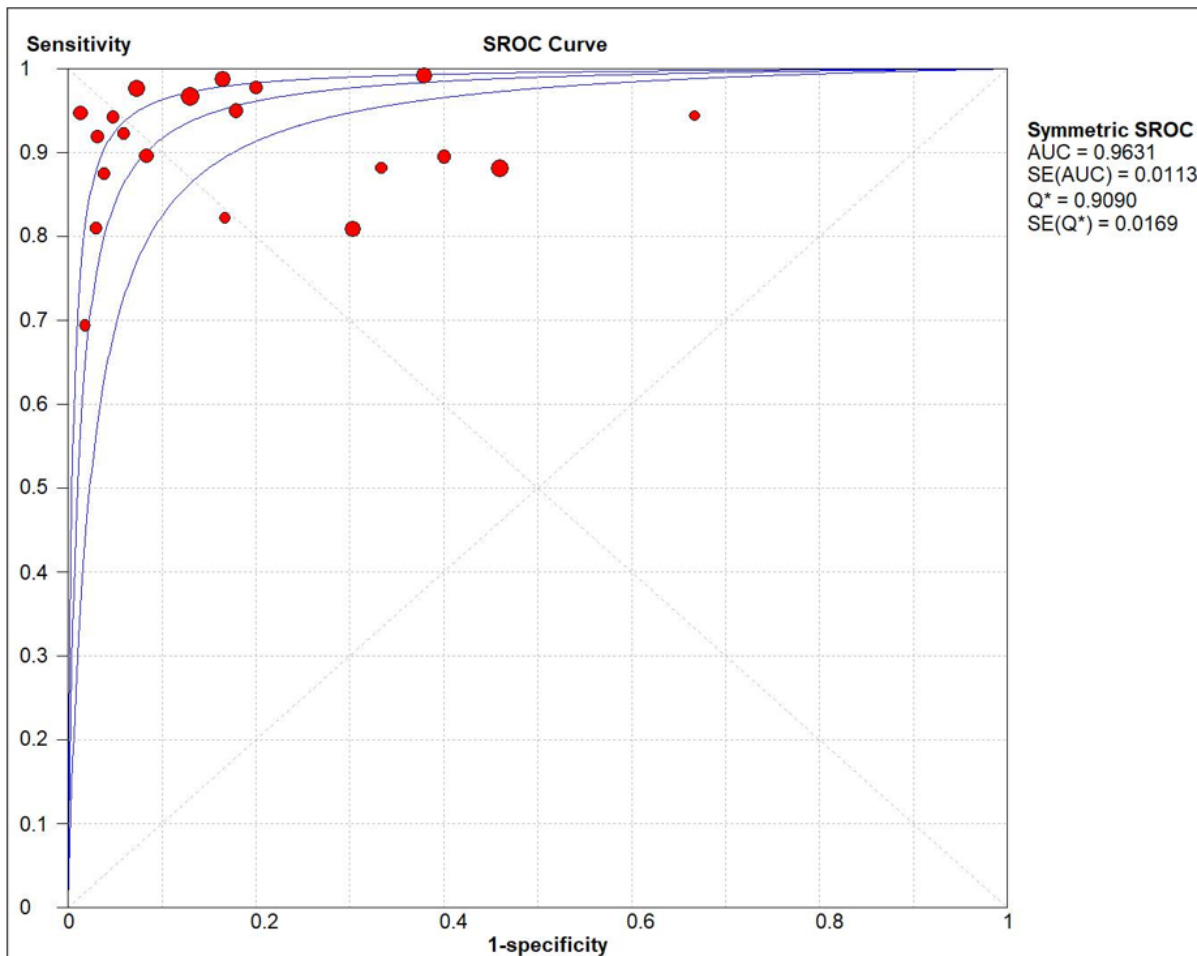


Figure 5: Summary receiver-operating characteristic (SROC) of ultrasonography for diagnosis of small bowel obstruction.