



**UNIVERSITY
OF TURKU**

This is an Accepted Manuscript version of the following article published originally by Oxford University Press, accepted for publication in the journal:

European heart journal : cardiovascular imaging

This version may differ from the original in pagination and typographic details. When using please cite the original.

AUTHOR(S)	Meucci Maria Chiara, Mantegazza Valentina, Wu Hoi W, van Wijngaarden Aniek L, Garlaschè Anna, Tamborini Gloria, Pepi Mauro, Bax Jeroen J, Ajmone Marsan Nina
TITLE	Structural and functional abnormalities of left-sided cardiac chambers in Barlow's disease without significant mitral regurgitation
YEAR	2024
DOI	10.1093/ehjci/jeae121
CITATION	Maria Chiara Meucci, Valentina Mantegazza, Hoi W Wu, Aniek L van Wijngaarden, Anna Garlaschè, Gloria Tamborini, Mauro Pepi, Jeroen J Bax, Nina Ajmone Marsan, Structural and functional abnormalities of left-sided cardiac chambers in Barlow's disease without significant mitral regurgitation, <i>European Heart Journal - Cardiovascular Imaging</i> , 2024;, jeae121, https://doi.org/10.1093/ehjci/jeae121
LICENSE	InCopyright © 2024 European Society of Cardiology

1 INTRODUCTION

2 Mitral valve prolapse (MVP) is the most common cause of primary MR and may be categorized in two
3 distinct phenotypes, i.e. fibroelastic deficiency (FED) and Barlow's disease (BD) (1). FED is typically
4 characterized by a single-segment prolapse/flail with thin leaflets. In turn, BD is defined by a bileaflet
5 or multi-scallops MVP, with diffuse thickening and redundancy of leaflets, elongated chordae and
6 annular abnormalities, and typically affects younger patients than FED (1).

7 The clinical course of patients with BD is often complicated by the development of severe MR, which
8 may result in progressive structural and functional remodeling of the left-sided chambers. Importantly,
9 the presence of left ventricular (LV) dysfunction or severe left atrial (LA) enlargement is a criterion for
10 mitral valve (MV) intervention in asymptomatic patients with severe MR, based on current guidelines
11 (with class I and IIa indications, respectively) (2). Recently, impaired LV or LA mechanics, as assessed
12 by speckle tracking-echocardiography, have also been suggested as early markers of cardiac damage in
13 patients with primary severe MR and of potential additive value in the decision-making regarding the
14 timing of surgical intervention (3,4).

15 On the other hand, recent studies in BD patients (5-7) have observed significant remodeling of the left-
16 sided chambers even in patients with mild or moderate MR, suggesting the presence of a myocardial
17 damage independent or disproportionate from MR severity. However, advanced echocardiographic
18 measures were not applied and the interpretation of these findings was challenged by other authors,
19 remaining a matter of debate (1,8). Furthermore, whether these chamber abnormalities have clinical
20 implications for disease progression, is still unclear.

21 Thus, aims of the present study were 1) to explore the presence of LV and LA morphological and
22 functional abnormalities, assessed by conventional and speckle-tracking echocardiography, in BD
23 patients without significant MR as compared to controls; 2) to investigate whether these abnormalities
24 may predict MR progression during follow-up.

1 without evidence of any cardiac abnormalities also with multi-modality imaging), ii) detection of
2 source of embolism, iii) symptoms of chest pain, or palpitations or dyspnoe.

3 The study complies with the Declaration of Helsinki and was approved by the Institutional Review
4 Boards. Due to the retrospective design of this study, the Medical Ethical Committees waived the need
5 for written informed consent.

6

7

8

9 *Conventional echocardiographic examination*

10 Comprehensive echocardiographic examinations were performed with commercially available
11 ultrasound systems (Vivid E7, E9, E95, GE- General Electric Vingmed, Horten, Norway). Images were
12 digitally stored for offline analyses, which were performed by an experienced operator at each
13 institution (MCM and VM).

14 LV linear dimensions were measured from parasternal long-axis views and LV mass was calculated
15 using the Devereux formula and indexed for body surface area (BSA) (11). Eccentric LV hypertrophy
16 (eLVH) was defined by the presence of LV mass index (LVMI) $>115 \text{ g/m}^2$ for men and $>95 \text{ g/m}^2$ for
17 women, in association with regional wall thickness <0.42 (11). From the apical 2- and 4-chamber
18 views, LV end-diastolic and end-systolic volumes were measured and indexed for BSA (LVEDVi and
19 LVESVi, respectively) and LVEF was calculated using the biplane Simpson's method (11). Maximal
20 and minimal LA volumes were measured from the apical 2- and 4-chamber views, at end-systole and
21 end-diastole respectively, using the biplane Simpson's method and subsequently indexed for BSA
22 (LAVi max and LAVi min, respectively) (12). The LA sphericity index, defined as the ratio between
23 the medio-lateral and superior-inferior LA diameters in the end-systolic phase, was also calculated.
24 Parameters of diastolic function were assessed according to the most recent guidelines (13).

1
2
3
4
5
6
7
8
9
10
11
12
13
14
15
16
17
18
19
20
21
22
23
24

MR progression

Follow-up echocardiograms, when available, were reviewed by two experienced observers to evaluate the progression of MR grade in patients with BD. For patients having more than one subsequent examination, the most recent (before MV surgery, if applicable) was considered. MR progression was defined by the presence of a MR grade at least moderate-to-severe.

Statistical Analysis

Continuous variables are expressed as mean (SD) or median (interquartile range [IQR]) and compared between two groups using the Student's t test or Mann-Whitney U test, as appropriate. Categorical data are presented as frequencies and percentages and compared using χ^2 test or the Fisher's exact test.

One-way analysis of variance with Bonferroni post-hoc tests and Kruskal-Wallis test were used for the comparison of continuous variables between three groups, as appropriate.

Uni- and multi-variable linear regression analyses were performed to identify clinical and echocardiographic variables associated with LA or LV parameters that were significantly abnormal in BD patients (LVEDVi, LVMi, LAVi max and LA reservoir strain).

The predictors of MR progression were investigated using uni- and multi-variable Cox proportional hazard regression models, censoring patients at the time of the last available echocardiogram. Variables with a significant correlation at univariable analysis ($p < 0.05$) were selected for multivariable analysis.

Significant collinearity was excluded for each multivariable model estimating the variance inflation factor (< 0.5).

All tests were two-sided, and p values < 0.05 were considered statistically significant. Data analysis was performed using SPSS version 25.0 (SPSS, Chicago, IL) and R version 4.0.1 (R Foundation for Statistical Computing, Vienna, Austria).

1
2
3
4
5
6
7
8
9
10
11
12
13
14
15
16
17
18
19
20
21
22
23
24

RESULTS

A total of 231 patients with BD fulfilled the inclusion criteria for the present study (**Figure 1**) and were matched in a 1:1 ratio (n=231) with controls with similar demographic characteristics and prevalence of cardiovascular risk factors and paroxysmal AF.

The comparative analysis between the two groups is shown in **Table 1**. BD patients and controls showed similar clinical features, while echocardiography revealed remarkable differences. BD patients had increased LV dimensions and LVMi as compared to the control group, resulting in a higher prevalence of eLVH (all $p < 0.001$). In addition, BD patients showed larger LA volumes ($p < 0.001$), accompanied by a higher LA sphericity index, reflecting a more spherical remodeling of the LA cavity. However, parameters of LV systolic performance, including LVEF and LVGLS, were similar between the two groups. Particularly, 30 patients with BD had LVGLS $< 17.5\%$, with a prevalence not different from controls (12.9% vs 11.1%; $p = 0.594$). LA reservoir strain values were significantly lower in BD patients ($p < 0.001$) and an impairment of LA mechanics (defined by values of LA strain $< 24\%$) was more common among BD patients than controls (20.4% vs 5.7%; $p < 0.001$). Conversely, there were no relevant differences between the two groups in other diastolic parameters including E/e' ratio and peak velocity of the tricuspid regurgitant jet.

Among patients with BD, the vast majority (n=189; 79%) had bileaflet MVP.

MR was graded as trivial in 36 (16%) patients, mild in 93 (40%) patients and mild-to-moderate in the remaining 102 (44%) subjects. Among BD patients in which the quantitative assessment was feasible (n=169, with mild or mild-to-moderate MR; not feasible in trivial MR), the median values of EROA and RVol were 15 (10-21) mm² and 18 (11-25) ml, respectively. Finally, BD patients were characterized by larger tricuspid annular diameter, higher values of TAPSE and higher prevalence of mild-to-moderate tricuspid regurgitation, as compared to controls.

1

2 *Patients with BD stratified according to MR grade*

3 When stratifying the BD population on the basis of MR grade, both patients with trivial or mild MR
4 (n=129) and patients with mild-to-moderate MR (n=102) had significantly larger LA and LV
5 dimensions and increased LVMi, together with a higher prevalence of eLVH in comparison to controls
6 (**Figure 2** and **Table S1**). However, these signs of chamber remodeling progressively worsened with
7 more severe MR and eLVH was more commonly present in patients with mild-to-moderate MR as
8 compared to patients with trivial or mild MR (39% vs 20%, p=0.001). Both BD subgroups showed
9 lower values of LA reservoir strain than controls, but without relevant differences in MR severity.
10 Parameters of LV performance, including LVGLS, were also similar between BD patients with trivial
11 or mild and those with mild-to-moderate MR.

12 In addition, BD patients with mild-to-moderate MR presented larger MV annular dilatation and a
13 higher prevalence of MAD (42% vs 29%, p=0.033), as compared to patients with trivial or mild MR.
14 **Figure 3** shows an illustrative case of a patient with BD and mild MR, showing LA and LV dilatation,
15 as well as eLVH and impaired LA strain.

16 Finally, we performed a comparative analysis, selecting the subgroup of patients with trivial MR (36
17 BD vs 210 controls), as displayed in **Table S2**. Notably, this analysis confirmed the presence of larger
18 volumes of left-sided chambers and MV annulus, together with lower LA reservoir strain in BD
19 patients, as compared to controls.

20

21 *Determinants of LA and LV remodeling in the overall population (BD and controls)*

22 Linear regression models in the total population (n=462) were built to investigate the determinants of
23 LA or LV parameters that differ between the two study groups: LVMi, LVEDVi, LAVi max and LA
24 reservoir strain. Multivariable regression analyses are shown in **Table 2**, while results of the

1 univariable analyses are illustrated in **Table S3**. Age, male sex, BD and MR grade were independent
2 associates of increased LVMi. Similarly, larger LVEDVi was independently associated with age, male
3 sex, BD, and MR grade, but also with the presence of MAD. LAVi max was independently related with
4 age, paroxysmal AF, BD and MR grade. Finally, LA reservoir strain was independently associated with
5 age, male gender, BD, LVGLS, LA sphericity index and E/e', but not with MR grade.

6 7 *MR progression in BD patients*

8 A total of 170 patient with BD had at least one follow-up echocardiogram performed after a median
9 interval of 37 months (IQR: 24-68) from the baseline echocardiogram. Progression to moderate-to-
10 severe or greater MR was observed in 51 (30%) subjects and 20 patients were consequently referred for
11 MV intervention. On univariable Cox regression analysis (shown in **Table 3**) age, MR grade, the
12 presence of MAD, LVMi (expressed as continuous or categorical variable: eLVH), LAVi max and E/E'
13 ratio were significantly associated with MR progression. In order to avoid overfitting of the models,
14 multivariable analyses were performed including alternatively LAVi max and E/E' ratio. On
15 multivariable analysis age, MR grade, presence of MAD and LVMi emerged as independent predictors
16 of MR progression. When expressed as dichotomous variable, eLVH was also independently
17 associated with MR progression, after adjustment for age, MR grade, presence of MAD and LAVi max
18 (HR 2.251; 95%CI 1.195-4.240; p=0.012). Event-free survival rates in BD population stratified
19 according to MR grade, or the presence of MAD or eLVH are shown in **Figure 4** (panel A-C,
20 respectively).

21 22 **DISCUSSION**

23 The main findings of the present study can be summarized as follows: 1) Patients with BD and MR
24 grade from trivial to mild-to-moderate show early LV and LA remodeling, together with a mild

1 The association between higher LVMI and MR worsening may have important clinical implications,
2 since patients with eccentric LV remodeling may benefit from a tailored follow-up strategy, with closer
3 echocardiographic surveillance and screening of other potential etiologies, including ventricular
4 arrhythmias. Despite chronologically causality may not be ascertained from our study, it is conceivable
5 that eLVH may reflect a more severe disease phenotype, which is also associated with an increased risk
6 of MR progression. Similarly, the presence of MAD may act a predisposing factor for the evolution of
7 MV abnormalities and MR severity, as consequence of the abnormal annular mechanics and increased
8 mechanical stress on the MV apparatus (14).

9 Whether BD patients with less than severe MR and LV remodeling may benefit from an earlier referral
10 for MV intervention may not be ascertained from our study and deserve future specifically-designed
11 investigations.

12 *Limitations*

13
14 Several limitations of the current study should be mentioned. First, this study concerns a retrospective
15 analysis of patients referred to two high-volume tertiary centers and selection bias cannot be fully
16 excluded. Therefore, future prospective studies are warranted to confirm our findings. Accurate grading
17 of MR severity in patients with BD may be challenging, especially in patients with multiple and
18 eccentric jets, with the risk of underestimating MR severity. In our study, the echocardiographic
19 analysis of MR severity was optimized as performed by experts and confirmed after discussion with a
20 second observer and adopting a multiparametric approach. Nevertheless, quantitative parameters of
21 MR severity obtained by CMR imaging would have provided additive diagnostic value. History of
22 paroxysmal AF was not an exclusion criterion for the present study, but its prevalence in our BD cohort
23 was very low (3%) and the statistical analyses were adjusted for this factor. Finally, cardiopulmonary
24 testing was not performed in most of the patients and, thereby, correlating study findings with exercise
25 capacity was not feasible.

1
2
3
4
5
6
7
8
9
10
11
12
13
14
15
16
17
18
19
20
21
22
23
24

CONCLUSION

BD patients without significant MR display early LV and LA remodeling, together with mild impairment of LA reservoir strain, but not of LV function. The presence of eccentric LV remodeling, together with MAD and a higher MR grade, portend an increased risk of MR progression and patients with these features may benefit from a closer follow-up strategy.

Data availability: The data that support the results of this study are available from the corresponding author upon reasonable request.

Funding: none.

Conflict of interest: The department of Cardiology, Heart Lung Center, Leiden University Medical Center, received research grants from Abbott Vascular, Alnylam, Bayer, Bioventrix, Biotronik, Boston Scientific, Edwards Lifescience, GE Healthcare, Medtronic, Medis, Novartis, Pfizer and Pie Medical. J.J.B. received speaker fees from Abbott Vascular. N.A.M. received speaker fees from Abbott Vascular, GE Healthcare, Philips Ultrasound and Omnor.

1 prolapse due to Barlow disease: insights from cardiovascular magnetic resonance. *JACC*
2 *Cardiovasc Imaging*. 2021;14:573–84.

3 9) Adams DH, Rosenhek R, Falk V. Degenerative mitral valve regurgitation: best practice
4 revolution. *Eur Heart J*. 2010;31:1958–66.

5 10) Lancellotti P, Tribouilloy C, Hagendorff A, Popescu BA, Edvardsen T, Pierard LA et al.
6 Recommendations for the echocardiographic assessment of native valvular regurgitation: an
7 executive summary from the European association of cardiovascular imaging. *Eur Heart J*
8 *Cardiovasc Imaging*. 2013;14:611–44.

9 11) Lang RM, Badano LP, Mor-Avi V, Afilalo J, Armstrong A, Ernande L et al. Recommendations
10 for cardiac chamber quantification by echocardiography in adults: an update from the American
11 Society of Echocardiography and the European Association of Cardiovascular Imaging. *Eur*
12 *Heart J Cardiovasc Imaging* 2015;16:233–70.

13 12) Meucci MC, Fortuni F, Gallo X, Bootsma M, Crea F, Bax JJ et al. Left atrioventricular
14 coupling index in hypertrophic cardiomyopathy and risk of new-onset atrial fibrillation. *Int J*
15 *Cardiol*. 2022;363:87–93.

16 13) Nagueh SF, Smiseth OA, Appleton CP, Byrd BF 3rd, Dokainish H, Edvardsen T, et al.
17 Recommendations for the evaluation of left ventricular diastolic function by echocardiography:
18 an update from the American society of echocardiography and the European Association of
19 Cardiovascular Imaging. *Eur Heart J Cardiovasc Imaging*. 2016;17:1321–60.

20 14) Hiemstra YL, Tomsic A, Gripari P, van Wijngaarden AL, van der Pas SL, Palmén M, et al.
21 Evolution from mitral annular dysfunction to severe mitral regurgitation in Barlow's disease.
22 *Interact Cardiovasc Thorac Surg*. 2021;32:506–14.

23 15) Badano LP, Koliás TJ, Muraru D, Abraham TP, Aurigemma G, Edvardsen T, et al.
24 Standardization of left atrial, right ventricular, and right atrial deformation imaging using two-

1 dimensional speckle tracking echocardiography: a consensus document of the
2 EACVI/ASE/Industry Task Force to standardize deformation imaging. *Eur Heart J Cardiovasc*
3 *Imaging*. 2018;19:591–600.

4 16) Asch FM, Miyoshi T, Addetia K, Citro R, Daimon M, Desale S, et al; WASE Investigators.
5 Similarities and differences in left ventricular size and function among races and nationalities:
6 results of the world alliance societies of echocardiography normal values study. *J Am Soc*
7 *Echocardiogr*. 2019;32:1396–1406.e2.

8 17) Thomas L, Marwick TH, Popescu BA, Donal E, Badano LP. Left atrial structure and function,
9 and left ventricular diastolic dysfunction: JACC state-of-the-art review. *J Am Coll Cardiol*.
10 2019;73: 1961–77.

11 18) Wolff R, Uretsky S. Defining the left ventricular base in mitral valve prolapse: impact on
12 systolic function and regurgitation. *Int J Cardiovasc Imaging*. 2020;36:2221–7.

13 19) Ajmone Marsan N, Graziani F, Meucci MC, Wu HW, Lillo R, Bax JJ, et al. Valvular heart
14 disease and cardiomyopathy: reappraisal of their interplay. *Nat Rev Cardiol*. 2023. doi:
15 10.1038/s41569-023-00911-0.

16 20) Roselli C, Yu M, Nauffal V, Georges A, Yang Q, Love K, et al. Genome-wide association
17 study reveals novel genetic loci: a new polygenic risk score for mitral valve prolapse. *Eur Heart*
18 *J*. 2022.

19 21) van Wijngaarden AL, Hiemstra YL, Koopmann TT, Ruivenkamp CAL, Aten E, Schalij MJ, et
20 al. Identification of known and unknown genes associated with mitral valve prolapse using an
21 exome slice methodology. *J Med Genet*. 2020;57:843–50.

22 22) Constant Dit Beaufils AL, Huttin O, Jobbe-Duval A, Senage T, Filippetti L, Piriou N et al.
23 Replacement myocardial fibrosis in patients with mitral valve prolapse: relation to mitral
24 regurgitation, ventricular remodeling, and arrhythmia. *Circulation*. 2021;143:1763–74.

- 1 23) Tremblay-Gravel M, Ichimura K, Picard K, Kawano Y, Dries AM, Haddad F, Lakdawala NK,
 2 Wheeler MT, Parikh VN. Intrinsic atrial myopathy precedes left ventricular dysfunction and
 3 predicts atrial fibrillation in Lamin A/C cardiomyopathy. *Circ Genom Precis Med.* 2023
 4 Feb;16(1):e003480.
- 5 24) Lee AP, Jin CN, Fan Y, Wong RHL, Underwood MJ, Wan S. Functional implication of mitral
 6 annular disjunction in mitral valve prolapse: A Quantitative Dynamic 3D Echocardiographic
 7 Study. *JACC Cardiovasc Imaging.* 2017;10:1424–33.
- 8 25) Delling FN, Rong J, Larson MG, Lehman B, Fuller D, Osypiuk E et al. Evolution of mitral
 9 valve prolapse: insights from the Framingham heart study. *Circulation* 2016;133:1688–95.

11 TABLES

12 **Table 1. Clinical and echocardiographic features of the study population.**

	BD (n=231)	Controls (n=231)	P-value
<u>Clinical variables</u>			
Age (years)	48 ± 15	47 ± 12	0.602
Female gender (n,%)	130 (55)	119 (52)	0.305
Hypertension (n,%)	27 (12)	28 (12)	0.645
Hypercholesterolemia (n,%)	19 (8)	22 (10)	0.822
Diabetes (n,%)	1 (0.5)	6 (3)	0.124
Obesity (n,%)	1 (0.5)	4 (2)	0.372
PAF (n,%)	16 (7)	10 (4)	0.313
CAD (n,%)	3 (1)	3 (1)	0.922
COPD (n,%)	2 (1)	4 (2)	0.469
Creatinine (mg/dl)	0.87 ± 0.19	0.88 ± 0.20	0.816
NYHA functional class			0.999
I/II/III-IV (n)	210/20/0	210/20/0	

Syncope (n,%)	9 (4)	3 (1)	0.141
<u>Echocardiographic variables</u>			
LVEDDi (mm/m ²)	28.1 ± 3.6	25.4 ± 2.9	<0.001
LVEDSi (mm/m ²)	16.7 ± 3.3	15.6 ± 2.6	<0.001
IVS thickness (mm)	9 (8-10)	10 (8-11)	0.053
PW thickness (mm)	9 (8-11)	9 (8-10)	0.329
LVMi (g/m ²)	93 (80-109)	81 (72-93)	<0.001
eLVH (n,%)	66 (29)	17 (7)	<0.001
LVEDVi (ml/m ²)	61 ± 12	51 ± 9	<0.001
LVESVi (ml/m ²)	24 ± 6	20 ± 5	<0.001
LVEF (%)	61 ± 6	61 ± 5	0.314
LVGLS (%)	20.5 ± 2.7	20.2 ± 2.4	0.165
LAVi max (ml/m ²)	35 ± 12	25 ± 8	<0.001
LAVi min (ml/m ²)	17 ± 9	11 ± 5	<0.001
LA sphericity index	0.84 ± 0.11	0.78 ± 0.09	<0.001
LA reservoir strain (%)	31.2 ± 8.0	34.4 ± 7.0	<0.001
E/A ratio	1.2 (0.9-1.5)	1.3 (0.9-1.6)	0.365
E/e' ratio	7.0 (6.0- 8.4)	6.8 (5.7-8.0)	0.082
MV annulus (mm)	34 ± 5	28 ± 3	<0.001
MAD (n,%)	91 (39)	-	-
Mild-to-moderate MR	102 (44)	0 (0)	<0.001
TAPSE (mm)	25 ± 4	24 ± 3	0.002
TV annulus (mm)	32 (30-36)	31 (27-35)	0.001
TR grade (n,%)			0.015
Trivial or mild	224 (97)	231 (100)	
Mild-to-moderate	7 (3)	0 (0)	
TR jet velocity (m/s)	2.2 (2.0-2.4)	2.3 (2.1-2.4)	0.111
PASP (mmHg)	25 (22-29)	26 (22-29)	0.101

1

2 *Abbreviations:* BD: Barlow disease; CAD: coronary artery disease; COPD: chronic obstructive
3 pulmonary disease; IVS: interventricular septum; LA: left atrial; LAVi: indexed LA volume; LV: left
4 ventricular; eLVH: eccentric LV hypertrophy; LVEDDi: indexed LV end-diastolic diameter; LVEDSi:

1 indexed LV end-systolic diameter; LVEDVi: indexed LV end-diastolic volume; LVESVi: indexed LV
2 end-systolic volume; LVEF: LV ejection fraction; LVGLS: LV global longitudinal strain; LVMi:
3 indexed LV mass; MAD: mitral annular disjunction; MV: mitral valve; NYHA: New York Heart
4 Association; PAF: paroxysmal atrial fibrillation; PASP: pulmonary arterial systolic pressure; TR:
5 tricuspid regurgitation; TV: tricuspid valve.

6
7 **Table 2. Multivariable linear regression analyses for LVMi, LVEDVi, LAVi max and LA strain**
8 **in the overall population.**

ACCEPTED MANUSCRIPT

1 *Abbreviations:* BD: Barlow disease; LA: left atrial; LAVi: indexed LA volume; LVEDVi: indexed LV
 2 end-diastolic volume; LVGLS: LV global longitudinal strain; LVMi: indexed LV mass; MAD: mitral
 3 annular disjunction; MR: mitral regurgitation; PAF: paroxysmal atrial fibrillation.

4

5 **Table 3. Uni- and multivariable Cox regressions for MR progression in BD patients.**

	<i>Univariable</i>		<i>Multivariable (1)</i>		<i>Multivariable (2)</i>	
	HR (95%CI)	P	HR (95%CI)	P	HR (95%CI)	P
Age (years)	1.041 (1.019- 1.062)	<0.001	1.041 (1.018- 1.065)	<0.001	1.041 (1.017- 1.066)	<0.001
Male gender	1.464 (0.822- 2.606)	0.195	-	-	-	-
Hypertension	1.589 (0.816- 3.093)	0.173	-	-	-	-
PAF	1.277 (0.536- 2.809)	0.628	-	-	-	-
LVMi (g/m ²)	1.022 (1.010- 1.034)	<0.001	1.015 (1.002- 1.028)	0.020	1.017 (1.004- 1.031)	0.012
LVEDVi (mm/m ²)	1.021 (0.997- 1.045)	0.088	-	-	-	-
LVESVi (mm/m ²)	1.007 (0.961- 1.055)	0.764	-	-	-	-
LVEF (%)	1.025 (0.979- 1.073)	0.294	-	-	-	-
LVGLS (%)	1.014 (0.916- 1.116)	0.784	-	-	-	-

		1.123)					
LAVi (ml/m ²)	max	1.030 (1.009- 1.051)	0.004	-	-	0.998 (0.974- 1.022)	0.849
LAVi (ml/m ²)	min	1.025 (0.997- 1.053)	0.077	-	-	-	-
LA strain (%)		0.994 (0.956- 1.033)	0.750	-	-	-	-
E/e' ratio		1.125 (1.007- 1.258)	0.038	1.021 (0.888- 1.173)	0.772	-	-
Bileaflet MVP		0.978 (0.472- 2.028)	0.953	-	-	-	-
MAD		1.891 (1.085- 3.298)	0.025	1.912 (1.059- 3.452)	0.031	1.865 (1.051- 3.308)	0.033
Mild-moderate MR		2.664 (1-509- 4.704)	0.001	2.312 (1.226- 4.359)	0.007	2.060 (1.108- 3.827)	0.022

1

2 *Abbreviations:* as in figure 1 and 2.

3

4

5

6

7

8

1 **FIGURES LEGEND**

2 **Figure 1. Study flow-chart.**

3 *Abbreviations.* AF: atrial fibrillation; BD: Barlow's disease; FED: fibroelastic deficiency; LVNC: left
4 ventricular non-compaction; MR: mitral regurgitation; MVP: mitral valve prolapse; LVEF: left
5 ventricular ejection fraction.

6
7 **Figure 2. Left-sided chamber remodeling stratified according to MR severity in BD patients.**

8 Asterisks indicate statistical significance (p value <0.05).

9 *Abbreviations:* BD: Barlow disease; LA: left atrial; LAVi max: indexed maximal LA volume; LV: left
10 ventricular; LVEDVi: indexed LV end-diastolic volume; LVMI: indexed LV mass; ns: non significant.

11
12 **Figure 3. Example of echocardiographic measurements in a BD patient.**

13 *Legend.* A-B) Images from a 37-year-old woman with BD and bileaflet MVP are shown. She presented
14 a mild LV and LA dilatation, with eLVH. A MAD is also evident (indicated by yellow arrows). C) MR
15 was graded as mild MR (EROA 14 mm²), with an end-systolic, central jet D) Speckle-tracking analysis
16 revealed an impairment of LA reservoir strain.

17 *Abbreviations.* BD: Barlow's disease; EROA: effective regurgitant orifice area; LA: left atrial; LV: left
18 ventricular; eLVH: eccentric LV hypertrophy; MAD: mitral annular disjunction; MR: mitral
19 regurgitation; MVP: mitral valve prolapse.

20
21 **Figure 4. Kaplan-Meier curves for MR progression according to MR grade, MAD and eLVH**
22 **(panel A-C).**

23 *Abbreviations.* LV: left ventricular; eLVH: eccentric LV hypertrophy; MAD: mitral annular
24 disjunction; MR: mitral regurgitation.

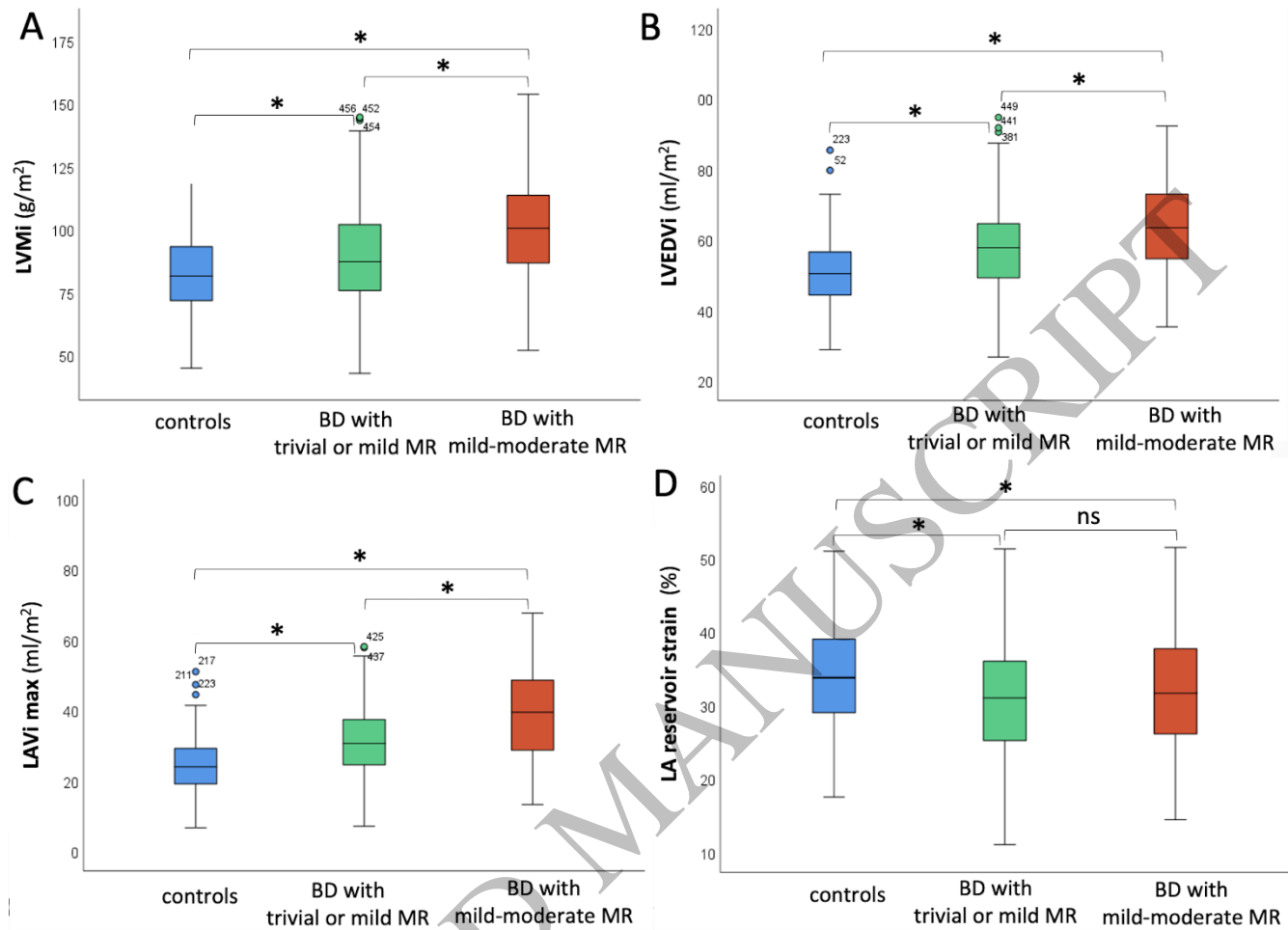


Figure 2
312x225 mm (x DPI)

1
2
3
4

