



Original research

# Endovascular embolization of tentorial dural arteriovenous fistulas (EMBOTENT): a retrospective multicenter study

Dominik F Vollherbst <sup>1</sup>, Nadja Krug,<sup>1</sup> Peng Zhang <sup>2,3</sup>, Yongjie Ma <sup>2,3</sup>, Xin Su <sup>2,3</sup>, Nicola Limbucci,<sup>4</sup> Leonardo Renieri,<sup>4</sup> Pascal J Mosimann,<sup>5</sup> Alexandre Boutet,<sup>5</sup> How-Chung Cheng,<sup>5</sup> Gaultier Marnat <sup>6</sup>, Xavier Barreau <sup>6</sup>, Istvan Szikora <sup>7</sup>, Máté Czencz,<sup>7</sup> Alejandro González,<sup>8</sup> Asier de Albóniga-Chindurza <sup>8</sup>, Luca Scarcia <sup>9</sup>, Erwah Kalsoum,<sup>9</sup> Andrea M Alexandre <sup>10</sup>, Alessandro Pedicelli,<sup>10,11</sup> Raoul Pop <sup>12</sup>, Dan Mihoc,<sup>12</sup> Bettina Serrallach,<sup>13</sup> Tomas Dobrocky <sup>13</sup>, Ansgar Berlis,<sup>14</sup> Christoph Johannes Maurer <sup>14</sup>, Frédéric Clarençon <sup>15</sup>, Kevin Premat,<sup>15</sup> Virginia Pujol Lereis,<sup>16</sup> Diego A Devia,<sup>17</sup> Sara Protto,<sup>18,19</sup> Gwynedd E Pickett <sup>20</sup>, Ivan Lylyk <sup>21</sup>, Kamil Zelenák,<sup>22</sup> Takeshi Morimoto <sup>23</sup>, Fouzi Bala <sup>24</sup>, Mykola Vyval,<sup>25</sup> Rui Carvalho,<sup>26</sup> Davide Simonato,<sup>27</sup> Marios-Nikos Psychogios,<sup>28</sup> Osman Koc,<sup>29</sup> Ajit S Puri,<sup>30</sup> Robert M Starke,<sup>31</sup> Riitta Rautio <sup>32</sup>, Mostafa Ergawy,<sup>33</sup> Jesse Jones <sup>34</sup>, Peter B Sporns <sup>35,36</sup>, Stephan Meckel <sup>37</sup>, Sophia Hohenstatt <sup>1</sup>, Martin Bendszus,<sup>1</sup> Adam A Dmytriw <sup>38,39</sup>, Markus A Möhlenbruch<sup>1</sup>

For numbered affiliations see end of article.

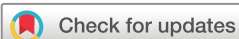## Correspondence to

Prof Dr Dominik F Vollherbst; dominik.vollherbst@med.uni-heidelberg.de

DFV and NK contributed equally.

Received 13 January 2026

Accepted 13 March 2026



© Author(s) (or their employer(s)) 2026. Re-use permitted under CC BY-NC. No commercial re-use. See rights and permissions. Published by BMJ Group.

**To cite:** Vollherbst DF, Krug N, Zhang P, et al. *J NeuroIntervent Surg* Epub ahead of print: [please include Day Month Year]. doi:10.1136/jnis-2026-024970

## ABSTRACT

**Background** Tentorial dural arteriovenous fistulas (TDAVFs) are rare but high risk vascular lesions. Although endovascular embolization is often the preferred treatment, large scale data on efficacy and safety are limited.

**Objective** To investigate the efficacy and safety of endovascular treatment for TDAVFs in a large, retrospective, multicenter cohort, and to analyze lesion characteristics and outcomes according to TDAVF location.

**Methods** Clinical, radiological, and interventional data from 585 patients treated in 32 international centers in 758 endovascular treatment sessions between 2012 and 2022 were analyzed. Patient demographics, fistula characteristics, endovascular treatment techniques, complications, and outcomes were assessed. Efficacy was measured by occlusion rates, safety by symptomatic complications, and modified Rankin Scale (mRS) scores.

**Results** In 31.3% of cases TDAVFs initially presented with hemorrhage, including 12.8% in low grade TDAVFs (absence of cortical venous reflux). Transarterial embolization was the primary approach in 84.7% of sessions. Complete occlusion was achieved in 74.2% of cases after the last treatment and 85.7% at the last imaging follow-up (mean 20.9 months). Symptomatic complications occurred in 9.4% of patients, with 2.6% permanent deficits and 1.0% mortality. At the last clinical follow-up (mean 30.6 months), 89.2% of patients had good functional outcome (mRS score 0–2). Location was significantly associated with fistula grade (eg, galenic and tentorial sinus TDAVFs being more often high grade, and torcular TDAVFs being more often low-grade).

## WHAT IS ALREADY KNOWN ON THIS TOPIC

- ⇒ Tentorial dural arteriovenous fistulas (TDAVFs) represent an aggressive subgroup of dural fistulas and their endovascular treatment is frequently challenging due to complex angioarchitecture.
- ⇒ Evidence regarding endovascular outcomes in TDAVFs remains areis limited.

## WHAT THIS STUDY ADDS

- ⇒ In this international multicenter cohort, embolization showed high efficacy with an acceptable safety profile.
- ⇒ We found a 12.8% hemorrhage rate among low grade TDAVFs without cortical venous reflux (CVR), which are generally considered low risk.
- ⇒ Rates of angiographic occlusion, hemorrhage, and procedural complications did not differ across anatomical locations, but TDAVF location was associated with fistula grade.

## HOW THIS STUDY MIGHT AFFECT RESEARCH, PRACTICE, OR POLICY

- ⇒ This study supports endovascular embolization as a treatment of choice for TDAVFs.
- ⇒ The relatively high hemorrhage rate in low grade TDAVFs suggests that these lesions may warrant treatment, even without CVR.
- ⇒ The observed association between location and grade may contribute to a better understanding of the pathophysiology of TDAVFs and support a more refined risk stratification and treatment planning.

**Conclusions** This large multicenter series demonstrated high occlusion rates, favorable functional outcomes, and acceptable complication rates, supporting endovascular therapy as a treatment of choice for TDAVFs. Considerable hemorrhage rates in low grade TDAVFs support the treatment even in the absence of cortical venous reflux.

**INTRODUCTION**

Intracranial dural arteriovenous fistulas (DAVFs) are acquired vascular lesions characterized by abnormal connections between arterial feeders and dural venous sinuses or cortical veins. This pathological shunting bypasses the capillary network and can result in venous hypertension, often accompanied by neurological deficits, and hemorrhage.<sup>1</sup> Based on the hemorrhagic risk, DAVFs are generally categorized as low grade, associated with no or minimal bleeding risk, and high grade, which may carry an annual risk of up to 20%.<sup>1,2</sup> Cortical venous reflux (CVR) represents the most important risk factor for hemorrhage, and serves as the defining indicator for high grade lesions.<sup>1</sup> Tentorial dural arteriovenous fistulas (TDAVFs) represent a high risk subtype of DAVFs. According to a recent large multicenter study, they are less prevalent than DAVFs located at the transverse/sigmoid sinus, comprising approximately 15% of DAVFs.<sup>3</sup> These TDAVFs frequently manifest with aggressive neurological behavior and progressive deficits, and often carry a high risk of hemorrhage.<sup>4-6</sup> Morphological risk factors for hemorrhage in TDAVFs comprise CVR, deep drainage, and venous varices.<sup>7</sup> For TDAVFs, prompt intervention is usually recommended, even in the absence of hemorrhage or neurological symptoms.<sup>8-10</sup>

Treatment of TDAVFs is often challenging due to their complex angioarchitecture, typically recruiting multiple dural artery feeders. Treatment options include surgical occlusion, radiation therapy, and endovascular treatment, with endovascular embolization increasingly being applied as the primary treatment modality for most TDAVFs.<sup>11-14</sup> Growing understanding of DAVF angioarchitecture, together with advancements in embolic materials and micro- and balloon catheters, now enables precise and effective targeted embolization of the fistula point, even in the complex vascular configurations typical of TDAVFs.<sup>13</sup>

Reported experiences concerning the treatment of TDAVFs are mostly limited to single center studies with small patient cohorts,

due to the relative rarity of these lesions. Only a few studies exist focusing on the endovascular treatment of TDAVFs.<sup>11,12,15-17</sup>

In this retrospective, multicenter study, we aimed to investigate the efficacy and safety of endovascular embolization of TDAVFs, and to analyze lesion characteristics and clinical outcomes according to fistula location.

**MATERIALS AND METHODS**

**Study design**

This observational, retrospective, multicenter study on the endovascular treatment of TDAVFs was conducted across 32 international neurovascular centers. The study period spanned 10 years, from January 1, 2012, to December 31, 2022.

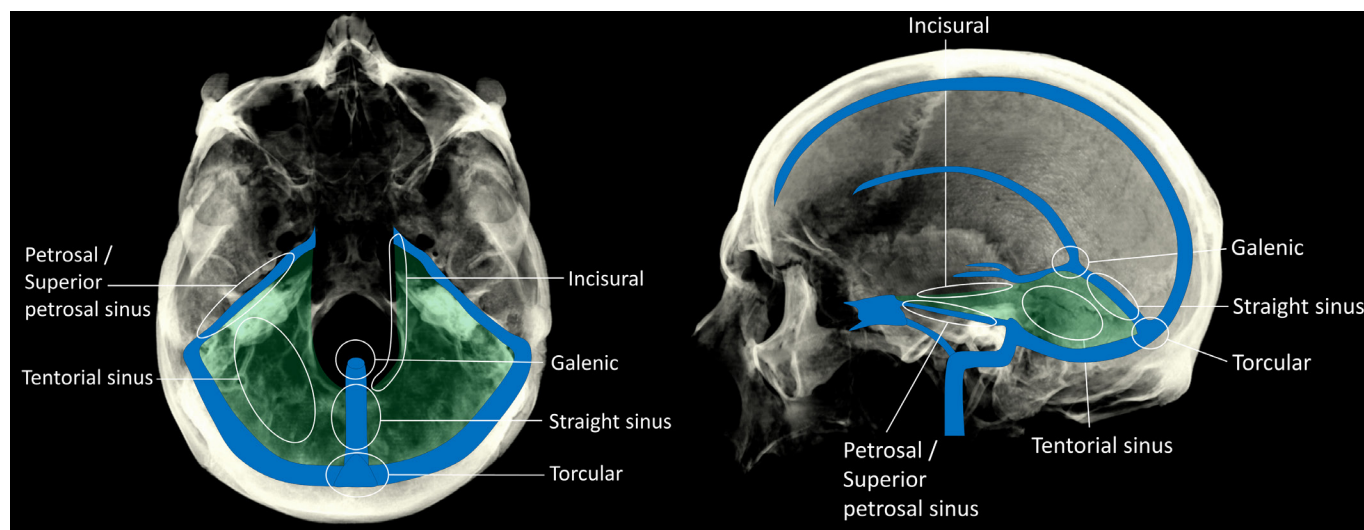
Data collection was based on an electronic survey specifically designed for this study and completed by the treating interventionalists, through which the clinical and radiological records of patients with primarily endovascularly treated TDAVFs were systematically reviewed and analyzed. Data analysis was carried out by a core laboratory blinded to patient identifying information. Radiological imaging analysis was performed by the treating interventionalists and not by a core laboratory.

Institutional review board approval was obtained from the coordinating center (Heidelberg University). Local approval was sought in accordance with institutional regulations at participating centers. The requirement for informed consent was waived due to the retrospective nature of the study.

**Patient, tentorial dural arteriovenous fistula, and treatment characteristics**

Patient characteristics were age, sex, pre-existing comorbidities, initial clinical presentation, and modified Rankin Scale (mRS) scores before and after treatment. The mRS score was assessed 24 hours and 6–12 months after treatment and also at the latest available follow-up.

TDAVF characteristics comprised the presence of TDAVF related intracranial hemorrhage, fistula location, classified according to the six TDAVF subtypes described by Lawton *et al*<sup>7</sup> (galenic, straight sinus, torcular, incisural, tentorial sinus, and petrosal/superior petrosal sinus; figure 1), fistula type according to the Cognard classification,<sup>1</sup> potential etiological factors for TDAVF development (including sinus thrombosis and trauma),



**Figure 1** Schematic illustrations of locations of tentorial dural arteriovenous fistulas.

and the angioarchitecture of the fistula (arterial feeder territories, presence of venous or arterial aneurysms, stenosis of the draining vein, and number of feeding arteries).

Treatment characteristics included the mode of anesthesia, vascular access site (femoral, radial, or brachial), endovascular approach (transarterial, transvenous, or combined), embolic material, use of adjunctive devices, such as balloon catheters or coils, target vessel for embolization, number of treatment sessions, and additional surgical or radiosurgical treatments. The degree of occlusion (no occlusion, partial occlusion <50%, partial occlusion >50%, subtotal occlusion >90%, or complete occlusion) was subjectively assessed by the treating interventionalist based on the estimated relative extent of the remaining fistula network. Periprocedural and postprocedural complications were assessed until discharge and throughout follow-up. The outcome of these complications was classified as asymptomatic, transient, permanent, or fatal.

### Efficacy endpoints

TDAVF occlusion was assessed immediately after the last procedure, at the 6–12 month follow-up, and at the latest follow-up. Follow-up imaging consisted of DSA (preferred), CT, and/or MRI. The primary efficacy endpoint was the rate of complete TDAVF occlusion at the last imaging follow-up.

### Complications

The occurrence of complications was assessed during the periprocedural period, at the 6–12 month follow-up, and at the latest follow-up. The primary safety endpoint was the occurrence of symptomatic complications. Clinical outcome was assessed with the mRS score.

### Statistical analyses

GraphPad Prism (La Jolla, USA; V.13.3.0) was used for all statistical analyses. Quantitative data are presented as mean±SD or as absolute number (relative frequency). Differences in the rates of complete occlusion (complete vs non-complete), hemorrhagic presentation, and treatment related complications between TDAVF locations were assessed using  $\chi^2$  tests across all locations. Likewise, a  $\chi^2$  test was performed to evaluate the distribution of fistula grades (high grade TDAVFs, low grade TDAVFs, and TDAVFs with spinal drainage) across locations. In the event of a significant global association, post hoc analyses were conducted by comparing each location against all others using  $\chi^2$  tests. A P value of 0.05 was defined as the threshold for statistical significance.

## RESULTS

### Patient and tentorial dural arteriovenous fistula characteristics

Patient and TDAVF characteristics are summarized in [table 1](#). Example cases are illustrated in [figures 2 and 3](#).

A total of 585 patients (mean age 57 years; 72.5% men), treated between January 2012 and December 2022 in 758 endovascular treatment sessions, were included in this study. The most frequent comorbidity was arterial hypertension (46.7%). The most frequent symptoms (some patients reported more than one symptom) were headache (51.6%), followed by tinnitus (18.5%) and vertigo (11.5%). Only 17.4% of TDAVFs were asymptomatic. In most cases (83.5%), no underlying cause for the TDAVF was identified, while sinus thrombosis was observed in 11.6% of cases as a probable underlying cause.

The most frequent TDAVF location was the torcular (25.5%), followed by the tentorial sinus (24.8%), the petrosal/superior petrosal sinus (19.7%), and galenic TDAVFs (13.0%). Most TDAVFs were classified as high grade ( $\geq$  type Cognard IIb), observed in 546 patients (93.3%), with the highest proportion being type IV (52.1%) and type III (23.4%). A smaller subset of 39 patients (6.7%) were classified as low grade ( $\leq$  type Cognard IIa). Spinal perimedullary venous drainage (Cognard V) was observed in 5.5% of patients.

The middle meningeal artery (79.7%), occipital artery (65.1%), meningohipophyseal trunk (47.2%), and posterior meningeal artery (45%) were the most frequently involved feeding arteries. Pial arteries (including dural branches of parenchymal arteries) were involved in 37.3%. Among the TDAVFs, 46.3% presented venous aneurysms/varices, 20.7% stenoses of the draining vein(s), and 3.1% with arterial aneurysms.

In 183 patients (31.3%), the TDAVF was ruptured, causing intracranial hemorrhage. Among the 39 patients with low grade TDAVFs (absence of CVR), 5 patients (12.8%) presented with intracranial hemorrhage. Of the type I TDAVFs, which were ruptured, one was located at the torcular, two at the straight sinus, and one was galenic. The ruptured type IIa TDAVF was situated at the torcular. This case is illustrated in [figure 3](#). All of the ruptured low grade TDAVFs demonstrated pial artery supply. No additional anatomical characteristics predisposing to hemorrhage were observed.

### Treatment characteristics

Treatment characteristics and outcome parameters are summarized in [table 2](#).

In total, 758 endovascular treatment sessions were performed. In 78.5%, only one treatment was performed. Additional surgical intervention was necessary in 22 cases, while in only 6 cases additional radiation therapy was performed. Most patients (98.0%) were treated under general anesthesia and via transfemoral access (96.8%). Transarterial embolization was the primary treatment technique in 84.7% of treatment sessions, transvenous access was used in 5.8%, and combined transarterial and transvenous access during the same session in 8.4%. Apart from liquid embolic agents, supplementary devices were used in 22.4% of cases (16.1% transarterial and transvenous balloon assisted embolization and 6.3% coiling).

The two most frequently used embolic agents were Onyx (Medtronic Neurovascular, Irvine, California, USA; 66.6%) and cyanoacrylates (20.3%). PHIL (Terumo Neuro, Aliso Viejo, USA) was used in 5.8% and Squid (Balt, Montmorency, France) in 5.3%. Multiple embolic agents were used in 12.3% of patients. The most common number of embolized target vessels was one (59.0%), followed by two (23.0%). The main feeding artery chosen for embolization was the middle meningeal artery (50.1%), followed by the occipital artery (23.5%), and the posterior meningeal artery (10.4%). Pial arteries were embolized in 17.8% of sessions.

### Efficacy endpoints

After the first treatment, complete, subtotal (>90%), and partial (50–90%) occlusion rates were 65.0%, 10.1%, and 13.9%, respectively. Immediately after completion of the final treatment, complete occlusion was achieved in 74.2% of cases, increasing to 81.4% at the 6–12 month follow-up. At the latest imaging follow-up, complete occlusion was observed in 85.7% of patients. Of patients with available imaging follow-up, DSA was available in 69.8% of cases. In this subgroup of 331 patients with available post-interventional DSA, which was performed

**Table 1** Patient and tentorial dural arteriovenous fistula characteristics

Patient characteristics							
No of patients	585						
Age (years) (mean±SD (range))	57±14.1 (1–91)						
Sex (women:men) (%)	27.5:72.5						
Comorbidities (%)	Arterial hypertension 46.70	Cardiovascular disease 18.30			Diabetes mellitus type 2 13.30	Family history of DAVF 0.40	
Symptoms (%)*	Headache 51.60	Tinnitus 18.50			Vertigo 11.50	Paresis 11	
	Visual disturbances 8.90	Seizure 6.20			Asymptomatic 17.40		
Suspected underlying cause for DAVF (%)	Unknown 83.50	Thrombosis 11.60			Trauma 3.20	Others 1.80	
Baseline mRS (%)	Score 0 36.90	Score 1 31.70	Score 2 15.90	Score 3 6.60	Score 4 4.30	Score 5 4.70	
DAVF characteristics							
Hemorrhage (%)†	Yes 31.30				No 68.70		
Location (%)	Torcular 25.50	Tentorial sinus 24.80			Petrosal/SPS 19.70	Galenic 13.00	
	Straight sinus 8.70	Incisural 8.00			Other 0.30		
Cognard type (%)	I 2.60	IIa 4.10	IIb 2.40	IIa+b 9.90	III 23.40	IV 52.10	V 5.50
Involved arterial feeder territories (%)	Middle meningeal a 79.70	Occipital a 65.10			MHT 47.20	Posterior meningeal a 45	
	Ascending pharyngeal a 20.90	Superficial temporal a 8.70			Pial artery supply 37.30		
Additional findings (%)	Venous aneurysms/varices 46.3	Stenosis of draining vein 20.7			Arterial aneurysms‡ 3.1		
No of feeding arteries (%)§	1–5 feeders 42.3	6–10 feeders 28.8			>10 feeders 28.8%		
*Some patients reported more than one symptom. †Hemorrhage occurred in 183 patients. ‡Directly related to the fistula. §>10 mm in length, measured from the fistula point. DAVF, dural arteriovenous fistulam; MHT, meningohypophyseal trunk; mRS, modified Rankin Scale; SPS, superior petrosal sinus.							

at a mean of 13±16 months after the final treatment session, complete occlusion was observed in 87.0% of cases. Mean time from last treatment to latest imaging follow-up was 20.9 months. Recurrence of TDAVFs during follow-up after initial complete occlusion was observed in 5.3%. During follow-up, three new TDAVFs were identified at separate locations, distant to the initially treated lesions.

**Complications and clinical outcome**

A total of 71 symptomatic complications occurred in 758 interventions, corresponding to an overall symptomatic complication rate of 9.4%. The most frequently observed events included intracranial hemorrhage (2.4%), ischemic infarction (1.9%), post-interventional hydrocephalus (0.8%), as well as cranial nerve palsy (0.9%) and visual disturbances (0.8%). Further complications comprised post-interventional headache (0.7%), nausea (0.7%), and vertigo (0.7%). Less common adverse events were transient cardiac arrest, most likely attributable to the trigemino-cardiac reflex (0.3%), and retroperitoneal hematoma (0.3%).

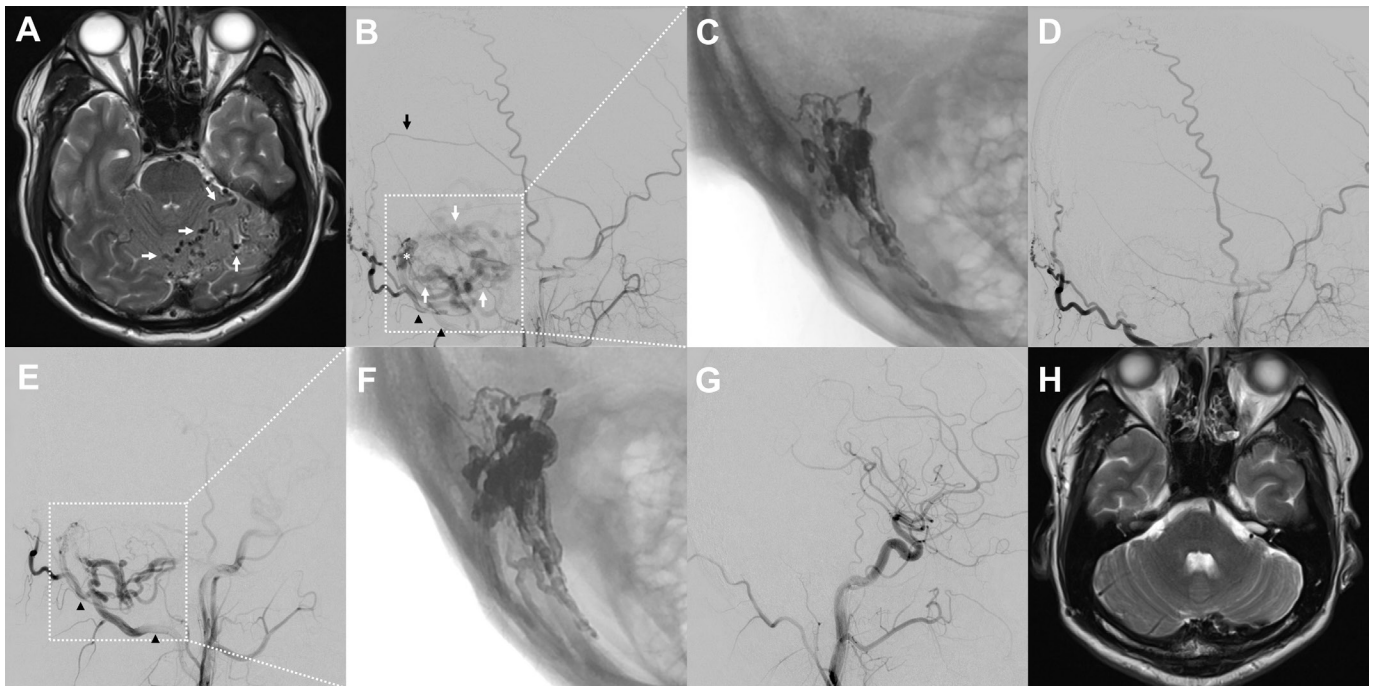
Regarding the outcome of these events, 53.5% of complications were transient, 28.2% resulted in permanent deficits,

and 8.5% were fatal, while in 9.9% of cases the outcome was not documented. This corresponds to an overall rate of permanent deficit of 2.6% (relative to the number of treatments), and an overall mortality rate of 1.0% (relative to the number of patients). Among the six fatal events, five were associated with peri-interventional or post-interventional hemorrhage, two of which occurred in patients who had pre-existing hemorrhage, and one was associated with ischemic stroke.

The mean interval between the most recent treatment and the latest clinical follow-up was 30.6 months. At the last follow-up, 89.1% of patients had a good clinical outcome (mRS score 0–2). Compared with baseline, 42.7% of patients demonstrated improvement in mRS, 43.4% remained unchanged, and 13.9% experienced worsening.

**Differences between tentorial dural arteriovenous fistula locations**

Comparison of occlusion, hemorrhage, and complication rates between locations is summarized in table 3. No statistically significant difference was found regarding the rate of complete occlusion, hemorrhage, or complications between the different TDAVF locations (table 3). The highest rate of complete



**Figure 2** Example case of a 41-year-old man who presented with nausea. (A) Brain MRI (T2 weighted imaging) demonstrated a high grade tentorial dural arteriovenous fistula (TDAVF) at the tentorial sinus with ectatic cerebellar veins (white arrows). (B) DSA confirmed the diagnosis and delineated the angioarchitecture, revealing arterial feeders from the middle meningeal artery (black arrow) and the occipital artery (black arrowheads), converging at the fistula point (white asterisk) with venous drainage into dilated cerebellar veins (white arrows). Complete angiographic occlusion was achieved by transarterial embolization with Squid 18 via the petrosquamosal branch of the middle meningeal artery (black arrow). The embolic agent cast is shown in (C), and the final angiogram demonstrated no residual shunt (D). Follow-up angiography at 6 months revealed recurrence of the TDAVF, predominantly supplied by the occipital artery (arrowheads in E). Repeat embolization was performed using Squid 18 via a mastoid branch of the occipital artery, resulting in complete angiographic occlusion (embolic agent cast in F). Durable occlusion was confirmed on DSA 6 months after the second intervention (G) and on MRI 2 years after the initial treatment (H).

occlusion (74.5%), hemorrhage (40.4%), and complications (19.1%) were observed for incisural TDAVFs. The lowest complete occlusion and lowest hemorrhage rates were observed for galenic TDAVFs (55.3% and 25.0%, respectively), while the lowest rate of complications was observed for TDAVFs located at the straight sinus (5.9%).

Comparison of fistula grades between locations is summarized in table 4. The global  $\chi^2$  test demonstrated a significant association between TDAVF location and fistula grade ( $P < 0.0001$ ). Post hoc analyses showed that galenic and tentorial sinus TDAVFs were more frequently high grade compared with all other locations ( $P = 0.0397$  and  $P = 0.0400$ , respectively), whereas torcular TDAVFs were more frequently low grade ( $P = 0.0050$ ). Petrosal/superior petrosal sinus TDAVFs were significantly more frequently associated with spinal perimedullary venous drainage ( $P < 0.001$ ).

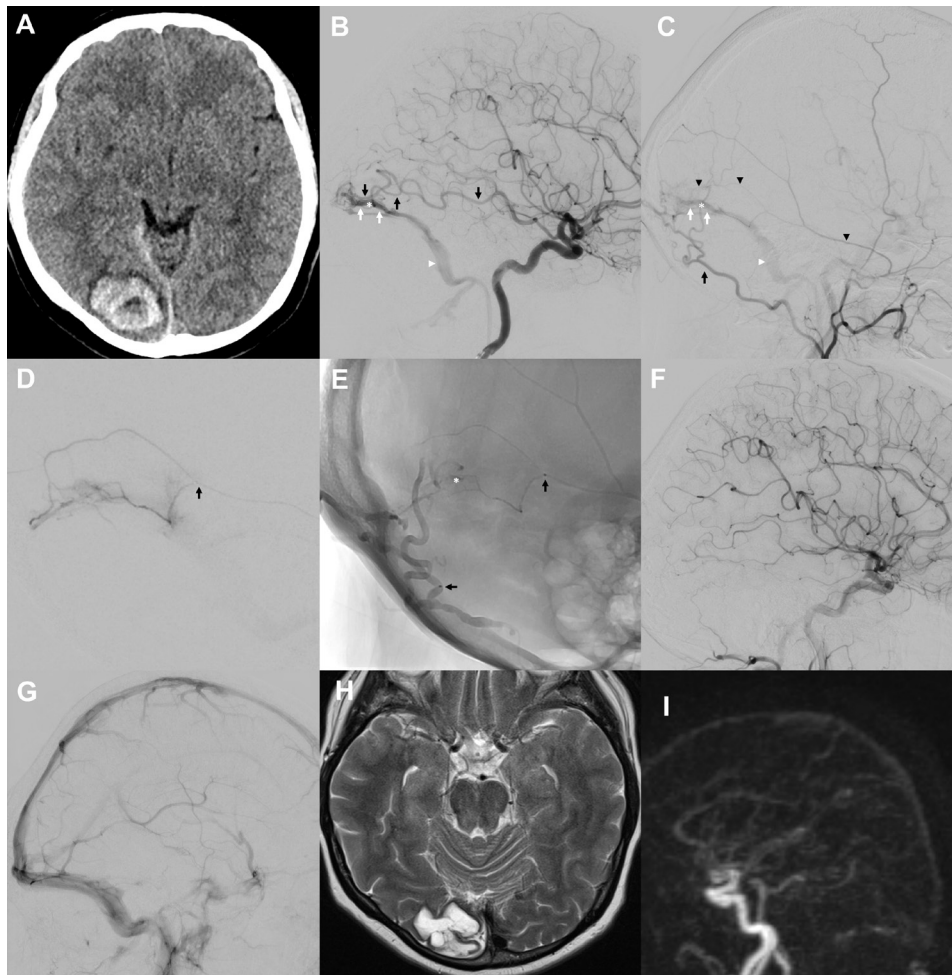
## DISCUSSION

The results of this retrospective multicenter study demonstrate the effectiveness and safety of endovascular embolization of TDAVFs. To the best of our knowledge, this represents the largest investigation to date focusing on the endovascular treatment of TDAVFs, including a subgroup analysis based on the anatomical locations of TDAVFs, as classified by Lawton *et al.*<sup>7</sup> This subanalysis revealed a significant association between location and fistula grade, but no association with hemorrhagic presentation, occlusion rates, or complications.

In our study, 31.3% of TDAVFs initially presented with intracranial hemorrhage, which highlights the highly aggressive nature

of this subtype of DAVF, and aligns with findings from other studies, reporting rates of 22.5–37.8%.<sup>11–15,16</sup> In comparison, the Japanese Registry of Neuroendovascular Therapy (JR-NET3), which included 1458 patients, reported an overall hemorrhage rate of 15% for DAVFs located in various regions.<sup>6</sup> In our study, TDAVFs located in the incisural region (40.4%) and at the tentorial sinus (37.2%) exhibited the highest hemorrhage rates, but without significant differences between the groups.

Low grade DAVFs, defined as DAVFs without CVR, are generally considered to carry no or only minimal risk of hemorrhage.<sup>1–18</sup> However, in our cohort, 13% of low grade TDAVFs presented with hemorrhage, indicating that this assumption may not fully apply to tentorial lesions. These ruptured low grade lesions lacked any additional known angioarchitectural hemorrhagic risk factor, such as arterial or venous aneurysms. In cases with complex angioarchitecture, it is conceivable that a thrombosed or angiographically occult venous structure with CVR may not be visualized at the time of diagnosis, potentially leading to misclassification of a high grade fistula as low grade. Interestingly, all of the ruptured low grade fistulas exhibited an involvement of supplying pial arteries, highlighting their potential special role in TDAVFs. Previous studies by Su *et al* and Brinjikji *et al* have similarly reported increased hemorrhage rates in DAVFs with a pial arterial supply.<sup>19–20</sup> Future investigations should systematically evaluate the association between pial supply and hemorrhagic presentation in TDAVFs, as this may guide risk stratification and therapeutic decision making. It should be noted that our study did not assess whether these feeders represented truly pure pial feeders or dilated pre-existing dural branches arising from



**Figure 3** Example case of a 49-year-old woman who presented with a right sided occipital intracerebral hemorrhage (non-enhanced CT at admission, A). Angiograms of the internal (B) and external (C) carotid arteries demonstrated a tentorial dural arteriovenous fistula (TDAVF) at the torcular, supplied by feeders from the middle meningeal (black arrowheads in C), occipital (black arrow in C), and posterior cerebral arteries (black arrows in B), with antegrade and retrograde venous drainage into a venous channel, representing the fistula point (white asterisk in B, C, and E), draining the sinus without cortical venous reflux, consistent with a low grade dural arteriovenous fistula. Endovascular embolization was performed through these feeders (black arrow marking the catheter tip in the middle meningeal artery and in the occipital artery in D and E) from three positions using PHIL LV and PHIL 35%. The embolic agent cast after embolization is visible in (E). Embolization resulted in complete angiographic occlusion (F) without complications, and with patency of the venous sinuses and major draining veins (G). MRI follow-up at 2 years (T2 weighted imaging, H; MR angiography, I) confirmed persistent complete occlusion of the TDAVF.

pial arteries, each characterized by a distinct angioarchitecture, as described by Osada and Krings.<sup>21</sup> Given the increased risk of rupture of these low grade lesions, TDAVFs without CVR, unlike those in other locations (eg, lateral sinus DAVFs), may warrant treatment even in the absence of CVR. A more detailed characterization of angioarchitectural factors predisposing low grade TDAVFs to rupture is needed.

Complete occlusion at the end of the last treatment session, at the 6–12 month follow-up, and at the latest imaging follow-up was achieved in 74%, 81%, and 86% of patients, respectively. These results are in line with reported occlusion rates in the literature. The largest single center study on TDAVF treatment, which was conducted by Su *et al*,<sup>15</sup> included 275 cases of TDAVFs, of which 219 cases underwent endovascular therapy, 32 cases received microsurgical therapy, and 12 cases were treated with a combination of both approaches. This study reported an immediate occlusion rate of 92.8% after these different therapeutic approaches. In a retrospective single center study, Zhang *et al*<sup>11</sup> reported their findings following predominantly endovascular treatment of 83 patients with TDAVFs. In

this cohort, two patients required microsurgery, and five patients underwent additional gamma knife therapy. The immediate occlusion rate after the final endovascular procedure was 89.1%, while the angiographic complete occlusion rate 6 months after the last treatment was 91.2%. Another retrospective study, by Rezende *et al*,<sup>16</sup> analyzed 45 patients presenting with TDAVFs who also mainly received endovascular treatment, performed in two centers. In this study, immediate angiography after the first treatment showed complete occlusion in 82.2% of cases and after the last treatment in 97.8%. After 6 months of follow-up of 42 patients, 100% of TDAVFs were occluded.

Interestingly, we observed a notable increase in complete occlusion rates over time, increasing from 74% at the end of the last treatment session to 86% at the latest follow-up imaging. This rate of delayed occlusion appears relatively high in comparison with the above mentioned previous studies, where more modest increases have been reported. On review of our data, we did not identify any consistent angiographic, technical, or clinical factors that would account for this finding. It remains possible that progressive thrombosis of

Table 2 Treatment characteristics and outcome parameters

Treatment characteristics								
No of treatments*	758							
Endovascular treatments per DAVF (%)*	1 treatment 78.5	2 treatments 14.8			≥3 treatments 6.7			
Artery selected for embolization (%)	Middle meningeal a 50.1	Occipital a 23.5	Posterior meningeal a 10.4	MHT 4.9	Ascending pharyngeal a 1.9	Pial a 17.8		
Access (%)	Femoral 96.8		Radial 1.7		Brachial 0.3			
Mode of anesthesia (%)	General anesthesia 98.0		Sedation 0.5		Local anesthesia 0.5			
Accessory devices (%)	Balloon assisted embolization† 16.1			Coiling‡ 6.3				
Approach (%)	Transarterial 84.7	Transvenous 5.8		Combined (transarterial+transvenous) 8.4				
Embolic agents (%)	Onyx 66.6	Cyanoacrylate 20.3	PHIL 5.8	Squid 5.3	Menox 0.3	PVA 0.3	Microspheres 0.3	Multiple agents 12.3
No of embolized target vessels (%)	1 59.0	2 23.0	3 10.0	4 2.0		5 1.0	6 0.1	
Morbidity and adverse events§								
mRS score 24 hours (±12 hours) after treatment (%)	0 35.9	1 34.8	2 9.1	3 6.1	4 4.1	5 5.2	6 0.8	
mRS score at 6–12 month clinical follow-up (%)	0 58.2	1 24.4	2 7.3	3 4.2	4 1.6	5 1.4	6 2.8	
mRS score at latest follow-up (%)¶	0 57.3	1 23.8	2 8.1	3 3.8	4 2.8	5 1.0	6 3.2	
mRS change (%)	Stable 43.4			Improvement 42.7	Worsening 13.9			
Complication rate (%)	Overall 9.4							
Specification of complications (%)	Intracranial hemorrhage 2.4		Infarction 1.9	Cranial nerve palsy 0.9	Hydrocephalus 0.8			
Outcome of complications (%)	Transient 53.5		Permanent 28.2		Death 8.5		Not specified 9.9	
Degree of DAVF occlusion								
Degree of occlusion after first treatment (%)	Complete occlusion 65.0	Subtotal occlusion >90% 10.1	Partial occlusion >50% 13.9		Partial occlusion <50% 8.3		No occlusion 2.8	
Degree of occlusion after last treatment (%)	Complete occlusion 74.2	Subtotal occlusion >90% 14.6	Partial occlusion >50% 7.0		Partial occlusion <50% 2.6		No occlusion 1.6	
Degree of occlusion at 6–12 month follow-up (%)**	Complete occlusion 81.4	Subtotal occlusion >90% 10.2	Partial occlusion >50% 6.4		Partial occlusion <50% 1.2		No occlusion 0.7	
Degree of occlusion at latest imaging follow-up (%)††	Complete occlusion 85.7	Subtotal occlusion >90% 7.0	Partial occlusion >50% 5.3		Partial occlusion <50% 1.5		No occlusion 0.5	
Modality of latest imaging follow-up (%)	DSA 40.4	MRI 43.1	CT 5.4	DSA+MRI 10.0		DSA+CT 0.2	MRI+CT 1.0	
Recurrence of DAVF during follow-up (%)‡‡	No 94.7				Yes 5.3			
*Endovascular treatments. †Protection of a healthy brain supplying artery or draining vein to avoid inadvertent embolization. ‡Transvenous coiling of the draining vein or arterial feeder. §Relative frequencies indicated related to the number of treatments (n=772). ¶Latest clinical follow-up was available for 496 patients. **Imaging follow-up after 6–12 months was available for 404 patients. ††Latest imaging follow-up was available for 413 patients (mean 20.9 months, maximum 135 months). ‡‡After initial complete occlusion of DAVF. DAVF, dural arteriovenous fistula; MHT, meningohypophyseal trunk; mRS, modified Rankin Scale.								

**Table 3** Comparison of occlusion, hemorrhage, and complication rates between tentorial dural arteriovenous fistula locations

Variable	Galenic	Straight sinus	Torcular	Tentorial sinus	Petrosal/SPS	Incisural	P value
Complete occlusion*	42 (55.3)	35 (68.6)	80 (53.7)	93 (64.1)	67 (58.3)	35 (74.5)	0.07
Hemorrhage†	19 (25.0)	14 (27.5)	47 (31.5)	54 (37.2)	29 (25.2)	19 (40.4)	0.16
Complications	9 (11.8)	4 (7.8)	16 (10.7)	21 (14.5)	11 (9.6)	10 (21.3)	0.28

Values are number (%).  
 \*At latest imaging follow-up.  
 †Initial presentation of dural arteriovenous fistula.  
 SPS, superior petrosal sinus.

small residual shunts may occur more frequently in TDAVFs than in dural fistulas at other locations, potentially due to their distinct angioarchitectural and hemodynamic features. While this phenomenon warrants further investigation, it must not be misconstrued as justification for subtotal embolization. On the contrary, complete angiographic occlusion at the time of treatment remains the primary therapeutic goal, particularly in high grade TDAVFs, to definitively prevent hemorrhagic complications.

In our cohort, the overall complication rate was 9.4%, which is slightly lower than has been reported in other studies, where complication rates were 13–16%.<sup>11 15 16</sup> The rates of permanent deficits (2.6%) and mortality (1.0%) were relatively low in our study, especially regarding the aggressive nature of TDAVFs. In our study, complications were most frequently observed in TDAVFs of the incisural region and at the tentorial sinus, but there were no statistically significant differences between the locations. In the JR-NET3 study, the overall complication rate for different DAVF locations was 7.7%, while the rate of DAVFs located at the tentorium (15.3%), anterior cranial fossa (22.2%), and craniocervical junction (15.8%) was significantly higher than in other regions.<sup>6</sup>

Concerning clinical outcomes in our study, 43% of patients showed improvement in mRS scores, 43% remained stable, and 14% experienced worsening, while at the latest follow-up, 89% of patients achieved a good functional outcome. Similar results were demonstrated in other studies with mRS scores of 0–2 (89.1% reported by Zhang *et al*<sup>11</sup> and 82.6% by Su *et al*<sup>15</sup>).

Recurrence after complete angiographic occlusion is a known concern in the treatment of DAVFs. In our cohort of TDAVFs, we observed a recurrence rate of 5.3%, which is lower than the 7% overall recurrence rate across all DAVF locations reported in a large multicenter study by Abecassis *et al*, and notably lower than the 17% recurrence they observed specifically in DAVFs in tentorial location.<sup>22</sup> Thus we were not able to confirm the elevated recurrence rate for TDAVFs reported in their series.

In our study, we examined, for the first time in a large cohort of patients with TDAVFs, whether different fistula locations correlated with fistula grade (venous drainage pattern) and key clinical outcomes such as complete occlusion after endovascular treatment, hemorrhagic presentation, and complication rates. There were no statistically significant differences in the rates of complete occlusion, hemorrhage at presentation, or treatment related complications between the various TDAVF locations. However, an interesting observation was that incisural TDAVFs had the highest rates of complete occlusion, hemorrhagic presentation, and complications among all analyzed subtypes, highlighting a special profile for this location, despite the lack of statistical significance. This trend underlines the distinctive nature of incisural TDAVFs and suggests that this subgroup might warrant further focused investigation in future studies.

Moreover, we observed a significant association between TDAVF location and fistula grade. Post hoc analysis revealed that galenic and TDAVFs located at the tentorial sinus were significantly more often high grade lesions, torcular TDAVFs were significantly more often low grade, and petrosal/superior petrosal sinus TDAVFs were significantly more frequently associated with spinal perimedullary venous drainage (Cognard type V). These patterns shed new light on the angioarchitecture and grading of these rarer TDAVF subtypes and could be of clinical importance when assessing their risk and managing treatment strategies.

The study had several limitations. First, its retrospective design inherently carries a risk of incomplete data capture and reporting bias. Second, the analysis and reporting of angiographic and clinical outcomes were performed by the treating interventionalists themselves, without independent core laboratory adjudication, which may have introduced subjectivity. Third, a substantial proportion of patients did not undergo DSA for follow-up assessment but were instead evaluated by MRI. This may have limited the precision in detecting residual shunts or recurrence, potentially affecting the accuracy of occlusion estimates. However, in the subgroup of patients with follow-up DSA, the complete occlusion rate was 87.0%, which

**Table 4** Comparison of fistula grades between tentorial dural arteriovenous fistula (TDAVF) locations

Variable	Galenic	Straight sinus	Torcular	Tentorial sinus	Petrosal/SPS	Incisural	P value*
High grade TDAVFs	73 (96.0)	46 (90.2)	126 (84.6)	136 (94.4)	87 (76.0)	44 (95.7)	<0.0001
Low grade TDAVFs	3 (4.0)	4 (7.8)	18 (12.1)	5 (3.5)	8 (7.0)	1 (2.2)	
TDAVFs with spinal peri-medullary drainage	0 (0)	1 (2.0)	5 (3.4)	4 (2.8)	20 (17.5)	2 (4.3)	
P value†	0.038	0.493	0.005	0.040	<0.001	0.381	

Values are number (%).  
 \*Global  $\chi^2$  test to compare the distribution of fistula grades.  
 †Post hoc  $\chi^2$  tests of each location vs all other locations.  
 SPS, superior petrosal sinus.

was similar to the overall cohort rate of 85.7%. This may indicate that the lack of uniform DSA follow-up did not markedly affect the overall occlusion estimate. Finally, most participating centers were academic high volume neurovascular institutions, potentially leading to selection bias toward more complex or aggressive TDAVFs and limiting generalizability to smaller or non-tertiary centers.

## CONCLUSIONS

This large multicenter series on the endovascular embolization of TDAVFs demonstrated high long term occlusion rates, favorable functional outcomes, and acceptable complication rates. The occurrence of hemorrhage in low grade TDAVFs supports considering treatment even for lesions without cortical venous drainage. While no association was found between TDAVF location and rates of occlusion, hemorrhage, or complications, significant associations between location and fistula grade were identified, which may be clinically relevant for risk assessment and management.

## Author affiliations

<sup>1</sup>Department of Neuroradiology, Heidelberg University Hospital, Heidelberg, Germany

<sup>2</sup>Department of Neurosurgery, Xuanwu Hospital, Capital Medical University, Beijing, China

<sup>3</sup>China International Neuroscience Institute (CHINA-INI), Beijing, China

<sup>4</sup>Department of Interventional Neuroradiology, Careggi University Hospital, Florence, Italy

<sup>5</sup>Division of Neuroradiology, JDMI, UMIT, and University of Toronto, Toronto Western Hospital, Toronto, Ontario, Canada

<sup>6</sup>Neuroradiology Department, Bordeaux University Hospital, Bordeaux, France

<sup>7</sup>Department of Neurosurgery and Neurointerventions, Semmelweis University, Budapest, Hungary

<sup>8</sup>Department of Interventional Neuroradiology, University Hospital Virgen del Rocío, Seville, Spain

<sup>9</sup>Department of Neuroradiology, Henri Mondor Hospital, Créteil, France

<sup>10</sup>UOSD Neuroradiologia Interventistica, Fondazione Policlinico Universitario A. Gemelli IRCCS, Rome, Italy

<sup>11</sup>Università Cattolica del Sacro Cuore, Rome, Italy

<sup>12</sup>Interventional Neuroradiology Department, Strasbourg University Hospitals, Strasbourg, France

<sup>13</sup>Institute of Diagnostic and Interventional Neuroradiology, Inselspital, Bern University Hospital, and University of Bern, Bern, Switzerland

<sup>14</sup>Department of Diagnostic and Interventional Neuroradiology, University Hospital Augsburg, Augsburg, Germany

<sup>15</sup>Interventional Neuroradiology, Pitié-Salpêtrière University Hospital, Paris, France

<sup>16</sup>Department of Neurology, Vascular Neurology Division, Institute of Neurological Research, FLENI, Buenos Aires, Argentina

<sup>17</sup>Department of Neurosurgery, Pontifical Xaverian University and Hospital Universitario San Ignacio, Bogotá, Colombia

<sup>18</sup>Monash Neurointerventional Radiology, Monash Medical Centre, Melbourne, Victoria, Australia

<sup>19</sup>Interventional Radiology, Department of Radiology, Sant'Anna Hospital, Como, Italy

<sup>20</sup>Division of Neurosurgery, Department of Surgery, Dalhousie University, Halifax, Nova Scotia, Canada

<sup>21</sup>Department of Interventional Neuroradiology and Neurosurgery, Instituto Médico ENERI Clínica La Sagrada Familia, Jose Hernandez, Buenos Aires, Argentina

<sup>22</sup>Clinic of Radiology, Comenius University's Jessenius Faculty of Medicine and University Hospital, Martin, Slovakia

<sup>23</sup>Department of Data Science, Hyogo Medical University, Nishinomiya, Japan

<sup>24</sup>Department of Diagnostic and Interventional Neuroradiology, Tours University Hospital, Tours, France

<sup>25</sup>Scientific-Practical Centre of Endovascular Neuroradiology NAMS of Ukraine, Kyiv, Ukraine

<sup>26</sup>Interventional Neuroradiology Department, ULS São José, Hospital São José, Lisboa, Portugal

<sup>27</sup>Department of Neuroradiology, Oxford University Hospital NHS foundation Trust, Nuffield Department of Clinical Neurosciences, University of Oxford, Oxford, UK

<sup>28</sup>Department of Neuroradiology, University Hospital Basel, Basel, Switzerland

<sup>29</sup>Department of Radiology, Necmettin Erbakan University, Meram Medical Faculty, Meram, Turkey

<sup>30</sup>Division of Neurointerventional Radiology, Department of Radiology, University of Massachusetts Medical Center, Worcester, Massachusetts, USA

<sup>31</sup>Department of Neurological Surgery, Radiology, Neurosciences, Pharmacology,

University of Miami School of Medicine, Miami, Florida, USA

<sup>32</sup>Department of Interventional Radiology, Turku University Hospital and University of Turku, Turku, Finland

<sup>33</sup>Section of Interventional Neuroradiology, University Hospital of Münster, Münster, Germany

<sup>34</sup>Departments of Neurosurgery and Radiology, University of Alabama at Birmingham School of Medicine, Birmingham, Alabama, USA

<sup>35</sup>Department of Neuroradiology, University and University Hospital Basel, Basel, Switzerland

<sup>36</sup>Department of Radiology and Neuroradiology, Stadtspital Zürich, Zürich, Switzerland

<sup>37</sup>Institute of Diagnostic and Interventional Neuroradiology, RKH Kliniken Ludwigsburg, Ludwigsburg, Germany

<sup>38</sup>Neuroendovascular Program, Massachusetts General Hospital and Brigham and Women's Hospital, Harvard Medical School, Boston, Massachusetts, USA

<sup>39</sup>Neurointerventional and Neuroanalytics Consortium (NAN-C), School of Medicine, Toronto Metropolitan University, Toronto, Ontario, Canada

**Contributors** DFV and MAM designed the study. All authors analyzed and interpreted data for the work. DFV and NK drafted the manuscript. All authors approved the final manuscript. DFV is the guarantor of this work.

**Funding** The authors have not declared a specific grant for this research from any funding agency in the public, commercial, or not-for-profit sectors.

**Competing interests** DFV reports consultancy for Medtronic Neurovascular, and paid lectures for TerumoNeuro and Balt. NL reports paid consultations for Medtronic, Balt, Penumbra, Acandis, Stryker, and Microvention. LR reports paid consultations for Medtronic, Balt, Penumbra, Acandis, and Stryker. GM received consulting honoraria from TerumoNeuro, Balt, Stryker, Sim and Cure, and Perfuze, and paid lectures from Penumbra, Wallaby Phenox, Bracco, and Medtronic. IS reports a consulting agreement with Stryker and Medtronic. AMA and AP received educational grants from Medtronic, Stryker, Balt, and Microvention/Terumo (unrelated to the current study). RR reports consulting agreements with Stryker, Balt, Medtronic, and Microvention. SM serves as a consultant for Acandis, Balt, Medtronic, and Stryker, and as a proctor for Balt, has received travel/meeting support from Balt and Medtronic, paid lectures from Balt, Medtronic, Stryker, and Penumbra, is a member of the scientific advisory board for Novartis Pharma GmbH, and serves as a speaker for certification courses of DeGIR/DGNR. MAM has received consulting honoraria, speaker honoraria, and travel support outside this work from Codman, Covidien/Medtronic, MicroVenton, Phenox, and Stryker.

**Patient consent for publication** Not applicable.

**Ethics approval** This study involves human participants. Institutional review board approval was obtained from the coordinating center (Heidelberg University, reference No: S\_247\_2009). Local approval was sought in accordance with institutional regulations at participating centers. The requirement for informed consent was waived due to the retrospective nature of the study.

**Provenance and peer review** Not commissioned; externally peer reviewed.

**Data availability statement** All data relevant to the study are included in the article or uploaded as supplementary information.

**Open access** This is an open access article distributed in accordance with the Creative Commons Attribution Non Commercial (CC BY-NC 4.0) license, which permits others to distribute, remix, adapt, build upon this work non-commercially, and license their derivative works on different terms, provided the original work is properly cited, appropriate credit is given, any changes made indicated, and the use is non-commercial. See: <https://creativecommons.org/licenses/by-nc/4.0/>.

## ORCID iDs

Dominik F Vollherbst <https://orcid.org/0000-0002-8992-4757>

Peng Zhang <https://orcid.org/0000-0001-8344-101X>

Yongjie Ma <https://orcid.org/0000-0001-8136-1753>

Xin Su <https://orcid.org/0009-0004-5324-2545>

Gaultier Marnat <https://orcid.org/0000-0002-7611-7753>

Xavier Barreau <https://orcid.org/0000-0002-4932-1484>

Istvan Szikora <https://orcid.org/0000-0003-3730-3278>

Asier de Albóniga-Chindurza <https://orcid.org/0000-0002-3770-8534>

Luca Scarcia <https://orcid.org/0000-0002-1316-0383>

Andrea M Alexandre <https://orcid.org/0000-0002-8080-3916>

Raoul Pop <https://orcid.org/0000-0003-4417-1496>

Tomas Dobrocky <https://orcid.org/0000-0002-6167-3343>

Christoph Johannes Maurer <https://orcid.org/0000-0002-0305-0797>

Frédéric Clarençon <https://orcid.org/0000-0002-6442-8239>

Gwynedd E Pickett <https://orcid.org/0000-0002-5896-1782>

Ivan Lylyk <https://orcid.org/0000-0002-6048-4225>

Takeshi Morimoto <https://orcid.org/0000-0002-6844-739X>

Fouzi Bala <https://orcid.org/0000-0001-6748-2081>

Riitta Rautio <https://orcid.org/0000-0001-8385-0622>

Jesse Jones <https://orcid.org/0000-0002-2682-9736>  
 Peter B Sporns <https://orcid.org/0000-0002-3028-0539>  
 Stephan Meckel <https://orcid.org/0000-0001-6468-4526>  
 Sophia Hohenstatt <https://orcid.org/0000-0003-0951-3948>  
 Adam A Dmytriw <https://orcid.org/0000-0003-0131-5699>

## REFERENCES

- Cognard C, Gobin YP, Pierot L, et al. Cerebral dural arteriovenous fistulas: clinical and angiographic correlation with a revised classification of venous drainage. *Radiology* 1995;194:671–80.
- Gross BA, Du R. The Natural History of Cerebral Dural Arteriovenous Fistulae. *Neurosurgery* 2012;71:594–603.
- Guniganti R, Giordan E, Chen C-J, et al. Consortium for Dural Arteriovenous Fistula Outcomes Research (CONDOR): rationale, design, and initial characterization of patient cohort. *J Neurosurg* 2022;136:951–61.
- Awad IA, Little JR, Akrawi WP, et al. Intracranial dural arteriovenous malformations: factors predisposing to an aggressive neurological course. *J Neurosurg* 1990;72:839–50.
- Daniels DJ, Vellimana AK, Zipfel GJ, et al. Intracranial hemorrhage from dural arteriovenous fistulas: clinical features and outcome. *Neurosurg Focus* 2013;34:E15.
- Hiramatsu M, Sugiu K, Hishikawa T, et al. Results of 1940 embolizations for dural arteriovenous fistulas: Japanese Registry of Neuroendovascular Therapy (JR-NET3). *J Neurosurg* 2020;133:166–73.
- Lawton MT, Sanchez-Mejia RO, Pham D, et al. Tentorial dural arteriovenous fistulae: operative strategies and microsurgical results for six types. *Neurosurgery* 2008;62:110–24.
- Zhou L-F, Chen L, Song D-L, et al. Tentorial dural arteriovenous fistulas. *Surg Neurol* 2007;67:472–81.
- Shose H, Fujita A, Hori T, et al. Treatment of tentorial dural arteriovenous fistula with preservation of the vein of Galen using a combination of transarterial and transvenous embolization. *Surg Neurol Int* 2025;16:89.
- Tomak PR, Cloft HJ, Kaga A, et al. Evolution of the management of tentorial dural arteriovenous malformations. *Neurosurgery* 2003;52:750–60.
- Zhang G, Pang M, Li Z, et al. Endovascular Treatment for Tentorial Dural Arteriovenous Fistulas: A Retrospective Single-Center Study. *AJNR Am J Neuroradiol* 2025;46:1617–24.
- Zhang G, Zhang W, Chang H, et al. Endovascular treatment strategy and clinical outcome of tentorial dural arteriovenous fistula. *Front Neurol* 2023;14:1315813.
- Cannizzaro D, Brinjikji W, Rammos S, et al. Changing Clinical and Therapeutic Trends in Tentorial Dural Arteriovenous Fistulas: A Systematic Review. *AJNR Am J Neuroradiol* 2015;36:1905–11.
- Raygor KP, Abdelsalam A, Tonetti DA, et al. Microsurgical Treatment of Intracranial Dural Arteriovenous Fistulas: A Collaborative Investigation From the Multicenter Consortium for Dural Arteriovenous Fistula Outcomes Research. *Neurosurgery* 2025;96:1023–34.
- Su X, Li X, Song Z, et al. Tentorial Dural Arteriovenous Fistulas: A Retrospective Cohort Study. *Oper Neurosurg (Hagerstown)* 2025;29:678–85.
- Rezende MTS, Trivelato FP, Castro-Afonso LH, et al. Endovascular Treatment of Tentorial Dural Arteriovenous Fistulas Using the Transarterial Approach as a First-Line Strategy. *Oper Neurosurg (Hagerstown)* 2021;20:484–92.
- Jiang C, Lv X, Li Y, et al. Endovascular treatment of high-risk tentorial dural arteriovenous fistulas: clinical outcomes. *Neuroradiology* 2009;51:103–11.
- Gross BA, Du R. The natural history of cerebral dural arteriovenous fistulae. *Neurosurgery* 2012;71:594–602.
- Su X, Ma Y, Song Z, et al. Intracranial Dural Arteriovenous Fistulas With and Without Pial Artery Supply: Analysis of Treatment Outcomes. *Neurosurgery* 2026;98:450–63.
- Brinjikji W, Cloft HJ, Lanzino G. Clinical, angiographic, and treatment characteristics of cranial dural arteriovenous fistulas with pial arterial supply. *J NeuroIntervent Surg* 2021;13:331–5.
- Osada T, Krings T. Intracranial Dural Arteriovenous Fistulas with Pial Arterial Supply. *Neurosurgery* 2019;84:104–15.
- Abecassis IJ, Meyer RM, Levitt MR, et al. Recurrence after cure in cranial dural arteriovenous fistulas: a collaborative effort by the Consortium for Dural Arteriovenous Fistula Outcomes Research (CONDOR). *J Neurosurg* 2022;136:981–9.