

CLINICAL REPORT OPEN ACCESS

Optical Genome Mapping Identifies a Second Xq27.1 Rearrangement Associated With Charcot–Marie–Tooth Neuropathy CMTX3

Elisa Rahikkala^{1,2}  | Jonna Komulainen-Ebrahim^{2,3} | Jussi-Pekka Tolonen^{2,3}  | Sandra Vorimo⁴ | Maria Suo-Palosaari^{5,6} | Päivi Vieira^{2,3} | Johanna Piispala⁷ | Johanna Uusimaa^{2,3} | Katri Pylkäs^{4,8}  | Tuomo Mantere⁴ 

¹Department of Genomics, Turku University Hospital, Turku, Finland | ²Research Unit of Clinical Medicine and Medical Research Center Oulu, Oulu University Hospital and University of Oulu, Oulu, Finland | ³Division of Pediatric Neurology, Department of Children and Adolescents, Oulu University Hospital, Oulu, Finland | ⁴Laboratory of Cancer Genetics and Tumor Biology, Translational Medicine Research Unit, Medical Research Center Oulu and Biocenter Oulu, University of Oulu, Oulu, Finland | ⁵Department of Diagnostic Radiology, Physics and Technology, Research Unit of Health Sciences and Technology, University of Oulu, Oulu, Finland | ⁶Medical Research Center Oulu, Oulu University Hospital and University of Oulu, Oulu, Finland | ⁷Department of Clinical Neurophysiology, Oulu University Hospital, Oulu, Finland | ⁸Northern Finland Laboratory Centre Nordlab, Oulu, Finland

Correspondence: Tuomo Mantere (tuomo.mantere@oulu.fi)

Received: 25 April 2024 | **Revised:** 20 August 2024 | **Accepted:** 10 September 2024

Funding: This work was supported by Research Council of Finland (Grants 338446, 356676 and 38374).

Keywords: Charcot–Marie–Tooth disease | CMTX3 | genome sequencing | genomic rearrangement | optical genome mapping

ABSTRACT

Background: X-linked recessive type 3 Charcot–Marie–Tooth (CMTX3) is a rare subtype of childhood-onset CMT. To date, all reported CMTX3 patients share a common founder 78 kb insertion from chromosome 8 into the Xq27.1 palindrome region.

Methods: We conducted patient–parent trio optical genome mapping (OGM) on a male patient presenting with clinically diagnosed Dejerine–Sottas disease for whom initial standard diagnostic genetic tests, including whole-genome sequencing (WGS), yielded negative results.

Results: OGM analysis revealed a maternally inherited interchromosomal insertion from chromosome region 7q31.1 into Xq27.1. Coupled with manual reassessment of WGS data, this confirmed the molecular diagnosis of atypical CMTX3 and showed that the 122.4 kb inserted fragment contained *DLD* and partially *LAMBI*. Subsequent analyses confirmed that the rearrangement had arisen de novo in the proband's mother.

Conclusion: We report the second Xq27.1 rearrangement associated with CMTX3, providing novel clinical insights into its phenotypic and genotypic spectrum. Our findings highlight the importance of including genomic rearrangement analysis of Xq27.1 in standard diagnostic pipelines for childhood-onset CMT. Given the overlap in polyneuropathy phenotypes resulting from insertions from chromosomes 7 and 8 into the same Xq27.1 palindrome region, the pathogenic mechanism underlying peripheral neuropathy in CMTX3 likely involves dysregulation of genes within this region.

1 | Introduction

Charcot–Marie–Tooth disease (CMT) is a group of clinically and genetically heterogeneous disorders that cause damage

to peripheral nerves, with more than 100 causative genes described to date (Pipis et al. 2019). The classic CMT type 1A (CMT1A, MIM 188220) is genetically diagnosed by the confirmation of chromosome 17p11.2-p12 duplication, while

This is an open access article under the terms of the [Creative Commons Attribution-NonCommercial](https://creativecommons.org/licenses/by-nc/4.0/) License, which permits use, distribution and reproduction in any medium, provided the original work is properly cited and is not used for commercial purposes.

© 2024 The Author(s). *Molecular Genetics & Genomic Medicine* published by Wiley Periodicals LLC.

next generation sequencing (NGS) approaches, including exome (ES) and whole-genome sequencing (WGS) are recommended for the diagnosis of non-CMT1A phenotypes (Pipis et al. 2019). However, despite recent methodological advancements in NGS approaches, a significant proportion of CMT patients are still without a confirmed molecular-level diagnosis (Record et al. 2024).

X-linked recessive type 3 CMT (CMTX3, MIM 302802) is a rare subtype of severe childhood-onset CMT, characterized by both demyelinating and axonal neuropathy observed on electroneuromyography (ENMG), distal sensory and motor impairment, and foot deformities (Kanhangad et al. 2018). To date, only a single causative genomic alteration has been identified for CMTX3: a 78 kb insertion from chromosome 8 into chromosomal region Xq27.1 (Brewer et al. 2016). Altogether, three families mapping to the CMTX3 locus have been identified (Ionasescu et al. 1991; Brewer et al. 2008), and recent identity-by-descent analysis demonstrated that all previously published CMTX3 patients share the common founder (Henden et al. 2023).

Here, we report a male patient with a clinical diagnosis of Dejerine–Sottas disease at the age of 4 months, for whom standard genetic testing in diagnostic laboratories yielded initially negative results. However, patient–parent trio optical genome mapping (OGM) and reassessment of WGS data revealed a maternally inherited interchromosomal insertion from 7q31.1 into Xq27.1, confirming the molecular diagnosis of phenotypically atypical CMTX3.

2 | Methods

2.1 | Diagnostic Genetic Testing

Previous genetic testing was performed as part of standard clinical diagnostics including trio-ES and short-read WGS (Centogene, Rostock, Germany), chromosomal microarray (HumanCytoSNP-12 v.2.1, Illumina), and karyotyping (Nordlab, Oulu, Finland). Manual reanalysis of mapped reads from WGS was performed with Integrative Genomics Viewer (IGV) v.2.16.1.

2.2 | Optical Genome Mapping

All the OGM experiments were performed according to the manufacturer's instructions using the Saphyr instrument and DLE-1 chemistry (Bionano Genomics Inc., San Diego, CA, USA) as previously described (Mantere et al. 2021), more detailed description is provided in the [supporting information](#).

3 | Results

3.1 | Clinical Description

The patient is a currently 13-year-old boy who was clinically diagnosed with Dejerine–Sottas disease (Table 1, Figure S1, Video S1), based on hypotonia, hyporeflexia, and ENMG studies. The proband's phenotype has overlapping clinical

characteristics with the previously published CMTX3 patients (Table 1; see [supporting information](#) for a detailed case report) (Kanhangad et al. 2018). However, additional findings also include ophthalmological and neuropsychiatric problems and a tethered spinal cord.

3.2 | Molecular Genetics

Results of the standard diagnostic genetic testing, including trio-ES, WGS, array-CGH, and karyotyping, were negative. As part of an ongoing international collaborative research effort utilizing OGM for rare diseases (van der Sanden et al. *unpublished*), a patient–parent trio-based OGM analysis was performed. OGM analysis resulted in 60 rare structural variant (SV) calls, which were assessed for potential association with the patient's phenotype utilizing a list of disease associated genes and loci (MIM, Gene2Phenotype, and Orphanet) and literature searches (PubMed). This revealed an interchromosomal insertion from chromosome 7q31.1 into the intergenic region between *HAPSTR2* and *SOX3* at Xq27.1 (Figure 1A,B), resembling the insertion that has previously been described in families with CMTX3 (Brewer et al. 2016; Henden et al. 2023). Based on OGM, the estimated size of the now identified insertion in our patient was 115.8 kb and it entailed *DLG* and partially *LAMB1*. In line with X-linked recessive inheritance, trio-analysis revealed that the insertion was inherited from the mother.

To confirm the OGM results and obtain nucleotide-level resolution for the rearrangement, WGS data was manually reassessed with IGV (Figure 2A). This confirmed the presence of the 7q31.1 insertion and revealed that it co-occurred with a 1.7 kb deletion that spans the first 97 bps of the Xq27.1 palindrome region. Notably, the insertion-site breakpoint within the 180 bp palindrome region is only 13 nucleotides apart from the one previously reported by Brewer et al. (2016). WGS refined the size of the inserted region to 122.4 kb (chr7:107,842,060–107,964,478) and copy number variant (CNV) calling confirmed its duplication, indicating its presence in two normal copies and as an insertion. In addition, WGS revealed 12 and 58 bp size insertions of unknown origin flanking the inserted 7q31.1 material, and another 4.6 kb deletion upstream of the insertion site (Figure 2A,B). The deletions within the Xq27.1 region were masked by the large insertion in the OGM analysis, explaining the 6.6 kb discrepancy between the insertion size estimated by OGM and WGS. Subsequent OGM analysis of the maternal grandparents of the proband revealed that the insertion had arisen *de novo* in the proband's mother (Figure S2). Here, the paternity and maternity were also confirmed using the SV calls from the trio-analysis.

4 | Discussion

The currently described case presents the second reported large interchromosomal insertion associated with CMTX3. Typically, molecular genetic diagnostics of CMT patients have focused on sequence and CNV analysis, but our study further emphasizes that the analysis of genomic rearrangements into chromosomal area Xq27.1 should be included in diagnostic analysis of patients with childhood-onset CMT. This could be achieved by improved WGS analysis pipelines or using OGM, which is a powerful tool

TABLE 1 | Clinical findings associated with CMTX3 and comparison with literature (Kanhangad et al. 2018).

Parameter	Literature cohort	Index case
Age, most recent assessment	2–19 years	12 years
Age at onset	0–12 years	2 months
Clinical characteristics		
Hypotonia	N/A	Yes, since 2 months
Nystagmus	N/A	Yes, since 2 months
Delayed walking (>18 months)	4/11	Yes, a few steps unsupported at 3 years
Foot deformity	6/11	Yes, pes planus observed by 3 years
Pes cavus	6/11	No
Ankle dorsiflexion weakness	11/11	Yes
Hand weakness	7/11	Yes
Hyporeflexia/Areflexia	N/A	Yes
Gait abnormality	5/11	Yes (imbalance, motor developmental delay)
Nonambulant	1/11	Yes, wheelchair bound before 4 years
Scoliosis	2/11	Yes, brace treatment since 9 months
Hip dysplasia	2/11	No
Foot surgery	3/11	No
Noninvasive respiratory support	1/11	Yes, CPAP from 5 years for obstructive sleep apnea
ENMG findings		
Sensorimotor demyelinating neuropathy	8/9	Yes
Sensorimotor axonal neuropathy	1/9	Yes
Other findings		Bilateral corneal clouding and cataract; ADHD and autism spectrum disorder with normal cognition; dysarthria; tethered cord release at 2 years

Abbreviations: CPAP, continuous positive airway pressure; ENMG, electroneuromyography; N/A, not available.

for detection of large SVs that may be challenging to detect with routine diagnostic methods. Accordingly, there are examples in the medical literature demonstrating that OGM has been able to end an exhaustive diagnostic odyssey in patients with a monogenic disorder of unknown aetiology (Cope et al. 2021; Sabatella et al. 2021). However, further research assessing the diagnostic yield of OGM in the etiological investigation of rare monogenic disorders is warranted.

The polyneuropathy phenotype in our patient overlapped with the CMTX3 phenotype presented in the literature, with typical ENMG findings and age of onset, while the additional features included also ophthalmological and neuropsychiatric symptoms, sleep apnea, and tethered spinal cord. It is possible that our patient's more complex phenotype represents phenotypic variation of CMTX3, and additional phenotypic characteristics could be explained by stochastic factors, background genetics, or a unique composition of genomic Xq27.1 rearrangement with an overlapping insertion site but different inserted material

compared with the previously published patients with CMTX3. Also, it cannot be ruled out that the atypical CMTX3 phenotype might be associated with the dysfunction of different gene(s) than those in previously reported CMTX3 patients with different Xq27.1 insertions.

Nevertheless, once the pathogenic CMTX3-associated genomic rearrangement is identified, it is crucial to analyze segregation to identify potential female carriers of the SV allowing accurate genetic counselling and the assessment of recurrence risk in the family. In this study, the proband's mother presented with highly arched feet possibly associated with the Xq27.1 genomic rearrangement. Furthermore, the proband and his mother had bilateral corneal clouding and strabismus that may be associated with the identified genomic rearrangement or another yet unknown genetic factor.

The chromosomal region Xq27.1 includes a 180 bp palindromic sequence which forms an unstable hairpin loop secondary

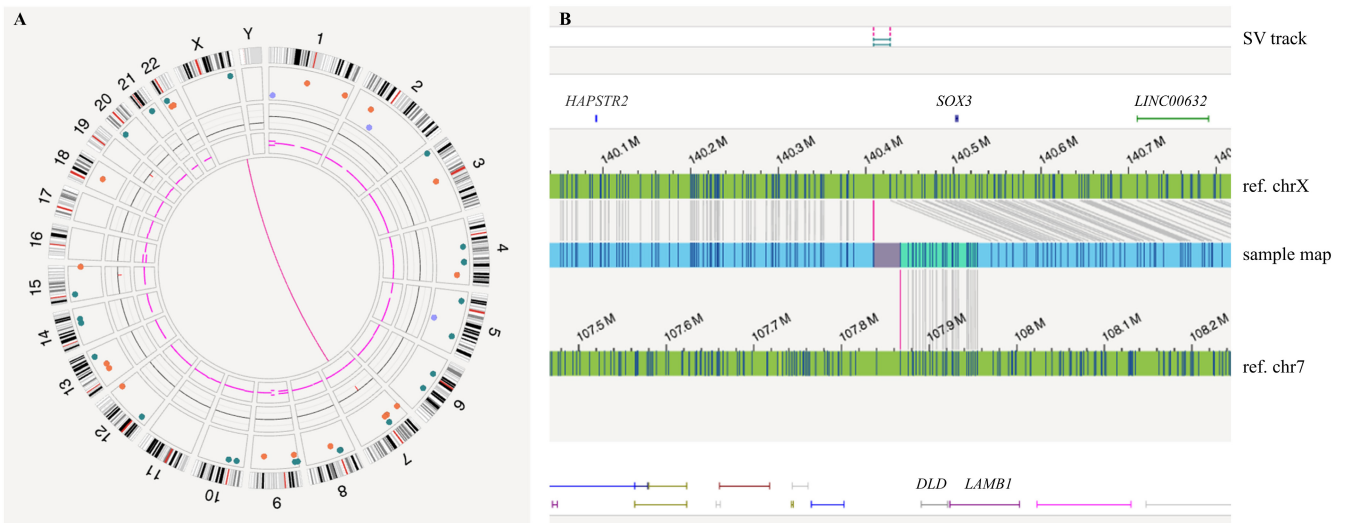


FIGURE 1 | Identification and visualization of the interchromosomal insertion between chromosomes 7 and X by OGM. (A) Genome-wide circos-plot view of all the rare SVs detected by OGM. The pink line between chromosomes 7 and X indicates a rearrangement between the two chromosomes. (B) Zoom-in of the identified rearrangement shows an insertion with an estimated size of 115.8 kb from chromosome 7q31.1 containing *DLD* and partially *LAMB1* (chr7:107,839,927–107,866,930–107,955,176~107,973,052) into the intergenic Xq27.1 region. Tilde (~) represents uncertainty of the exact breakpoint positions in the analysis. The insertion was shown to be located between label positions chrX:140,408,784 and 140,427,850 in the intergenic region between *HAPSTR2* and *SOX3*.

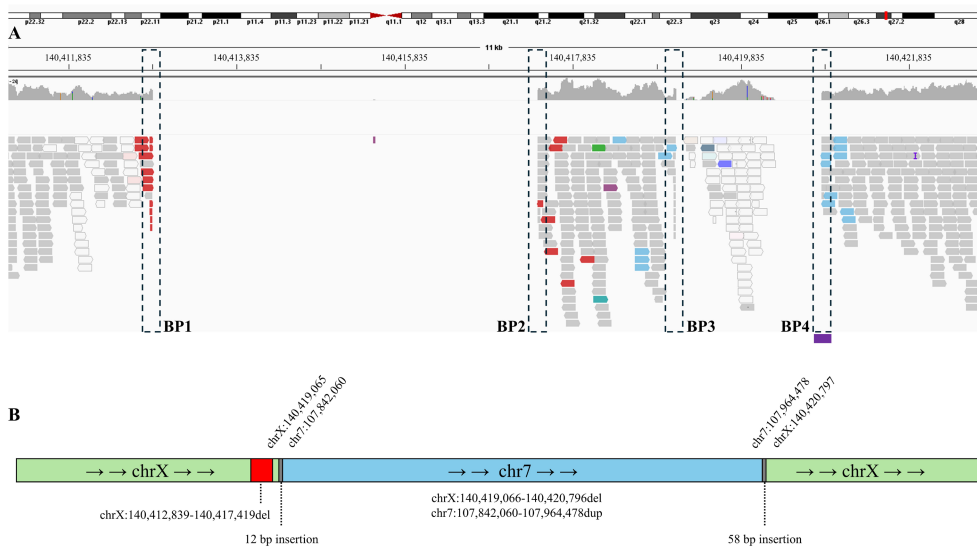


FIGURE 2 | Detection of rearrangement breakpoints (BPs) at nucleotide resolution with WGS. (A) Manual reanalysis of WGS reads at the Xq27.1 rearrangement region using IGV. For uniform presentation, the coordinates were converted from Hg19 to Hg38. Blue-colored reads flanking BP3 and BP4 represent those that have a pair aligning to chromosome region 7q31.1, confirming the insertional event. The insertion coincides with a 1.7 kb deletion (chrX:140,419,066–140,420,796del, delimited by BP3 and BP4), which spans the first 97bps of the Xq27.1 palindrome region (chrX:140,420,700–140,420,879) marked by purple box at BP4. The white-colored reads within the 1.7 kb deleted region are resulting from erroneous mapping. Another 4.6 kb deletion (chrX:140,412,839–140,417,419del, delimited by BP1 and BP2), located ~1.6 kb upstream of the insertion-site, was also detected. (B) Schematic representation (not to scale) of the Xq27.1 rearrangement, comprising a 122.4 kb duplication from 7q31.1 inserted at the site of a 1.7 kb deletion on Xq27.1. Red bar represents the second deletion detected upstream of the insertion. The grey bars flanking the material from 7q31.1 represent additional small insertions of unknown origin.

structure acting as a known mutational hotspot for genomic rearrangements and disease-associated insertions (Boyling, Perez-Siles, and Kennerson 2022). In addition to *CMTX3*, multiple different phenotypes have been linked to insertions into Xq27.1 (Boyling, Perez-Siles, and Kennerson 2022; de Boer et al. 2023). As the 78 kb insertion from chr8q24.3

(Brewer et al. 2016) and the 122.4 kb insertion from chr7q31.1 presented here led to similar symptoms in the affected individuals, it adds further evidence that the mechanism for peripheral neuropathy is the dysregulation of one or more genes within the *CMTX3* locus Xq27.1. Brewer et al. showed that the relative *FGF13* mRNA level was significantly higher in

CMTX3 patient lymphoblasts compared with healthy controls suggesting that *FGF13* is possibly contributing for the CMTX3 pathogenesis, warranting further investigations (Brewer et al. 2016). Altogether, our study further defines the regions within the Xq27.1 palindrome that may be critical for CMTX3 causative rearrangements. As palindromic sequences are present throughout the human genome (Ganapathiraju et al. 2020), other mutational hotspots explaining rare monogenic phenotypes may be identified in the future.

5 | Conclusions

Our study expands the knowledge of the phenotypic and genotypic spectrum of CMTX3 and provides further support for the clinical utility of OGM in revealing pathogenic SVs. It highlights the need for SV detection when studying unsolved peripheral neuropathy cases after negative tests for coding pathogenic variants. As structural genomic rearrangements play a role in multiple disease pathologies (Ganapathiraju et al. 2020), it is likely that other patients with rare diseases and negative ES will benefit from OGM analysis as a second-tier test alongside with other long-read techniques for SV detection.

Author Contributions

Conceptualization: E.R., J.K.-E., and T.M. Writing – original draft: E.R. and T.M., Writing – review and editing: E.R., J.K.-E., J.-P.T., S.V., M.S.-P., P.V., J.P., J.U., K.P., and T.M.

Acknowledgments

We thank the family participating in this study. This study was supported by the Research Council of Finland (decision numbers 338446, 356676, and 38374) to E.R., J.-P.T., and T.M. Biocenter Oulu sequencing center is acknowledged for providing optical genome mapping services. Some of the authors are members of the European Reference Network for Rare Neurological Diseases (ERN-RND) and Neuromuscular Diseases (EURO-NMD).

Ethics Statement

The study is approved by the Ethics Committee of the Northern Ostrobothnia Hospital District (EETTMK: 45/2015, amendment 2020). Written informed consent was obtained from all participating individuals. Written informed consent was obtained to publish patient video.

Conflicts of Interest

The authors declare no conflicts of interest.

Data Availability Statement

The data that support the findings of this study are available on request from the corresponding author.

References

Boyling, A., G. Perez-Siles, and M. L. Kennerson. 2022. “Structural Variation at a Disease Mutation Hotspot: Strategies to Investigate Gene Regulation and the 3D Genome.” *Frontiers in Genetics* 13: 842860. <https://doi.org/10.3389/fgene.2022.842860>.

Brewer, M., F. Changi, A. Antonellis, et al. 2008. “Evidence of a Founder Haplotype Refines the X-Linked Charcot-Marie-Tooth (CMTX3) Locus

to a 2.5 mb Region.” *Neurogenetics* 9, no. 3: 191–195. <https://doi.org/10.1007/s10048-008-0126-4>.

Brewer, M. H., R. Chaudhry, J. Qi, et al. 2016. “Whole Genome Sequencing Identifies a 78 kb Insertion From Chromosome 8 as the Cause of Charcot-Marie-Tooth Neuropathy CMTX3.” *PLoS Genetics* 12, no. 7: e1006177. <https://doi.org/10.1371/journal.pgen.1006177>.

Cope, H., H. Barseghyan, S. Bhattacharya, et al. 2021. “Detection of a Mosaic CDKL5 Deletion and Inversion by Optical Genome Mapping Ends an Exhaustive Diagnostic Odyssey.” *Molecular Genetics & Genomic Medicine* 9, no. 7: e1665. <https://doi.org/10.1002/mgg3.1665>.

de Boer, E., C. Marcelis, K. Neveling, et al. 2023. “A Complex Structural Variant Near SOX3 Causes X-Linked Split-Hand/Foot Malformation.” *HGG Advances* 4, no. 3: 100200. <https://doi.org/10.1016/j.xhgg.2023.100200>.

Ganapathiraju, M. K., S. Subramanian, S. Chaparala, and K. B. Karunakaran. 2020. “A Reference Catalog of DNA Palindromes in the Human Genome and Their Variations in 1000 Genomes.” *Human Genome Variation* 7, no. 1: 40. <https://doi.org/10.1038/s41439-020-00127-5>.

Henden, L., B. R. Grosz, M. Ellis, G. A. Nicholson, M. Kennerson, and K. L. Williams. 2023. “Identity-By-Descent Analysis of CMTX3 Links Three Families Through a Common Founder.” *Journal of Human Genetics* 68, no. 1: 47–49. <https://doi.org/10.1038/s10038-022-01078-1>.

Ionasescu, V. V., J. Trofatter, J. L. Haines, A. M. Summers, R. Ionasescu, and C. Searby. 1991. “Heterogeneity in X-Linked Recessive Charcot-Marie-Tooth Neuropathy.” *American Journal of Human Genetics* 48, no. 6: 1075–1083.

Kanhangad, M., K. Cornett, M. H. Brewer, et al. 2018. “Unique Clinical and Neurophysiologic Profile of a Cohort of Children With CMTX3.” *Neurology* 90, no. 19: e1706–e1710. <https://doi.org/10.1212/WNL.0000000000005479>.

Mantere, T., K. Neveling, C. Pebrel-Richard, et al. 2021. “Optical Genome Mapping Enables Constitutional Chromosomal Aberration Detection.” *American Journal of Human Genetics* 108, no. 8: 1409–1422. <https://doi.org/10.1016/j.ajhg.2021.05.012>.

Pipis, M., A. M. Rossor, M. Laura, and M. M. Reilly. 2019. “Next-Generation Sequencing in Charcot-Marie-Tooth Disease: Opportunities and Challenges.” *Nature Reviews. Neurology* 15, no. 11: 644–656. <https://doi.org/10.1038/s41582-019-0254-5>.

Record, C. J., M. Pipis, M. Skorupinska, et al. 2024. “Whole Genome Sequencing Increases the Diagnostic Rate in Charcot-Marie-Tooth Disease.” *Brain: A Journal of Neurology* 147: 3144–3156. <https://doi.org/10.1093/brain/awae064>.

Sabatella, M., T. Mantere, E. Waanders, et al. 2021. “Optical Genome Mapping Identifies a Germline Retrotransposon Insertion in SMARCB1 in Two Siblings With Atypical Teratoid Rhabdoid Tumors.” *Journal of Pathology* 255, no. 2: 202–211. <https://doi.org/10.1002/path.5755>.

Supporting Information

Additional supporting information can be found online in the Supporting Information section.