



## The current state of cranioplasty in Europe – Results from a European cranioplasty survey

Paul Vincent Naser<sup>a,b,c,d,\*</sup>, Parmenion Tsitsopoulos<sup>e</sup>, Friederike Zacharias<sup>a,b</sup>, Ana M. Castaño-Leon<sup>f</sup>, Andras Buki<sup>g</sup>, Bart Depreitere<sup>h</sup>, Thomas Van Essen<sup>i</sup>, Tommi K. Korhonen<sup>j</sup>, Harry Mee<sup>k</sup>, Iftakher Hossain<sup>l</sup>, Jussi Posti<sup>l</sup>, Laura Lippa<sup>m</sup>, Marios C. Papadopoulos<sup>n</sup>, Nicole Terpolilli<sup>o</sup>, Niklas Marklund<sup>p,q</sup>, Ondra Petr<sup>r</sup>, Peter Toth<sup>s</sup>, Teemu Luoto<sup>t</sup>, Sandro M. Krieg<sup>a,b</sup>, Andreas W. Unterberg<sup>a,b</sup>, Alexander Younsi<sup>a,b,\*\*</sup>, the European Cranioplasty Survey Group<sup>1</sup>

<sup>a</sup> Heidelberg University Hospital, Department of Neurosurgery, Im Neuenheimer Feld 400, 69120, Heidelberg, Germany

<sup>b</sup> Heidelberg University, Medical Faculty, Grabengasse 1, 69117, Heidelberg, Germany

<sup>c</sup> Heidelberg University Hospital, Division of Stereotactic Neurosurgery, Department of Neurosurgery, Im Neuenheimer Feld 400, 69120, Heidelberg, Germany

<sup>d</sup> AI Health Innovation Cluster, German Cancer Research Center (DKFZ), Heidelberg, Germany

<sup>e</sup> Department of Neurosurgery, Hippokraton General Hospital, Aristotle University School of Medicine, Konstantinoupolis 49, 54642, Thessaloniki, Greece

<sup>f</sup> Neurosurgery Department, Av. Córdoba S/n, 28041, Madrid, Spain

<sup>g</sup> Department of Neurosurgery Örebro University Hospital, Södra Grev Rosengatan 42, 70362, Örebro, Sweden

<sup>h</sup> Neurosurgery, University Hospitals Leuven, Herestraat 49, 3000, Leuven, Belgium

<sup>i</sup> Neurosurgery, Leiden University Medical Center, Albinusdreef 2, 2333, ZA, Leiden, Netherlands

<sup>j</sup> Neurosurgery, OYS Neurocenter, Oulu University Hospital, Kajaanintie 50, 90029, Oulu, Finland

<sup>k</sup> Clinical Neurosciences, Addenbrookes Hospital, CB2 0QQ, Cambridge, United Kingdom

<sup>l</sup> Neurocenter, Department of Neurosurgery, Turku University Hospital, Hämeentie 11, 20521, Turku, Finland

<sup>m</sup> UOC Neurosurgery, ASST Ospedale Niguarda, Milano, Piazza Dell'ospedale Maggiore 1, 20162, Milan, Italy

<sup>n</sup> Neurosurgery, Atkinson Morley Wing, St. George's Hospital, Blackshaw Road, SW17 0QT, London, United Kingdom

<sup>o</sup> Ludwig-Maximilians-Universität Munich, Department of Neurosurgery, Marchioninstr. 15, 81377, Munich, Germany

<sup>p</sup> Department of Clinical Sciences Lund, Neurosurgery, Klinikgatan 17A, EA-blocket, 4th Floor, 22185, Lund, Sweden

<sup>q</sup> Department of Clinical Sciences Lund, Neurosurgery, Lund University, Skåne University, Hospital, Lund, Sweden

<sup>r</sup> Department of Neurosurgery, Medical University Innsbruck, Anichstrasse 35, 6020, Innsbruck, Austria

<sup>s</sup> Department of Neurosurgery, University of Pecs, Hungary, Ret street 2, Pecs, Hungary

<sup>t</sup> Department of Neurosurgery, Tampere University Hospital, PL 2000, 33521, Tampere, Poland

### ARTICLE INFO

Handling Editor: Dr W Peul

#### Keywords:

Cranioplasty  
Alloplastic materials  
Autologous bone  
Hydrocephalus management  
European survey  
Regulatory changes

### ABSTRACT

**Introduction:** Cranioplasty, a surgical procedure to restore skull integrity and aesthetic contour following decompressive craniectomy, poses challenges in material selection and timing, driven by the lack of guidelines and ongoing regulatory changes.

**Research question:** This study aimed to provide an overview of current cranioplasty practices in Europe, explicitly addressing a potential shift towards alloplastic materials and the management of patients with concomitant hydrocephalus.

**Material and methods:** An online survey was conducted among European neurosurgical centers from January to March 2024, collecting data on material preferences, timing of procedures, and management strategies for cranioplasty. Descriptive and statistical analyses were performed on 110 complete responses.

**Results:** Respondents favored alloplastic materials over autologous bone for cranioplasty, citing regulatory constraints and reduced infection risk as primary reasons. Variability was observed in the timing of procedures and the management of patients with hydrocephalus, with most centers adopting staged approaches.

This article is part of a special issue entitled: Brain Trauma published in Brain and Spine.

\* Corresponding author. Department of Neurosurgery, Heidelberg University Hospital Im Neuenheimer Feld 400, 69120, Heidelberg, Germany.

\*\* Corresponding author. Department of Neurosurgery, Heidelberg University Hospital Im Neuenheimer Feld 400, 69120, Heidelberg, Germany.

E-mail addresses: [paul.naser@med.uni-heidelberg.de](mailto:paul.naser@med.uni-heidelberg.de) (P.V. Naser), [alexander.younsi@med.uni-heidelberg.de](mailto:alexander.younsi@med.uni-heidelberg.de) (A. Younsi).

<sup>1</sup> The full list is provided in the appendix.

<https://doi.org/10.1016/j.bas.2025.104214>

Received 16 June 2024; Received in revised form 1 December 2024; Accepted 12 February 2025

Available online 17 February 2025

2772-5294/© 2025 The Authors. Published by Elsevier B.V. on behalf of EUROSPINE, the Spine Society of Europe, EANS, the European Association of Neurosurgical Societies. This is an open access article under the CC BY-NC-ND license (<http://creativecommons.org/licenses/by-nc-nd/4.0/>).

*Discussion and conclusion:* The shift towards alloplastic materials in cranioplasty reflects regulatory pressures rather than material-specific considerations. Despite variability in practice, our findings underscore the need for standardized guidelines and further research to optimize patient outcomes. This study provides valuable insights into current practices and highlights areas for future investigation in cranioplasty.

## 1. Introduction

Decompressive craniectomy (DC) is often the last resort for intracranial pressure increases that can otherwise not be controlled. Pathologies leading to decompression, such as severe traumatic brain injury (TBI) (van Essen et al., 2023), intracranial hemorrhage (Marinkovic et al., 2009), or extensive ischemic stroke (Zweckberger et al., 2014), are associated with high mortality rates. If patients survive the acute illness and subsequent intensive care treatment, cranioplasty is indicated to restore the osseous integrity of the skull and is associated with both neurological and quality-of-life improvement (Corallo et al., 2021; Giese et al., 2021a).

Autologous cranioplasty, the cranial restoration by reimplantation of the resected bone fragment, has traditionally been the method of choice for skull repair (Alkhaibary et al., 2020). To this end, bone fragments are stored either in freezers or in the patient's abdominal subcutaneous fat until reimplantation (Alkhaibary et al., 2020). However, in recent years, novel materials have been developed that promise to stimulate osseous integration and may reduce the risk for cranioplasty-related complications such as aseptic osteolysis (Cerveau et al., 2023; Capitelli-McMahon et al., 2023). Although high-quality evidence in the form of randomized-controlled trials supporting the superiority of alloplastic cranioplasty is yet outstanding, regulatory developments complicating storing autografts in in-house freezers might have sparked a gradual shift towards alloplastic cranioplasty (Do et al., 2023).

Additionally, in recent years, there has been increased awareness regarding the legal status of a stored bone fragment assigned by European law (Missori et al., 2014). This has led to national regulations banning or complicating in-house bone storage, potentially encouraging the use of alloplastic implants.

Herein, we report on the results of an online survey of European neurosurgical centers conducted between January and March 2024 and review the current state of cranioplasty in Europe. Participants were tasked with reporting their current practice regarding cranioplasty and bone flap storage and the considerations associated with both.

## 2. Methods

From January to March 2024, we conducted an online survey using a web-hosted application (Crowdsignal API; Automattic Inc. San Francisco, CA, USA). The survey was accessible under <http://www.cranio-plasty.de> and actively promoted through the European Association of Neurological Surgeons (EANS) mailing lists and social media channels, e.g., LinkedIn. The survey recorded answers anonymously; participants could voluntarily disclose their contact information. The 28-item survey is included in the supplementary text. In brief, it included general questions regarding the participants' surgical specialty, professional setting, department preferences regarding cranioplasty, and the usual treatment course for patients undergoing cranioplasty. In total, 141 responses were counted. In cases where several responses were counted from the same clinic or the same respondent, only the survey with the most questions answered was evaluated. Of those, 110 surveys from unique hospitals were at least 66% complete and were included in the analysis. Descriptive and statistical analysis (chi-squared test and Fisher's exact test for categorical and Student's t-test for continuous variables with all variables being tested for normality using the Shapiro-Wilk test) was conducted using GraphPad Prism (Version 10.2.3) ( $p < 0.05$  was considered significant), and figures were prepared using Adobe Illustrator (Version 28.5). For improved readability, percent values are

rounded to the nearest integer in the main text.

## 3. Results

### 3.1. Participant demographics

Clinicians from 20 European nations participated in the survey, albeit with a non-homogenous distribution amongst countries (Fig. 1 B, Table 1). While the survey was open to all surgical specialties performing cranioplasty surgeries, we only received responses from neurosurgeons. Colleagues from Germany and Greece contributed the most completed surveys (Table 1). Over 60% (64/106) of responses were counted from attendings, executive attendings, or department heads, suggesting high data validity, as those groups putatively oversee the organizational and institutional rules and guidelines (Fig. 1 A). Most centers (42%, 45/107) reported performing between 10 and 25 decompression craniectomies annually, with a minority of very low (<10/a, 11%, 12/107) and very high (>100/a, 1.9%, 2/107) volume centers also participating in the survey (Fig. 1 A). Similarly, most centers performed 1–2 naïve, i.e., non-revision cranioplasty operations per month. Revision cranioplasty operations were conducted less frequently, with most participants (62%, 65/105) reporting less than ten annually. In the majority of centers (95%, 105/110), cranioplasty surgeries were conducted exclusively by neurosurgeons, whereas five centers reported receiving aid in complex cases, e.g., by maxillofacial or plastic surgeons.

#### 3.1.1. Material preferences in cranioplasty

Two general types of materials are available when considering performing a cranioplasty operation: autologous, i.e., using the patient's own preserved bone flap, or alloplastic, i.e., using synthetic materials. Over half (52%, 57/109) of respondents reported primarily using alloplastic materials for cranioplasty (Fig. 2 A).

Among such materials, thermoplastic polymers such as poly(methyl methacrylate) (PMMA), polyether ether ketone (PEEK), and polyetherketoneketone (PEKK) were strongly favored, with 48% (27/56) of surgeons preferring either of those materials. Interestingly, 21 centers (37%) reported preferring mineralic (calcium phosphate) or compound materials, such as composite bioactive glass implant (e.g., GLACE™, Skulle Inc. Finland) or calcium phosphate/titanium (e.g. OssDsign, Sweden). Solid titanium was the material of choice in only six clinics (11%). Two centers (4%) used other materials, namely, in one case, a proprietary polyethylene/polypropylene mesh (Cobudix®) and secondly, titanium mesh, which is intraoperatively covered with gentamicin-treated bone cement (Fig. 2 B).

Alloplastic cranioplasty was favored more frequently in high-volume centers (>50 DHC/a) with 64% (49/90), compared to 54.4% (16/25) in low-volume centers (<50 DHC/a); however, this difference was not statistically significant (Fisher's exact test,  $p = 0.5$ , Fig. 2 C).

Of those preferring autologous bone, the majority (81%, 42/52) cited biocompatibility, cost (67%, 35/52), and fit (38%, 20/52) as the main reasons for this preference (Fig. 1 D). Surgeons who preferred alloplastic materials interestingly favored this material for biocompatibility (53%, 30/57) and fit (47%, 27/57). Another critical factor cited in favor of alloplastic cranioplasty materials was their perceived reduced risk of infection (46%, 26/57), compared to only 11/52 (21%) respondents who preferred autologous bone for that reason. Indeed, significant differences regarding the reasons for choosing alloplastic versus autologous materials ( $p = 0.0002$ ) could be observed (Fig. 2 D).

### 3.1.2. Timing of cranioplasty

In clinics preferentially using autologous bone, cranioplasty tended to be conducted 8–12 weeks following DC (49%, 25/51), whereas half (50%, 28/56) of the clinics using alloplastic materials conducted cranioplasty after more than 12 weeks (Fig. 2 E). This difference did, however, not reach statistical significance ( $p = 0.3$ ).

Overall, only two clinics (2%) preferred ultra-early cranioplasty within four weeks following DC in adults. Most centers (84%, 91/108) usually restored cranial integrity after over two months (Fig. 3 B).

### 3.1.3. Autologous bone storage

In cases of autologous cranioplasty, the removed bone fragment must be stored safely until reimplantation. A dedicated ultra-cold freezer ( $\pm -80^\circ\text{C}$ ) was used in most centers (68%, 44/65). Ten clinics (15%) exclusively stored the bone fragments abdominally, and seven clinics (11%) reported utilizing both methods, depending on the individual patient. Four clinics (6%) reported other storage methods. In three instances (4%), those were dedicated, strongly regulated off-site tissue banks (Fig. 3 A, left). In one center (2%), the skull fragments were stored “enveloped in sterile gloves, in a box with formaldehyde pulver.”

Depending on the local jurisdiction, storing the bone fragments may require informed consent from patients or their legal guardians. In our survey, more than half of the centers (55%, 32/58) obtained informed consent from patients undergoing surgery for storing bone fragments, while 31% (18/58) did not. Additionally, eight respondents (14%) reported being unsure if this practice was implemented at their center. In contrast, physicians did not typically inform patients or next of kin when a bone fragment was discarded in most of the centers (62%, 36/58, Fig. 3 A, middle).

The duration of bone fragment storage varied widely between centers. Whereas in 41% (22/54), the storage duration was not limited, most centers reported defined guidelines for when a bone fragment is discarded (Fig. 3 A, right).

Thirty-five clinics (32%) reported discontinuing the use of autologous bone entirely. Among these, 74% (26/35) cited logistical issues such as storage (54%, 19/35) and legal concerns, including informed consent and biobanking (20%, 7/35), as reasons for cessation. Additionally, 46% (16/35) of the centers stated to exclusively use alloplastic

implants, attributing their choice to factors such as better outcomes after allogeneic cranioplasty, fewer reoperations, and reduced infection rates.

### 3.1.4. Pediatric cranioplasty practices

Children requiring cranioplasty are exceedingly rare. Reflecting that, only 64% (70/110) of participating clinics reported conducting these surgeries at all, 80% (56/70) of which were university hospitals. Contrary to adults, over half of the respondents (53%, 37/70) reported using autologous bone in children (Fig. 3 B), with 44% (31/70) favoring alloplastic materials and two respondents (3%) using both materials equally. Detailed reasons for the respective choices are given in Table 2. As with adults, a significant difference was found in those reported reasons ( $p = 0.03$ ). Of note, a reason for using autologous bone reported twice was the possibility of bone growth, whereas one colleague reported to use autologous bone “even if the risk for bone resorption is high”.

Highlighting the distinct approaches in pediatric cranioplasty, 41% of clinics (28/68) preferred to perform cranioplasty within the first two months after DC. Notably, 11.76% (8/68) of clinics typically operated within four weeks following DC. The variation in surgical timing between adult and pediatric patients was statistically significant ( $p = 0.0007$ ).

### 3.1.5. Shunt and cranioplasty

When treating patients with hydrocephalus requiring cranioplasty, two fundamental decisions need to be made by the operating surgeon. First, whether to simultaneously place shunt and cranioplasty implants or stage them, i.e., in a separate surgery. Secondly, whether to place the ventricular catheter through the healthy, contralateral hemisphere or ipsilateral to the cranioplasty.

Our survey underscores the varied approaches in managing patients requiring cranioplasty with concomitant hydrocephalus practiced throughout Europe. While 39.2% (31/79) of centers performed cranioplasty and ventriculoperitoneal (VP)-shunt in a single session, the majority of 60.8% (48/79) opted for a staged approach (Fig. 3 C). Generally, the preferred method for shunt placement was through the contralateral, cranially intact hemisphere. Among centers conducting simultaneous procedures, 48% (15/31) inserted the ventricular catheter ipsilaterally during cranioplasty, while 52% (16/31) used the

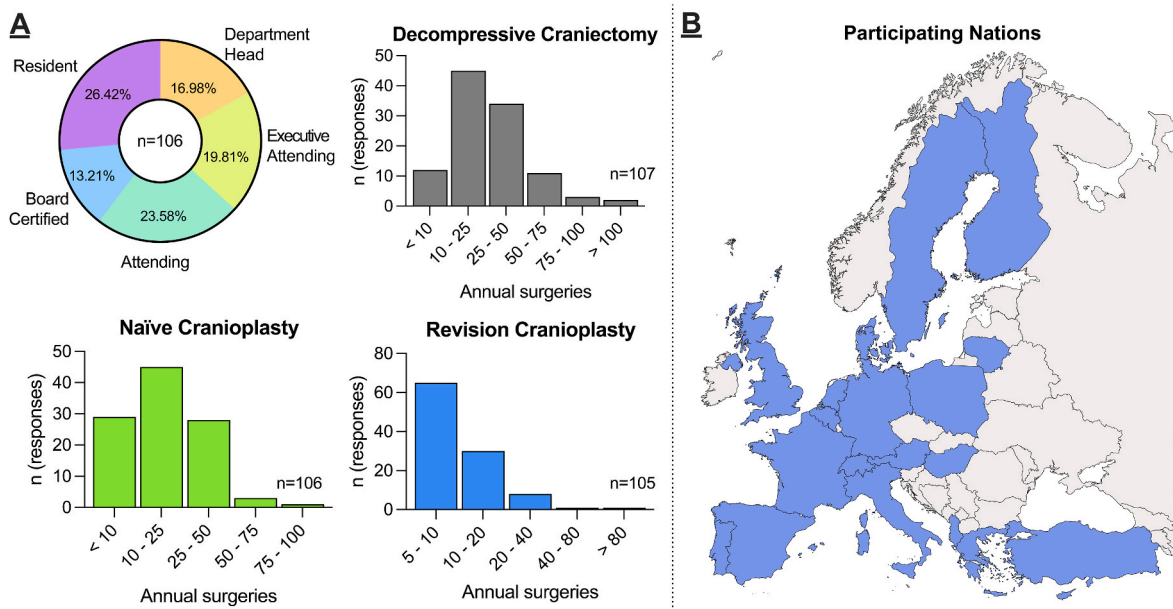


Fig. 1. Study participants.

A: Demographic information of survey participants (top left). Caseloads of decompressive craniectomy (top right), naïve (bottom left), and revision cranioplasty (bottom right) differed between centers. B: Colored map illustrating the location of practice of participating neurosurgeons; numerical data on the number of participants for each country are provided in Table 1.

**Table 1**  
Number of responses received from different European countries.

	Albania	Austria	Belgium	Switzerland	Cyprus	Germany	Denmark	Spain	Finland	France	United Kingdom	Greece	Hungary	Italy	Lithuania	Netherlands	Poland	Portugal	Sweden	Turkey
n	1	1	3	1	2	35	1	4	6	1	5	34	3	2	2	3	1	4	1	

contralateral hemisphere.

For those adopting a staged approach, 71% (34/48) conducted the cranioplasty first, and 22% (14/48) placed the shunt initially. One center used temporary external ventricular drains (EVDs) during cranioplasty to avoid permanent shunting. All centers initiating with VP-shunting placed the catheter contralaterally. Of the centers starting with cranioplasty, only a minority (15%, 5/34) subsequently placed the shunt ipsilaterally, with the majority continuing to favor the contralateral hemisphere.

### 3.1.6. Follow-up

Regarding follow-up after cranioplasty, 78% of participants (78/100) routinely performed a postoperative computed tomography (CT) scan. In contrast, 12% (12/100) did not conduct any CT scans but instead followed up with a single outpatient visit. We did not ascertain the time frame in which a CT scan was conducted. Additionally, 5% of the centers (5/100) reported to adhere to a structured follow-up regimen involving multiple outpatient visits. Another 5% of respondents stated that they enroll their patients in prospective registries to monitor outcomes over time.

## 4. Discussion

Cranioplasty is often considered a routine neurosurgical operation; however, with one of the largest wound surfaces among cranial procedures, it can be associated with high complication rates, including surgical site infections and implant failure (Alkhaibary et al., 2020; Sauvigny et al., 2021; Rocque et al., 2018; Giese et al., 2021b; Rashidi et al., 2020; Di Rienzo et al., 2024). These complications pose significant risks to patients who have already survived life-threatening conditions that initially required DC. Despite a notable reduction in complication and reoperation rates—from 15-40% and 25% a decade ago (Feroze et al., 2015) to markedly lower figures today (Sauvigny et al., 2021) — international best practices for cranioplasty have yet to be established. This scarcity of best practices is largely due to the lack of extensive, multicentric studies. Therefore, our study aimed to gather comprehensive data on cranioplasty within the European Community, laying the groundwork for developing standardized guidelines and best practices.

### 4.1. Autologous vs. alloplastic cranioplasty

Since the widespread availability of ultra-cold storage freezers in the 1970s and 1980s, storing patients' autologous bone fragments after DC frozen was considered the gold standard and surpassed both split-rib autografts, a technique developed during wartime to treat cranial defects and also the practice of abdominal storage (Alkhaibary et al., 2020; Do et al., 2023). However, a steady shift from autologous to alloplastic cranioplasty has been observed over the past several years (Do et al., 2023). The participants in our survey, too, favored alloplastic over autologous cranioplasty in adult patients (Fig. 2 A). Reasons for this shift, however, were not the ever-present, steady infection rate of autologously transplanted bone fragments documented over decades but a regulatory shift. In the first decade of the century, the European Parliament (Directive, 2004/23/EC) and the European Council (2006/17/CE & 2006/86/CE) classified bone fragments as equivalent to human transplant organs, potentiating the regulatory burden for cryopreservation and making in-house cryopreservation, while still widely practiced, formally illegal within the European Union (Missori et al., 2014). Our survey, too, reflects this, as several centers gave up autologous cranioplasty not for material-specific reasons but for the legal and logistical burden of storage. Despite these regulations, nearly half of the participating centers reportedly do not seek informed consent for in-house storage or discarding of autologous bone fragments, and more than 40% store bone fragments indefinitely, risking potential medico-legal consequences.

Material-specific aspects, in turn, played a vital role in surgeons

preferring specific alloplastic materials over autologous grafts (Fig. 2 D). Several dozen different materials, ranging from bare titanium over thermoplastics to proprietary calcium phosphate/titanium amalgamations promising stimulation of bone growth and near-natural cranial integration, are used globally (Siracusa et al., 2021). Our survey participants revealed no clear preference for one material while naming over 20 different manufacturers available in the EU alone (Fig. 2 B).

The current consensus is that alloplastic and autologous cranioplasty materials are largely comparable regarding postoperative complication rates (Cerveau et al., 2023; Do et al., 2023), with a small number of studies even suggesting a superiority of alloplastic materials (Capitelli-McMahon et al., 2023). A definite advantage of such materials lies in their inability to succumb to osteolysis, a risk exceptionally high in patients with concomitant hydrocephalus, young age, and smokers (Sauvigny et al., 2021; Rashidi et al., 2020; Di Rienzo et al., 2024; Ernst et al., 2018; Korhonen et al., 2018). To date, objectively, no single material has emerged superior to others in sufficiently powered trials (Alkhaibary et al., 2020), and surgeons should be aware of the economic incentive for medical suppliers in this potentially lucrative market when choosing a material for cranioplasty.

#### 4.2. Timing for cranioplasty

Determining the optimal timing for cranioplasty is complex, requiring a careful balance of considerations that favor both earlier and later surgical interventions. During the acute phase, factors such as persistent brain swelling and incomplete wound healing must be considered, complicating the decision-making process. Traditionally, it

has been a common practice to delay cranioplasty for 3–6 months following decompression (Malcolm et al., 2018). However, recent studies indicate that cranioplasty plays an essential role in restoring both CSF dynamics and normalizing cerebral blood flow (Panwar et al., 2019; Parichay et al., 2017; Mah and Kass, 2016), suggesting that patients may benefit from cranioplasty in the early stages of neurological rehabilitation (Malcolm et al., 2018; Morton et al., 2018; Patel et al., 2023). Another practical factor for early cranioplasty is to restore cranial integrity to enable patients to take full advantage of rehabilitative measures without restrictions imposed by overly cautious neuro-rehabilitationalists (LA Porta et al., 2023).

In our collective, surgeons were hesitant to perform ultra-early cranioplasty within one month following DC, but nearly two-thirds favored an operation within the first three months. Centers primarily using autologous bone did show a trend towards earlier cranioplasty, which could potentially be attributed to the immediate availability of in-house stored fragments in contrast to specifically produced patient-specific implants.

#### 4.3. Pediatric patients

Pediatric patients requiring cranioplasty are exceedingly rare and are virtually always treated at large (academic) centers. This, too, was reflected in our analysis as only a small subset of participants reported performing pediatric cranioplasty. In pediatric patients, the incomparably larger capacity for osseous and neurological regeneration needs to be taken into account. Contrary to adult cases, we found that participating surgeons particularly preferred using autologous bone over

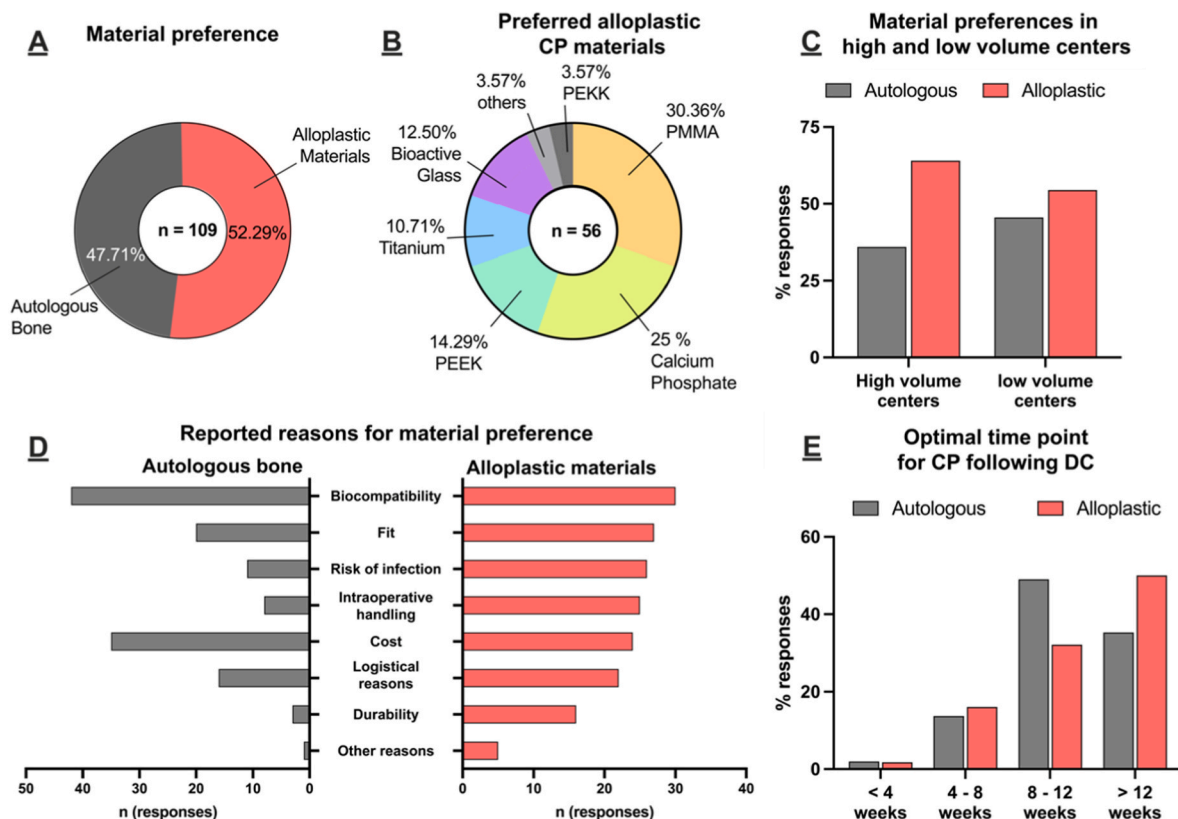
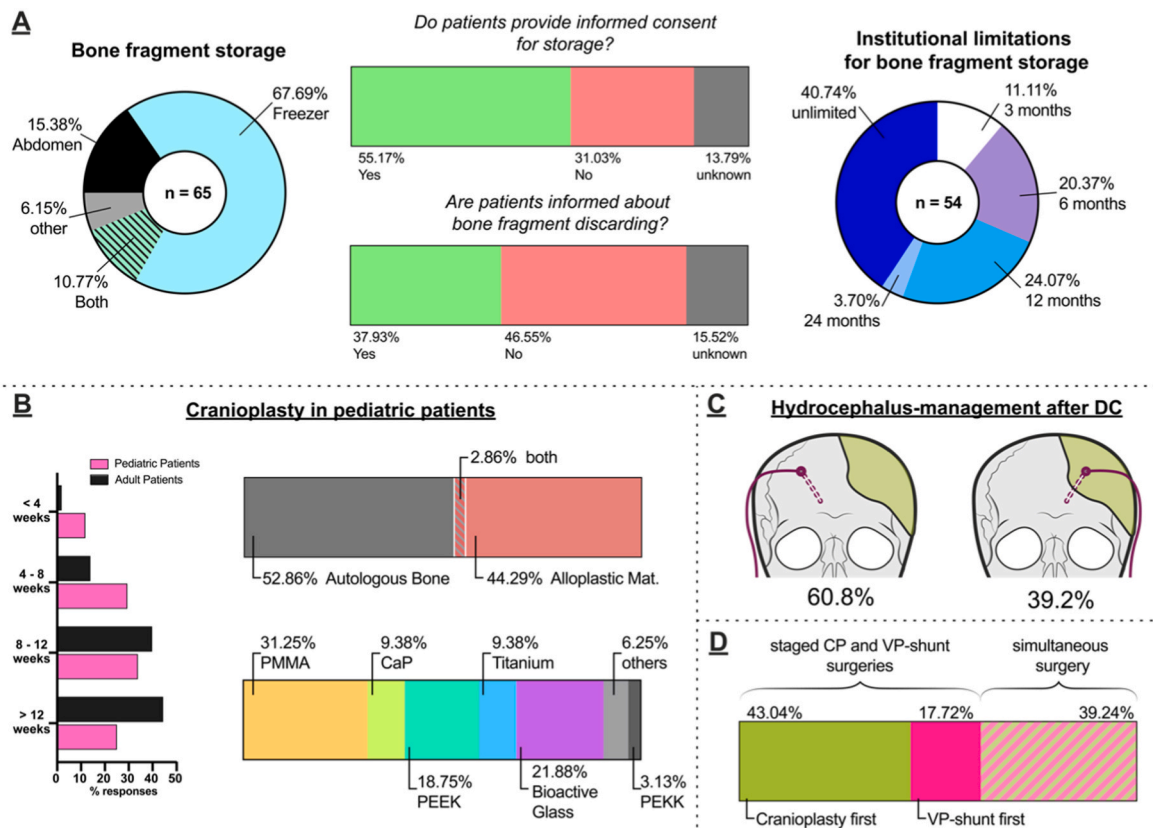


Fig. 2. Preferences in material selection for cranioplasty.

**A:** Pie-chart illustrating the distributions of surgeons preferring alloplastic (red) materials or autologous bone (grey) for cranioplasty. **B:** Pie-chart illustrating the distributions of alloplastic materials used as first-line material in cranioplasty. **C:** Material preferences were not significantly different between high and low-volume centers (for definition, see text (Fisher's exact test,  $p = 0.5$ )). **D:** The reasons for choosing autologous and alloplastic materials were differed between alloplastic materials and autologous CP. Bar graphs denoting the number of responses. Note that participants could provide multiple reasons for each material. **E:** No significant difference was detected between the preferred time point for cranioplasty when comparing surgeons preferring alloplastic and autologous bone (Fisher's exact test,  $p=0.3$ ).



**Fig. 3.** Practices of bone-fragment storage, pediatric cranioplasty, and management of hydrocephalus  
**A: Management of bone fragment storage.** Pie-chart illustrating the practices of bone fragment storage (left). More than half of centers seek informed consent from patients (resp. next of kin) when storing bone fragments (middle, top), but more than 60% do not notify next of kin when bone fragments are discarded (middle, bottom). Maximal storage time was limited by institutional guidelines in most centers (right). **B: Management of cranioplasty in children.** Survey participants favored an earlier cranioplasty compared to adults ( $X^2, p=0.0007$ ). In pediatric patients, most respondents favored autologous bone cranioplasty (right, top). When alloplastic cranioplasty was conducted, materials similar to those used in adults were used (right, bottom). **C + D: Management of patients with hydrocephalus requiring cranioplasty.** Most respondents preferred placing a ventriculoperitoneal (VP)-shunt via the contralateral hemisphere (C) when necessary. Additionally, a staged approach was predominantly favored, where cranioplasty (CP) is performed first, followed by VP-shunt placement if required (D).

**Table 2**

Reasons reported for preferring autologous and alloplastic cranioplasty materials in pediatric patients.

	primarily autologous	primarily alloplastic
Durability	n = 6	n = 4
Logistical reasons	n = 6	n = 11
Cost	n = 16	n = 7
Ease of handling during surgery	n = 3	n = 8
Biocompatibility	n = 33	n = 12
Fit	n = 17	n = 14
Risk of infection	n = 10	n = 8
Other reasons	n = 4	

alloplastic materials in pediatric patients. Commonly cited reasons included the potential for osseous regeneration and the ability of the bone fragment to grow during the child's later development. However, despite these perceived advantages, a recent study indicated that bone flaps stored for more than four months contain no viable osteoblasts. (Chan et al., 2017). Notably, in a child requiring an alloplastic graft with a bioglass implant, the contour of the reconstructed area followed skull anatomic development, and imaging showed considerably large areas of bone growth (Piitulainen et al., 2019), underscoring the immense potential for osseous regeneration in this collective, which may likewise occur in cryopreserved autografts (Posti et al., 2016). Using partial, split grafts of the removed craniectomy has further been demonstrated to yield promising results (Fekry Elshirbiny et al., 2023). In our survey,

44% of participants favored alloplastic grafts, whereas various materials were reportedly used. Mimicking the inconclusive studies from adults, a recent meta-analysis conducted explicitly on children failed to identify a single superior material (Salam et al., 2018).

In our data, we found a highly significant difference in the surgical timing of cranioplasty in children, with surgeons favoring earlier cranioplasty, even within the first four weeks (Fig. 3 B). Supporting this, Piedra and colleagues found a significant reduction in bone-flap resorption rates following early (<6 weeks) cranioplasty in 61 children, up to 82% of which may have been at risk of developing this complication otherwise (Piedra et al., 2012; Martin et al., 2014). Interestingly, while supporting early cranioplasty as a beneficial factor against bone flap resorption, other studies found that the cranial defect's size did not significantly influence its occurrence (Rocque et al., 2018; Primalani et al., 2022).

#### 4.4. Management of patients with hydrocephalus requiring cranioplasty

One of the most heatedly debated topics in recent years has been the question of treating patients with hydrocephalus after DC. Numerous studies found these patients to inherently carry a high risk of developing maladaptive CSF dynamics (Panwar et al., 2019; Wu et al., 2022; Fat-tahian et al., 2018), which have at times been found to be reverted after cranioplasty (Panwar et al., 2019). From the surgical perspective, however, prior shunt placement can enable the intraoperative CSF tap to decompress the situs in cases of prolapsing brain tissue. Conversely,

when shunt settings are not closely monitored, a collapsed skin flap as a result of sunken brain tissue can occur, potentially increasing CP complications (Chen et al., 2023). Combining both operations in one session thirdly might offer logistical advantages, as the patients, often requiring intensive or intermediate care settings, need only to be admitted once (Rosinski et al., 2020).

Mirroring such controversies, participating centers reported significant differences in managing these cases. The majority (~60%) favored staged surgery, with two-thirds restoring cranial integrity before evaluating shunt necessity. A small subset of neurosurgeons reported placing a shunt first, followed by cranioplasty surgery later. The remaining 39.3% reported shunt and cranioplasty implantation in one surgical session. Conflicting evidence has been brought forward regarding the simultaneous shunt implantation, with some studies finding no differences in complication rates (Yang et al., 2017; Wang et al., 2023) and others finding marked increases when conducted simultaneously (Yang et al., 2017; Zhou et al., 2022). Building on the established drastic changes in hydrodynamics following cranioplasty (Panwar et al., 2019; Parichay et al., 2017; Mah and Kass, 2016; Fodstad et al., 1984; Dujovny et al., 1997a, 1997b), several studies suggest that prior cranioplasty may restore CSF dynamics enough to render shunt placement obsolete (Qiu et al., 2023). In the absence of large randomized controlled trials, a European expert panel recently addressed the management of hydrocephalus after severe trauma and decompression in a comprehensive consensus paper (Iaccarino et al., 2024). Their guidelines heavily favor dynamic monitoring of CSF dynamics and, if possible, conducting cranioplasty first to evaluate whether, after cranial restoration, shunt insertion is still necessary (Iaccarino et al., 2024). Only further prospective multicentric studies can elucidate whether these guidelines apply to atraumatic cases, e.g., DC following a malignant stroke or SAH.

Interestingly, no consensus was observed even when considering the preferred hemisphere for shunt placement, with 60.8% primarily favoring the hemisphere contralateral to the cranioplasty. While most surgeons would be hesitant to reoperate the ipsilateral hemisphere in a staged procedure due to the risk of surgical site infection, a small retrospective analysis showed that when simultaneous shunt/cranioplasty was conducted, the side did not adversely influence complication rates (Yan et al., 2022).

## 5. Limitations

The current study has several limitations, primarily due to the nature of data acquisition. Namely, selection, sampling, and reporting bias cannot be ruled out. Additionally, this survey did not aim to adequately answer the often-multifaceted questions faced by neurosurgeons in treatment decisions using multiple-choice questions. Furthermore, preferred neurosurgical practice may significantly differ from how surgeons are able to treat patients given non-medical constraints, such as insurance policies, implant availability, etc.

With the majority of responses from Germany and Greece, the survey's implications may not broadly apply to countries with fewer responses. As this online survey was conducted openly, no verification of professional status was performed, potentially making this survey susceptible to varying levels of experience and competence amongst respondents. Further, although the over 100 responses counted here represent the most extensive published survey regarding cranioplasty, with several thousand neurosurgeons practicing in Europe (Ringel et al., 2023), the data analyzed here are not representative but should invite the interested reader to reflect on their practices in light of recent international developments.

## 6. Conclusions

In this study, we explored current cranioplasty practices across European neurosurgical centers via an online survey. Traditionally, cranioplasty after decompressive craniectomy was performed using the

patient's autologous bone fragment. Although our study is, to our knowledge, the first survey attempting to document the real-life practice of cranioplasty, with a significant number of centers reportedly using primarily alloplastic materials, our findings indicate a shift towards preferring alloplastic materials over autologous bone. Regulatory changes and the individual materials' characteristics supposedly drive this trend. We noted significant variability in the timing of cranioplasty procedures and in managing patients with hydrocephalus, underscoring the urgent need to develop standardized guidelines. Despite limitations such as reliance on self-reported data and a possible sampling bias, our research provides critical insights into the evolving dynamics of cranioplasty practices. These insights highlight the necessity for ongoing research and enhanced collaboration to optimize patient outcomes in this field.

## Author's contributions

P.V.N. and A.Y. conceived the study. A.M. C-L., A.B., B.D., T.v.E., H. M., I.H., J.P., L.L., M.C.P., N.T., N.M., O.P., P.T, P.T., and T.L. provided input on the survey design and actively promoted the survey in their national EANS chapters. P.V.N. and F.Z. collected and analyzed data. P. V.N. prepared figures and wrote a first manuscript draft, which was edited and reviewed by A.Y. A.W.U. and S.M.K. provided infrastructure and funding. All authors reviewed the manuscript and provided feedback.

The members of the European Cranioplasty Survey group contributed insights on their individual practices as survey participants.

## Ethics approval

This voluntary survey involving human participants was following the ethical standards of the institutional and national research committee and with the 1964 Helsinki Declaration and its later amendments or comparable ethical standards.

## Declaration of competing interest

The authors declare that they have no known competing financial interests or personal relationships that could have appeared to influence the work reported in this paper.

## Acknowledgments

This publication was supported through state funds approved by the State Parliament of Baden-Württemberg for the Innovation Campus Health + Life Science Alliance Heidelberg Mannheim issued to P.V.N. The authors thank all department colleagues for fruitful discussions and survey participants for sharing their valuable insights. We thank Thomas Schmidt for his help with data curation and Chiraz Ben Salah and Philipp Gustav Roth for their feedback on the figures.

## Appendix A. Supplementary data

Supplementary data to this article can be found online at <https://doi.org/10.1016/j.bas.2025.104214>.

## References

- Alkhaibary, A., Alharbi, A., Alnefaie, N., Oqalaa Almubarak, A., Aloraidi, A., Khairy, S., 2020. Cranioplasty: a comprehensive review of the history, materials, surgical aspects, and complications. *World Neurosurgery* 139, 445–452. <https://doi.org/10.1016/j.wneu.2020.04.211>.
- Capitelli-McMahon, H., Kahlar, N., Rahman, S., 2023. Titanium versus autologous bone-based cranioplasty: a systematic review and meta-analysis. *Cureus* 15, e39516. <https://doi.org/10.7759/cureus.39516>.
- Cerveau, T., Rossmann, T., Clusmann, H., Veldeman, M., 2023. Infection-related failure of autologous versus allogenic cranioplasty after decompressive hemicraniectomy - a

- systematic review and meta-analysis. *Brain Spine* 3, 101760. <https://doi.org/10.1016/j.bas.2023.101760>.
- Chan, D.Y.C., Mok, Y.T., Lam, P.K., Tong, C.S.W., Ng, S.C.P., Sun, T.F.D., Poon, W.S., 2017. Cryostored autologous skull bone for cranioplasty? A study on cranial bone flaps' viability and microbial contamination after deep-frozen storage at  $-80^{\circ}\text{C}$ . *J. Clin. Neurosci.* 42, 81–83. <https://doi.org/10.1016/j.jocn.2017.04.016>.
- Chen, R., Ye, G., Zheng, Y., Zhang, Y., Zheng, S., Fang, W., Mei, W., Xie, B., 2023. Optimal timing of cranioplasty and predictors of overall complications after cranioplasty: the impact of brain collapse. *Neurosurgery* 93, 84–94. <https://doi.org/10.1227/neu.0000000000002376>.
- Corallo, F., Lo Buono, V., Calabrò, R.S., De Cola, M.C., 2021. Can cranioplasty Be considered a tool to improve cognitive recovery following traumatic brain injury? A 5-years retrospective study. *J. Clin. Med.* 10, 5437. <https://doi.org/10.3390/jcm10225437>.
- Di Rienzo, A., Colasanti, R., Dobran, M., Carrassi, E., Herber, N., Paracino, R., Raggi, A., Iacangelo, M., 2024. Bone flap resorption after cranioplasty: risk factors and proposal of the flap integrity score. *World Neurosurgery* 181, e758–e775. <https://doi.org/10.1016/j.wneu.2023.10.124>.
- Do, T.H., Lu, J., Palzer, E.F., Cramer, S.W., Huling, J.D., Johnson, R.A., Zhu, P., Jean, J. N., Howard, M.A., Sabal, L.T., et al., 2023. Rates of operative intervention for infection after synthetic or autologous cranioplasty: a National Readmissions Database analysis. *J. Neurosurg.* 138, 514–521. <https://doi.org/10.3171/2022.4.JNS22301>.
- Dujovny, M., Fernandez, P., Alperin, N., Betz, W., Misra, M., Mafee, M., 1997a. Post-cranioplasty cerebrospinal fluid hydrodynamic changes: magnetic resonance imaging quantitative analysis. *Neurol. Res.* 19, 311–316. <https://doi.org/10.1080/01616412.1997.11740818>.
- Dujovny, M., Aviles, A., Agner, C., Fernandez, P., Charbel, F.T., 1997b. Cranioplasty: cosmetic or therapeutic? *Surg. Neurol.* 47, 238–241. [https://doi.org/10.1016/S0090-3019\(96\)00013-4](https://doi.org/10.1016/S0090-3019(96)00013-4).
- Ernst, G., Qeadan, F., Carlson, A.P., 2018. Subcutaneous bone flap storage after emergency craniectomy: cost-effectiveness and rate of resorption. *J. Neurosurg.* 129, 1604–1610. <https://doi.org/10.3171/2017.6.JNS17943>.
- Fattahian, R., Bagheri, S.R., Sadeghi, M., 2018. Development of posttraumatic hydrocephalus requiring ventriculoperitoneal shunt after decompressive craniectomy for traumatic brain injury: a systematic review and meta-analysis of retrospective studies. *Med. Arch.* 72, 214–219. <https://doi.org/10.5455/medarch.2018.72.214-219>.
- Fekry Elshirbiny, M., Ahmed, A., Mohsen Amen, M., 2023. Autograft cranioplasty for skull defects in children. *Interdisciplinary Neurosurgery* 33, 101789. <https://doi.org/10.1016/j.inat.2023.101789>.
- Feroze, A.H., Walmsley, G.G., Choudhri, O., Lorenz, H.P., Grant, G.A., Edwards, M.S.B., 2015. Evolution of cranioplasty techniques in neurosurgery: historical review, pediatric considerations, and current trends. *J. Neurosurg.* 123, 1098–1107. <https://doi.org/10.3171/2014.11.JNS14622>.
- Fodstad, H., Love, J.A., Ekstedt, J., Fridén, H., Liliequist, B., 1984. Effect of cranioplasty on cerebrospinal fluid hydrodynamics in patients with the syndrome of the trephined. *Acta Neurochir.* 70, 21–30. <https://doi.org/10.1007/BF01406039>.
- Giese, H., Anritter, J., Unterberg, A., Beynon, C., 2021a. Long-Term results of neurological outcome, quality of life, and cosmetic outcome after cranioplastic surgery: a single center study of 202 patients. *Front. Neurol.* 12, 702339. <https://doi.org/10.3389/fneur.2021.702339>.
- Giese, H., Meyer, J., Unterberg, A., Beynon, C., 2021b. Long-term complications and implant survival rates after cranioplastic surgery: a single-center study of 392 patients. *Neurosurg. Rev.* 44, 1755–1763. <https://doi.org/10.1007/s10143-020-01374-4>.
- Iaccarino, C., Chibbaro, S., Sauvigny, T., Timofeev, I., Zaed, I., Franchetti, S., Mee, H., Belli, A., Buki, A., De Bonis, P., et al., 2024. Consensus-based recommendations for diagnosis and surgical management of cranioplasty and post-traumatic hydrocephalus from a European panel. *Brain and Spine* 4, 102761. <https://doi.org/10.1016/j.bas.2024.102761>.
- Korhonen, T.K., Tetri, S., Huttunen, J., Lindgren, A., Piitulainen, J.M., Serlo, W., Vallittu, P.K., Posti, J.P., 2018. Predictors of primary autograft cranioplasty survival and resorption after craniectomy. *J. Neurosurg.* 130, 1672–1679. <https://doi.org/10.3171/2017.12.JNS172013>.
- LA Porta, F., Formisano, R., Iaccarino, C., Lavezzi, S., Pompucci, A., Estraneo, A., DE Tanti, A., Respondents to the survey prepared by the Special Interest Group on sABI and DoC of the Italian Society of Neurorehabilitation (SIRN sABI&DoC-SIG) in preparation for the International Consensus Meeting on Post-Traumatic Cranioplasty, 2023. When the practice does not meet the theory: results from an Italian survey on the clinical and pathway management of inpatients with decompressive craniectomy or cranioplasty admitted to rehabilitation. *Eur. J. Phys. Rehabil. Med.* 59, 303–316. <https://doi.org/10.23736/S1973-9087.23.07754-7>.
- Mah, J.K., Kass, R.A., 2016. The impact of cranioplasty on cerebral blood flow and its correlation with clinical outcome in patients underwent decompressive craniectomy. *Asian J Neurosurg* 11, 15–21. <https://doi.org/10.4103/1793-5482.172593>.
- Malcolm, J.G., Rindler, R.S., Chu, J.K., Chokshi, F., Grossberg, J.A., Pradilla, G., Ahmad, F.U., 2018. Early cranioplasty is associated with greater neurological improvement: a systematic review and meta-analysis. *Neurosurgery* 82, 278–288. <https://doi.org/10.1093/neuros/nyx182>.
- Marinkovic, I., Strbian, D., Pedrono, E., Vekovisheva, O.Y., Shekhar, S., Durukan, A., Korpi, E.R., Abo-Ramadan, U., Tatlisumak, T., 2009. Decompressive craniectomy for intracerebral hemorrhage. *Neurosurgery* 65, 780–786. <https://doi.org/10.1227/01.NEU.0000351775.30702.A9>, 1 pp. following 786; discussion 786.
- Martin, K.D., Franz, B., Kirsch, M., Polanski, W., von der Hagen, M., Schackert, G., Sobottka, S.B., 2014. Autologous bone flap cranioplasty following decompressive craniectomy is combined with a high complication rate in pediatric traumatic brain injury patients. *Acta Neurochir.* 156, 813–824. <https://doi.org/10.1007/s00701-014-2021-0>.
- Missori, P., Morselli, C., Domenicucci, M., 2014. Transplantation of autologous cranioplasty in Europe as part of bone organ. *Acta Neurochir.* 156, 2015–2016. <https://doi.org/10.1007/s00701-014-2207-5>.
- Morton, R.P., Abecassis, J.J., Hanson, J.F., Barber, J.K., Chen, M., Kelly, C.M., Nerva, J. D., Emerson, S.N., Ene, C.I., Levitt, M.R., et al., 2018. Timing of cranioplasty: a 10.75-year single-center analysis of 754 patients. *J. Neurosurg.* 128, 1648–1652. <https://doi.org/10.3171/2016.11.JNS161917>.
- Panwar, N., Agrawal, M., Sinha, V.D., 2019. Postcranioplasty quantitative assessment of intracranial fluid dynamics and its impact on neurocognition cranioplasty effect: a pilot study. *World Neurosurgery* 122, e96–e107. <https://doi.org/10.1016/j.wneu.2018.09.108>.
- Parichay, P.J., Khanapure, K., Joshi, K.C., Aniruddha, T.J., Sandhya, M., Hegde, A.S., 2017. Clinical and radiological assessment of cerebral hemodynamics after cranioplasty for decompressive craniectomy – a Clinical study. *J. Clin. Neurosci.* 42, 97–101. <https://doi.org/10.1016/j.jocn.2017.04.005>.
- Patel, P.D., Khanna, O., Gooch, M.R., Glener, S.R., Mouchtouris, N., Momin, A.A., Sioutas, G., Amllay, A., Barsouk, A., El Naamani, K., et al., 2023. Clinical outcomes after ultra-early cranioplasty using craniectomy contour classification as a patient selection criterion. *Oper Neurosurg (Hagerstown)* 25, 72–80. <https://doi.org/10.1227/ons.0000000000000689>.
- Piedra, M.P., Thompson, E.M., Selden, N.R., Ragel, B.T., Guillaume, D.J., 2012. Optimal timing of autologous cranioplasty after decompressive craniectomy in children. *J. Neurosurg. Pediatr.* 10, 268–272. <https://doi.org/10.3171/2012.6.PEDS1268>.
- Piitulainen, J.M., Posti, J.P., Vallittu, P.K., Aitasalo, K.M., Serlo, W., 2019. A large calvarial bone defect in a child: osseointegration of an implant. *World Neurosurg* 124, 282–286. <https://doi.org/10.1016/j.wneu.2019.01.028>.
- Posti, J.P., Piitulainen, J.M., Hupa, L., Fagerlund, S., Frantzen, J., Aitasalo, K.M.J., Vuorinen, V., Serlo, W., Syrjänen, S., Vallittu, P.K., 2016. A glass fiber-reinforced composite – bioactive glass cranioplasty implant: a case study of an early development stage implant removed due to a late infection. *J. Mech. Behav. Biomed. Mater.* 55, 191–200. <https://doi.org/10.1016/j.jmbbm.2015.10.030>.
- Primalani, N.K., Chew, K.Y., Ramachandran, S., Ng, L.P., Low, D.C., Seow, W.T., Low, S. Y., 2022. Paediatric cranioplasty—experience from a Singapore children's hospital. *Interdisciplinary Neurosurgery* 30, 101606. <https://doi.org/10.1016/j.inat.2022.101606>.
- Qiu, X., Wang, D., Chen, L., Huang, G., Zhou, X., Chen, Q., Wang, Z., 2023. The compensatory mechanism and clinical significance of hydrocephalus after cranioplasty. *Front. Neurol.* 13. <https://doi.org/10.3389/fneur.2022.1075137>.
- Rashidi, A., Sandalcioglu, I.E., Luchtman, M., 2020. Aseptic bone-flap resorption after cranioplasty - incidence and risk factors. *PLoS One* 15, e0228009. <https://doi.org/10.1371/journal.pone.0228009>.
- Ringel, F., Stoffel, M., Krieg, S.M., Schöller, K., Gerlach, R., Conzen, M., Schuss, P., Kreutzer, J., Beck, J., 2023. Structure of neurosurgical care in Germany in comparison to countries organized in the European association of neurosurgical societies: a need to reorganize neurosurgical training and care in Germany. *J. Neurol. Surg. Cent. Eur. Neurosurg.* 84, 305–315. <https://doi.org/10.1055/a-1982-3976>.
- Rocque, B.G., Agee, B.S., Thompson, E.M., Piedra, M., Baird, L.C., Selden, N.R., Greene, S., Deibert, C.P., Hankinson, T.C., Lew, S.M., et al., 2018. Complications following pediatric cranioplasty after decompressive craniectomy: a multicenter retrospective study. *J. Neurosurg. Pediatr.* 22, 225–232. <https://doi.org/10.3171/2018.3.PEDS17234>.
- Rosinski, C.L., Behbahani, M., Geever, B., Chaker, A.N., Patel, S., Chiu, R., Zakrzewski, J., Rosenberg, D., Parola, R., Shah, K., et al., 2020. Concurrent versus staged procedures for ventriculoperitoneal shunt and cranioplasty: a 10-year retrospective comparative analysis of surgical outcomes. *World Neurosurg* 143, e648–e655. <https://doi.org/10.1016/j.wneu.2020.08.062>.
- Salam, A.A., Ibbett, I., Thani, N., 2018. Paediatric cranioplasty: a review. *Interdisciplinary Neurosurgery* 13, 59–65. <https://doi.org/10.1016/j.inat.2018.03.004>.
- Sauvigny, T., Giese, H., Höhne, J., Schebesch, K.M., Henker, C., Strauss, A., Besoglu, K., Spreckelsen, N. von, Hampf, J.A., Walter, J., et al., 2021. A multicenter cohort study of early complications after cranioplasty: results of the German Cranial Reconstruction Registry. *J. Neurosurg.* 1–8. <https://doi.org/10.3171/2021.9.JNS211549>.
- Siracusa, V., Maimone, G., Antonelli, V., 2021. State-of-Art of standard and innovative materials used in cranioplasty. *Polymers* 13, 1452. <https://doi.org/10.3390/polym13091452>.
- van Essen, T.A., van Erp, I.A.M., Lingsma, H.F., Piscià, D., Yue, J.K., Singh, R.D., van Dijk, J.T.J.M., Volovici, V., Younsi, A., Koliass, A., et al., 2023. Comparative effectiveness of decompressive craniectomy versus craniotomy for traumatic acute subdural hematoma (CENTER-TBI): an observational cohort study. *eClinicalMedicine* 63. <https://doi.org/10.1016/j.eclinm.2023.102161>.
- Wang, K., Guo, H., Zhu, Y., Li, J., Niu, H., Wang, Y., Cai, X., 2023. Improved strategy for post-traumatic hydrocephalus following decompressive craniectomy: experience of a single center. *Front. Surg.* 9. <https://doi.org/10.3389/fsurg.2022.935171>.
- Wu, Y.-C., Liao, H.-C., Lin, J.-C., Chou, Y.-C., Ju, D.-T., Hwang, D.-Y., Tang, C.-T., Tseng, K.-Y., Chou, K.-N., Lin, B.-J., et al., 2022. Risk factors of postoperative hydrocephalus following decompressive craniectomy for spontaneous intracranial hemorrhages and intraventricular hemorrhage. *Medicine (Baltimore)* 101, e31086. <https://doi.org/10.1097/MD.00000000000031086>.
- Yan, Z., Zhang, H., Zhang, Z., Wang, X., Wei, M., Wang, X., 2022. Clinical study of cranioplasty combined with ipsilateral ventriculoperitoneal shunt in the treatment of

- skull defects with hydrocephalus. *J. Craniofac. Surg.* 33, 289. <https://doi.org/10.1097/SCS.00000000000008227>.
- Yang, X.-F., Wang, H., Wen, L., Huang, X., Li, G., Gong, J.-B., 2017. The safety of simultaneous cranioplasty and shunt implantation. *Brain Inj.* 31, 1651–1655. <https://doi.org/10.1080/02699052.2017.1332781>.
- Zhou, Q., Shen, W., Zhou, Z., Yang, X., Wen, L., 2022. Is simultaneous cranioplasty with cerebrospinal fluid shunts implantation as safe as staged procedures? *Front. Neurol.* 13, 995897. <https://doi.org/10.3389/fneur.2022.995897>.
- Zweckberger, K., Juettler, E., Bösel, J., Unterberg, W.A., 2014. Surgical aspects of decompression craniectomy in malignant stroke: review. *Cerebrovasc. Dis.* 38, 313–323. <https://doi.org/10.1159/000365864>.