




## ORIGINAL RESEARCH

# Magnetic resonance guided high intensity focused ultrasound (MR-HIFU) effectively reduces fibroid-related symptoms and improves quality of life—A prospective single-centre 12-month follow-up study

Saara Otonkoski<sup>1,2</sup>  | Antti Viitala<sup>2,3</sup> | Gaber Komar<sup>2,3</sup> | Teija Sainio<sup>2,4</sup> |  
Anna Yanovskiy<sup>2,3</sup> | Roberto Blanco Sequieros<sup>2,3</sup> | Antti Perheentupa<sup>1,2</sup>  |  
Kirsi Joronen<sup>1,2</sup> 

<sup>1</sup>Department of Obstetrics and Gynaecology, Turku University Hospital, Turku, Finland

<sup>2</sup>University of Turku, Turku, Finland

<sup>3</sup>Department of Radiology, Turku University Hospital, Turku, Finland

<sup>4</sup>Department of Medical Physics, Turku University Hospital, Turku, Finland

## Correspondence

Saara Otonkoski, Department of Obstetrics and Gynaecology, Turku University Hospital, Kuusitie 23, 21620 Kuusisto, Finland.  
Email: [saara.otonkoski@varha.fi](mailto:saara.otonkoski@varha.fi)

## Funding information

Finnish Government Research Funding

## Abstract

**Introduction:** Uterine fibroids are the most common benign tumors among women, and it is estimated that approximately 70% of women have one or multiple fibroids by the age of menopause. About 30% of these women suffer from symptoms related to the fibroids. Magnetic resonance-guided high-intensity focused ultrasound (MR-HIFU) is a novel, non-invasive treatment method for symptomatic uterine fibroids.

**Material and Methods:** In this prospective, single-centre follow-up study, 175 women with symptomatic uterine fibroids were treated with MR-HIFU. The effect of MR-HIFU on fibroid symptoms and quality of life was evaluated using a uterine fibroid-specific quality of life questionnaire (UFS-QoL). The main outcome measure was the symptom severity score and quality of life (QoL) before the MR-HIFU and 3 and 12 months after the treatment. This study was registered at [clinicaltrials.gov](https://clinicaltrials.gov) (NCT03937401).

**Results:** The median symptom severity score decreased from 56 (IQR 44–69) at baseline to 28 (IQR 16–44) at 3 months ( $p < 0.01$ ) and 25 (IQR 16–38) at 12 months ( $p < 0.01$ ) after treatment. The QoL score increased from a median of 48 (IQR 33–66) at baseline to 73 (IQR 59–93) at 3 months ( $p < 0.01$ ) and 78 (IQR 66–90) at 12 months after treatment ( $p < 0.01$ ). The reintervention rate during the 12-month follow-up was 2%.

**Conclusions:** MR-HIFU significantly reduces the severity of fibroid-related symptoms in selected patients as early as 3 months after MR-HIFU. The effect persists at 12 months. There is also a significant improvement in the quality of life 3 months after treatment, which further increases at 12 months.

**Abbreviations:** MR, magnetic resonance; MR-HIFU, magnetic resonance-guided high-intensity focused ultrasound; NPV, non-perfused volume; SSS, symptom severity score; UAE, uterine artery embolization; UFS-QoL, Uterine fibroid-specific-quality of life.

This is an open access article under the terms of the [Creative Commons Attribution-NonCommercial-NoDerivs](https://creativecommons.org/licenses/by-nc-nd/4.0/) License, which permits use and distribution in any medium, provided the original work is properly cited, the use is non-commercial and no modifications or adaptations are made.

© 2025 The Author(s). *Acta Obstetrica et Gynecologica Scandinavica* published by John Wiley & Sons Ltd on behalf of Nordic Federation of Societies of Obstetrics and Gynecology (NFOG).

## KEYWORDS

fibroid, MR-HIFU, quality of life, uterine fibroid

## 1 | INTRODUCTION

Uterine fibroids are the most common benign neoplasms in women, occurring in up to 70% of women by menopause.<sup>1,2</sup> A third of these women develop symptoms, reducing their quality of life. The symptoms most commonly related to uterine fibroids are menorrhagia or other bleeding disorders and various pain or bulk symptoms. Uterine fibroids can interfere with fertility, being associated with miscarriages and infertility.<sup>2,3</sup>

There are multiple ways to treat fibroid symptoms. Several types of pharmacological agents are available.<sup>4</sup> Medical therapy, however, requires long-term compliance since the symptoms usually return if the medication is discontinued. Operative options include hysterectomy or myomectomy. Less invasive radiological treatment methods are uterine artery embolization (UAE) and high-intensity focused ultrasound (HIFU).<sup>5-8</sup> Magnetic resonance-guided HIFU (MR-HIFU) is a non-invasive thermal ablation method based on the rapid heating of the target tissue. The procedure is performed under real-time magnetic resonance imaging, offering excellent image guidance and simultaneous temperature monitoring.<sup>6,9</sup> Unlike UAE and hysterectomy, MR-HIFU is a viable option for women seeking future pregnancies. Earlier studies have shown that no negative effect on ovarian reserve is caused by MR-HIFU, and also normal pregnancies after HIFU treatment have been reported in several studies.<sup>10,11</sup> The technical treatment success of MR-HIFU is assessed by calculating the non-perfused volume (NPV), which is the volume of the fibroid ablated during the treatment.

MR-HIFU offers several benefits in the treatment of symptomatic fibroids. However, the treatment is not suitable for all fibroids, and the histological structure and vascularisation of the fibroid, for example, affect treatment efficacy. Radiologically, fibroids are a heterogeneous group of tumors, and various parameters can be assessed from preoperative MR images and used to predict treatment efficacy. Most often, the so-called Funaki classification, in which the fibroids are classified into three classes by their signal intensity in a T2-weighted MR image, is used.<sup>12</sup> In addition, other parameters such as apparent diffusion coefficient and fibroid perfusion should be included in the preoperative analysis to improve the treatment success.<sup>12,13</sup>

The modern concept of fibroid treatment highlights the clinical outcomes of the various therapies, since the main objective is to offer the patients sustainable symptom relief and improvement in quality of life by means of therapy that is the least invasive and safest possible. A commonly used clinical assessment tool is the validated uterine fibroid-specific symptom and quality of life questionnaire (UFS-QoL). It consists of questions both regarding the fibroid symptom severity (symptom severity score, SSS) as well as the effect of fibroid symptoms on different aspects of quality of life

### Key message

Uterine fibroids are common benign tumors that cause symptoms decreasing the quality of life for many women. MR-HIFU is a non-invasive treatment method that significantly reduces the severity of fibroid-related symptoms in selected patients.

(QoL).<sup>14</sup> Here we report the clinical outcome assessed with the UFS-QoL questionnaire of patients treated for uterine fibroids in Turku, Finland, since 2016.

## 2 | MATERIAL AND METHODS

A total of 175 women were recruited in this prospective, single-center follow-up study between May 2016 and November 2023. All patients had at least one symptomatic uterine fibroid, as evaluated in the gynecological department of Turku University Hospital, and were deemed suitable for MR-HIFU treatment. Written informed consent was obtained from all patients. The patients were initially referred to the gynecological department for evaluation of symptoms and their relation to the fibroid. All available treatment options were carefully discussed with the patients. Patients considered clinically suitable for MR-HIFU were referred for MR imaging to evaluate the technical suitability of the treatment. For each patient, a team consisting of experienced practitioners, one gynecologist, and one radiologist (KJ and GK) carried out the evaluation of suitability for MR-HIFU. A significant proportion of the patients were found to be unsuitable for the treatment. However, no record of these rejected patients was kept, and the exact proportion is not known. Our screening protocol for assessing the patients' suitability for MR-HIFU treatment is written in more detail in [Appendix S1](#).

The primary outcome of this study was the effect of MR-HIFU treatment on the patient's fibroid-related symptoms. The secondary outcome was the reintervention rate.

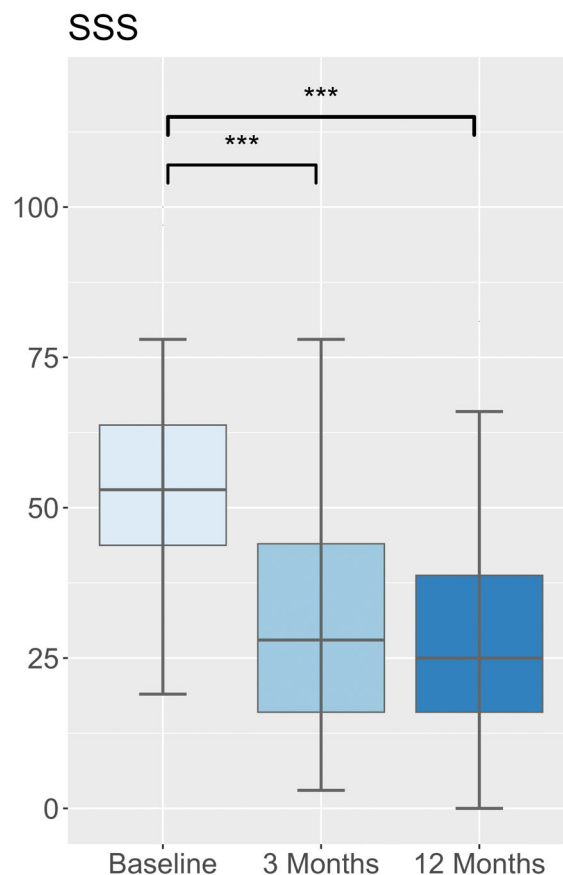
Planning MR images were obtained shortly before the treatment, and control images were obtained after the treatment to confirm the results. The NPV was defined immediately after the treatment. NPV values were determined by our radiologist (AY), who manually outlined the non-enhancing part of the treated fibroid on contrast-enhanced T1 weighted MR images and compared that to the whole volume of the fibroid, which was determined using T2 weighted MR images. Volumes were calculated using GE AW server 3.2 (GE HealthCare, Chicago, Illinois, USA).

The patients filled in the UFS-QoL questionnaire before the treatment, and this is taken as the baseline in our study. All patients were seen 3 months after the treatment, and this appointment included the UFS-QoL questionnaire, a clinical evaluation with a gynecological ultrasound, and an MRI. The same protocol was performed 12 months after the treatment. If a patient failed to make a follow-up visit and was not reached after two attempts from the hospital, the patient was considered as lost to follow-up.

All the treatments were performed using an extracorporeal tabletop MR-HIFU system (Sonalleve V2, Profound medical Inc., Mississauga, Canada). The treatment planning was conducted by positioning the ellipsoid treatment cells into the targeted fibroid. This was performed one by one to cover the whole fibroid. Test sonication was carried out, and the treatment power was selected based on it. The aim was to achieve the best possible temperature rise in the target tissue. The possible undesired heating of the surrounding tissues and the heating of the targeted area were monitored with real-time MR thermometry. The technical objective of the treatment was to ablate as much of the fibroid tissue as possible in those fibroids considered relevant with respect to the symptoms. During the treatment, intravenous oxytocin (40IU of oxytocin, Syntocinon 8.3 µg/mL, Sigma-Tau Industrie Farmaceutiche Riunite S. p. A, diluted to 500 mL of NaCl 0.9%) was infused at a rate of 5 mL/min to reduce the blood flow in the fibroids.<sup>15</sup> After the treatment, the NPV was evaluated from a contrast-enhanced T1-weighted image acquired by injecting the contrast agent (DOTAREM, Guerbet, Aulnay-Sous-Bois, France, 0.1 mmol/kg). NPV% was calculated for each patient.

Clinical evaluation of the efficacy of MR-HIFU on fibroid-related symptoms was performed using the UFS-QoL questionnaire. The first part of the questionnaire is about the severity of the fibroid symptoms (SSS) and the second part about the fibroids effect on the quality of life (the quality of life questionnaire, QoL). The quality of life questionnaire is also divided into subgroups; Concern (five questions); Activities (seven questions); Energy/Mood (seven questions); Control (five questions); Self-Consciousness (three questions); Sexual Function (two questions). The total quality of life score (HRQoL) consists of the sum of the subgroup results. All of the questions have responses on a five-point scale, the options being from 'none of the time' or 'not at all' to 'all of the time' or 'a very great deal'. The results are calculated with set formulas that provide the SSS and QoL. With the SSS, the minimum score is 0 and the maximum 100, a higher score indicating greater severity of symptoms. With the QoL, the minimum is 0 and the maximum 100, a higher score indicating a better quality of life. The analyses were conducted by using all of these questionnaires, even if one patient did not have responses for all of the timepoints. In addition, we made supplementary analyses using the patient series with responses to all of the timepoints, and gained similar results. These are shown in Figures 1 and 2.

Statistical analysis was conducted in RStudio 2022.07.2 Build 576 (RStudio, PBC, Boston, USA) using R version 4.2.2 (R: A language and



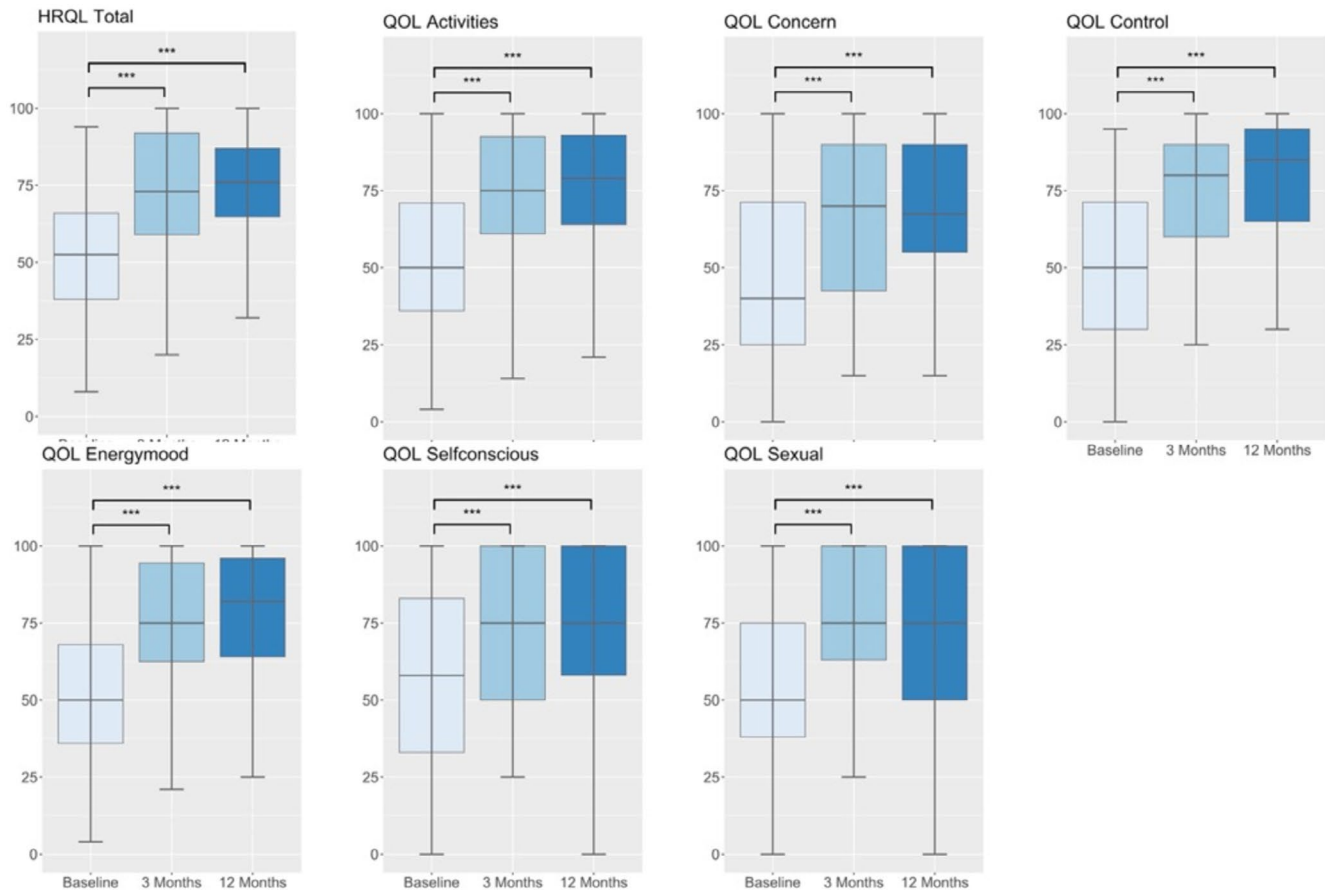
**FIGURE 1** Symptom Severity Score (SSS) at baseline, 3 months, and 12 months based on the patient series with responses to all of the timepoints. \*\*\* $P < 0.001$ .

environment for statistical computing. R Foundation for Statistical Computing, Vienna, Austria).

For all the outcome parameters, we used the Shapiro–Wilk test and visual density distribution evaluation to assess whether the data was normally distributed. Since the majority of the parameters were found not to be normally distributed, a paired Wilcoxon signed-rank test was used to calculate the statistical significance of parameter changes between time points. The full R is available online.<sup>16</sup>

### 3 | RESULTS

All the women included in this study were premenopausal. The median age of the women was 39 years (range 24–57) and the median body mass index (BMI) was 24 (range 18–39). At baseline, 55 (31%) of the women were using hormonal contraception, and they continued with the same medication throughout the follow-up. Eight women were using ulipristal acetate medication at the outset and four were on relugolix/estradiol/norethisterone acetate. All of these women continued their medication until at least the first follow-up at 3 months. Information was obtained about the medication potentially increasing bleeding (two patients with warfarin



**FIGURE 2** Total quality of life score (HRQoL) at baseline, 3 months, and 12 months based on the patient series with responses to all of the timepoints. \*\*\* $P < 0.001$ .

and one mini-heparin) or decreasing bleeding (27 patients using tranexamic acid). Sixty-four women (38%) had had earlier successful pregnancies.

Detailed information about the leading symptom was gathered. 42 (25%) women had more than one leading symptom. A total of 127 (73%) women had a leading symptom related to menstrual bleeding: menorrhagia or menometrorrhagia. Fifty women (29%) had bulk symptoms such as a feeling of abdominal pressure or frequent urination. For 33 (19%) women, the leading symptom was pain, that is, abdominal pain, dysmenorrhea, or dyspareunia. Infertility was the leading symptom for eight (5%) patients. The women in this group had experienced unsuccessful in vitro fertilization or recurrent miscarriages, for instance. 22 (13%) women had had an earlier hysteroscopy for the fibroid, and five had had multiple hysteroscopies. Five (3%) women had had a myomectomy by either laparoscopy or laparotomy. Only three (2%) women needed reintervention during follow-up at 12 months: one myomectomy and two hysterectomies.

The parameters regarding the patients and the fibroids are shown in [Table 1](#).

The fibroids treated were of various sizes, locations, and vascularization. In some patients, multiple fibroids were treated, but no data was kept on the number of fibroids treated per woman.

In clinical practice and studies, the FIGO classification is used to classify fibroid location.<sup>4</sup> In our study population, the fibroids were divided into FIGO groups as follows: seven fibroids (4%) of type FIGO 0; 24 (12%) of FIGO 1; 52 (26%) of FIGO 2; 64 (32%) of FIGO 3; 20 (10%) of FIGO 4; 17 (9%) of FIGO 5; and 15 (8%) of FIGO 6. A total of 109 (54%) of the fibroids were located in the anterior wall of the uterus, 20 (10%) in the fundus, 20 (10%) in the lateral wall and 51 (25%) in the posterior wall. In addition, there was one fibroid (0.5%) located in the cervix, and the location of one (0.5%) was unclear. In addition, the signal intensity of the fibroids was assessed: there were 22 (11%) fibroids of Funaki group 1, 159 (80%) of Funaki group 2, and 17 (9%) of Funaki group 3. Before the treatment, the median volume of the fibroids was 63 mL (IQ range 18–134), corresponding to a diameter of approximately 4.9 cm.

In these MR-HIFU treatments, the median NPV% was 69 (IQ range 47–89). There were five complications: two first-degree skin burns treated with a topical agent and anti-inflammatory medication (group B according to SIR criteria), one pulmonary embolization that was diagnosed 2 weeks after the MR-HIFU, and two nonspecific inflammatory reactions (group C according to SIR criteria). One of the two resulted in fever, leukocytosis, and a high C-reactive protein and was similar to post-embolization syndrome. This patient recovered

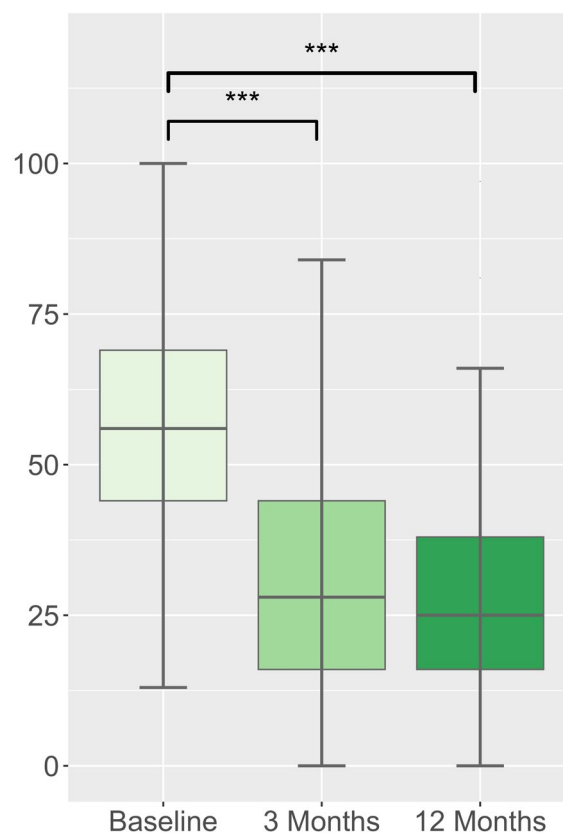
**TABLE 1** Parameters regarding the patients and the fibroids included in the study.

Parameters	
Number of patients	175
Age (median, range)	39 (24–57)
BMI (median, range)	24 (18–39)
Hormonal contraception	
Yes	55 (31%)
No	120 (69%)
Fibroid medication	
Ulipristal acetate	8 (5%)
Relugolix	4 (2%)
Medication affecting blood coagulation	
Warfarin	2 (1%)
Mini-heparin	1 (0.6%)
Tranexamic acid	27 (15%)
Earlier fibroid treatments	
Hysteroscopy	22 (13%)
Myomectomy	5 (3%)
Leading symptom	
Bleeding symptom	127 (73%)
Bulk symptom	50 (29%)
Pain	33 (19%)
Infertility	8 (5%)
More than one leading symptom	42 (25%)
Earlier fibroid treatments	
Hysteroscopy	22 (13%)
Myomectomy	5 (3%)
FIGO groups (number of fibroids)	
FIGO 0	7 (4%)
FIGO 1	24 (12%)
FIGO 2	52 (26%)
FIGO 3	64 (32%)
FIGO 4	20 (10%)
FIGO 5	17 (9%)
FIGO 6	15 (8%)
Funaki groups (number of fibroids)	
Funaki 1	22 (11%)
Funaki 2	159 (80%)
Funaki 3	17 (9%)

after a short hospital stay. The other patient had low fever, bleeding, and abdominal pain for 2 weeks after the treatment but also recovered and did not need further treatment. Three women needed a reintervention: one myomectomy and two hysterectomies. The reintervention rate at 1 year was 2%.

A total of 129 patients answered the baseline questionnaire, 118 the questionnaire at 3 months, and 91 the questionnaire at 12 months. The clinical follow-up demonstrated a significant

## SSS



**FIGURE 3** Symptom Severity Score (SSS) at baseline, 3 months, and 12 months. \*\*\* $P < 0.001$ .

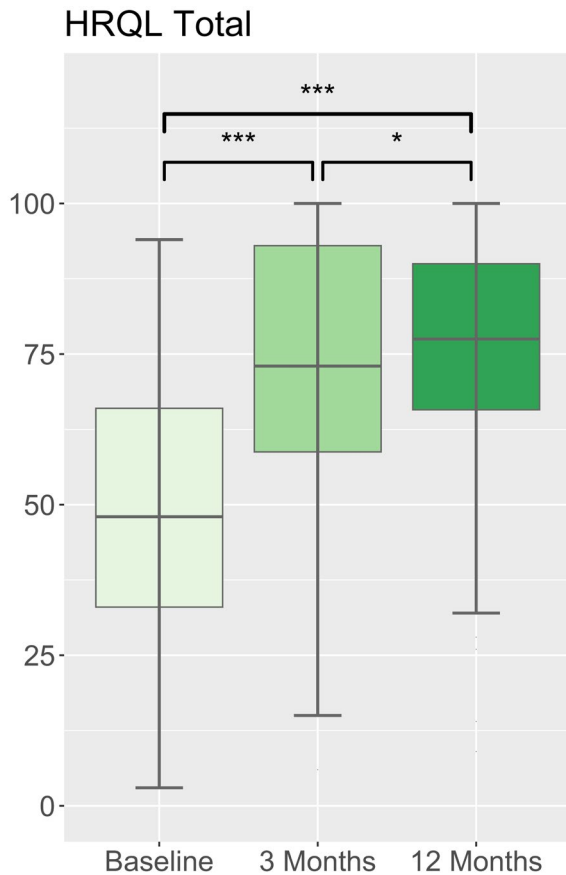
reduction in fibroid-related symptoms as well as an improvement in quality of life. The median SSS decreased from 56 (IQR 44–69) at the baseline to 28 (IQR 16–44) 3 months and to 25 (IQR 16–38) 12 months after treatment. The change was significant from the baseline to 3 and 12 months ( $p < 0.01$  and  $p < 0.01$  respectively) but not from 3 to 12 months ( $p = 0.3$ ). The SSS at the baseline, 3 months, and 12 months is shown in [Figure 3](#).

Accordingly, the QoL score increased from a median of 48 (IQR 33–66) at the baseline to 73 (IQR 59–93) 3 months ( $p < 0.01$ ) and 78 (IQR 66–90) 12 months after treatment ( $p < 0.01$ ). Unlike SSS, the change in the QoL was also statistically significant between 3 and 12 months after treatment ( $p = 0.02$ ). The QoL at the baseline, 3 months, and 12 months is shown in [Figure 4](#).

The QoL results were also analyzed according to subgroups.

In the subgroup Concern, the median QoL score at the baseline was 35 (IQR 20–65), at 3 months 65 (IQR 45–90), and at 12 months 70 (IQR 55–90). The change was statistically significant between the baseline and 3 months ( $p < 0.01$ ) and between the baseline and 12 months ( $p < 0.01$ ).

In the subgroup Activities, the baseline median QoL score was 46 (IQR 29–71), at 3 months 75 (IQR 57–96) and at 12 months 82 (IQR 64–93). The change was statistically significant between the baseline and 3 months and between the baseline and 12 months ( $p < 0.01$  and  $p < 0.01$  respectively).



**FIGURE 4** Total quality of life score (HRQoL) at baseline, 3 months, and 12 months. \* $P < 0.05$ , \*\*\* $P < 0.001$ .

In the subgroup Energy/Mood, at the baseline the median QoL score was 46 (IQR 31–68), at 3 months 77 (IQR 61–95) and at 12 months 82 (IQR 64–100), with the change also statistically significant at the timepoints of 3 months ( $p < 0.01$ ) and 12 months ( $p < 0.01$ ) compared to the baseline.

In the subgroup Control, the baseline QoL median was 50 (IQR 30–70), at 3 months 80 (IQR 56–95), and at 12 months 85 (IQR 65–100). The change was statistically significant at 3 months compared to the baseline ( $p < 0.01$ ) and at 12 months compared to the baseline ( $p < 0.01$ ).

In the subgroup Self-Consciousness, at the baseline the median QoL score was 58 (IQR 25–75), at 3 months 75 (IQR 54–100), and at 12 months 75 (IQR 58–92). The change was statistically significant at 3 months ( $p < 0.01$ ) and 12 months ( $p < 0.01$ ) compared to the baseline.

In the subgroup Sexual, at baseline, the median QoL score was 50 (IQR 25–75), at 3 months 75 (IQR 50–100) and at 12 months 75 (IQR 50–100), the change being statistically significant between the timepoints baseline to 3 months ( $p < 0.01$ ) and baseline to 12 months ( $p < 0.01$ ).

In all the subgroups, the QoL scores were significantly higher at both 3 months and 12 months compared to the baseline. The QoL subgroups Concern, Activities, Energy/Mood, Control, Self-Consciousness, and Sexual are shown in [Figure 5](#).

## 4 | DISCUSSION

In this paper, we present the results of our prospective single-center study demonstrating the effectiveness of MR-HIFU in treating uterine fibroid-related symptoms over a follow-up period of 12 months. Uterine fibroids are the most common tumors in women of reproductive age, and even though benign, they are known to often significantly impact patients' quality of life. With an estimated annual cost of 34 billion dollars in the United States, they represent an important burden for healthcare systems all over the world.<sup>17</sup> Since there are currently no effective methods to inhibit the development of fibroids, it is very important to attempt to develop minimally invasive or non-invasive treatments that are also cost-effective.

Uterine fibroids are a common benign indication for hysterectomy. However, recently there has been a major decrease in hysterectomies performed for uterine fibroids, and in Finland, the lifetime risk of undergoing hysterectomy for a uterine fibroid has decreased from 12.8% to 4.2% in the last 30 years.<sup>18</sup> This is largely due to the development of treatment options for menstrual disorders (such as the hormonal intrauterine device, IUD). Nevertheless, this phenomenon may in part be attributed to the changing attitude of women regarding major surgery, with women increasingly opting for less invasive treatment options that offer effective and sustainable symptom relief.

In our study, we have demonstrated that MR-HIFU is efficient in treating fibroid-related symptoms and improving the quality of life of patients. For both of the parameters measured, there was a clear improvement 3 months after treatment, and the response was maintained (SSS) or even improved (QoL) 12 months after treatment. Furthermore, comparing the baseline and the timepoint of 12 months, the change was significant.

According to a study published in 2002, in which the UFS-QoL questionnaire was established, the mean SSS of a healthy woman with no fibroid-related symptoms was 23, and the QoL was 86.<sup>14</sup> Considering this, it is clearly unrealistic to aim for lower scores with any fibroid treatment. Considering this, an SSS of 28 at 12 months and a QoL of 73 at 12 months do not differ much from the results for healthy control women. This significant improvement in symptom severity was achieved despite the median NPV% being less than 80, which is often the target when planning HIFU treatments.

We were surprised by the fairly rapid effect of MR-HIFU on fibroid symptoms at 3 months after the treatment, considering that the fibroids were not physically removed. In a meta-analysis published in *European Radiology* in 2022 by Liu et al., similar results were found, but the first follow-up was at 6 months after treatment instead of our 3-month time point.<sup>19</sup> A systematic review of minimally invasive approaches to uterine fibroids published in 2022 found a significant decrease in symptom severity from baseline to 6 months but not as early as 3 months. The rapid decrease in symptom severity could be explained by changes in the structure of the fibroid following the coagulative necrosis caused by the heating of the tissue. We speculate that this is the reason for

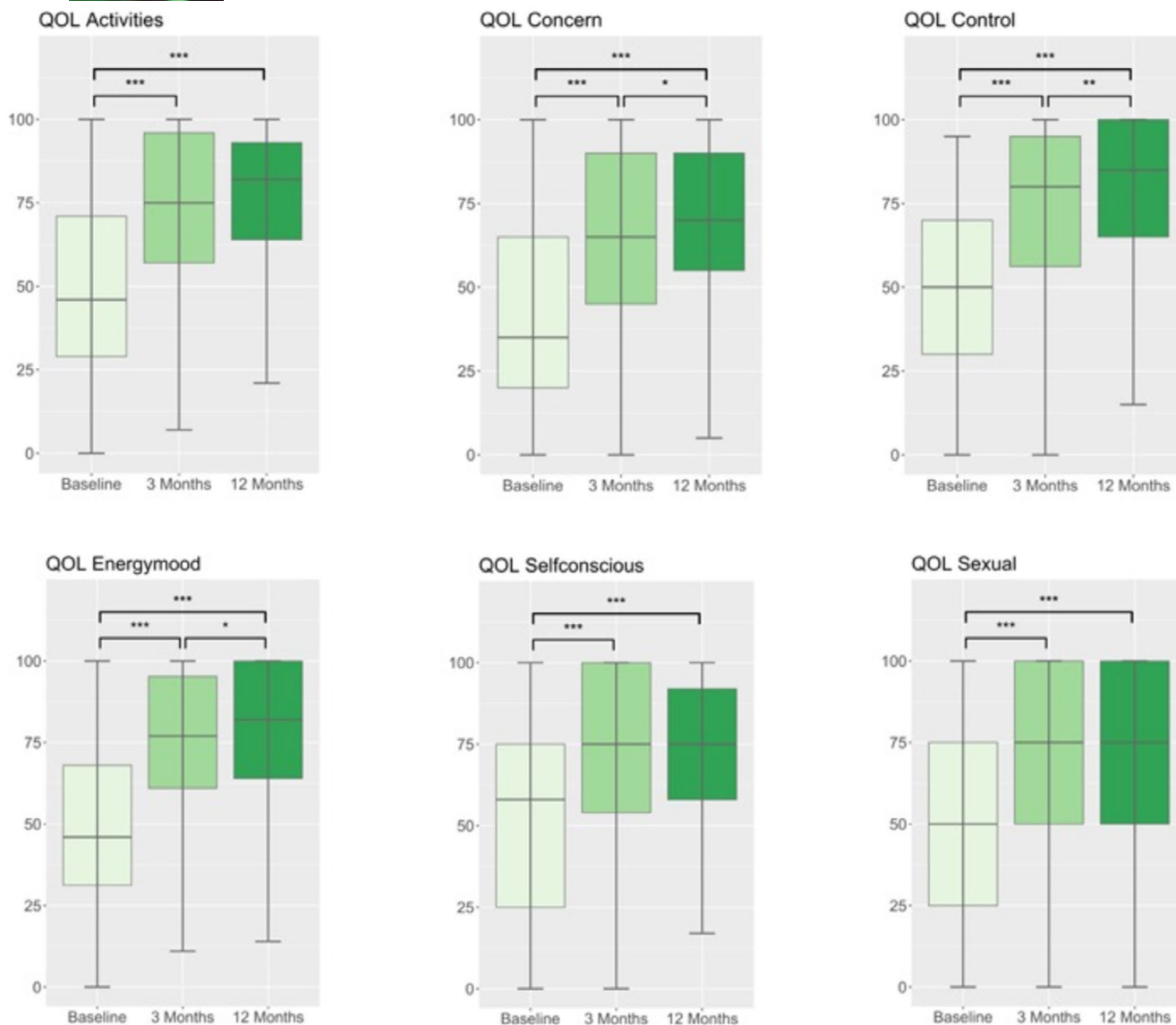


FIGURE 5 Quality of Life according to the subgroups. \* $P < 0.05$ , \*\* $P < 0.01$ , \*\*\* $P < 0.001$ .

the rapid relief of bulk symptoms even when the fibroid has not yet significantly shrunk in the MRI at 3 months. On the contrary, fibroids are biologically active tumors producing hormones and cytokines, which may disturb endometrial homeostasis and contribute to bleeding disorders.<sup>20</sup> Thus, inactivation of the fibroid tissue can also affect the molecular environment of the uterus and the endometrium.

The relief of fibroid symptoms demonstrated in our study is in accordance with previously published studies. In a meta-analysis by Liu et al., published in 2022, MR-HIFU was found to be superior to surgery in treating uterine fibroid symptoms and increasing quality of life with a follow-up time of 6–12 months. Symptom recurrence, reinterventions, and adverse events were comparable for these two treatment methods.<sup>19</sup> In an earlier review and meta-analysis published in 2018, HIFU was associated with the least favorable outcomes in decreasing fibroid symptom severity and increasing quality of life.<sup>21</sup> Mindjuk et al. published a single-center study of the clinical

results of MR-HIFU and the factors affecting clinical success. They found that the NPV ratio was highly correlated with treatment success, with an NPV% over 80 resulting in a clinical success for over 80% of patients. In their study, the reintervention rate was 12.7%, with a follow-up time of 19 months.<sup>12</sup> Despite similar, favorable results in the short term, the need for long-term results is emphasized by most of these studies.

Notwithstanding the relatively short follow-up time of 12 months, the reintervention rate for fibroid-related symptoms in our study was extremely low, only 2%. The previously reported reintervention rate for fibroid symptoms after MR-HIFU varies from 14% (24 months follow-up) to as high as 54% (60 months follow-up), depending on the duration of the follow-up.<sup>12,19,21,22</sup> For any uterine-sparing fibroid treatment, there is the evident risk of reintervention, due either to possible fibroid recurrence or to other non-fibroid-related symptoms. The reintervention rate after UAE is reported to be 1% at a follow-up time of 13 months and 14% at a

follow-up time of 60 months. Considering myomectomy, the rates are 1% (12 months follow-up) and 12% (60 months follow-up) respectively.<sup>1,21</sup> As we continue the follow-up of our patients, we expect the reintervention rate to increase. However, we do believe that identifying the risk factors for early or late reintervention is a crucial part of patient selection and treatment success in MR-HIFU. This has also been reported by other groups.<sup>23,24</sup>

Being a non-invasive treatment, MR-HIFU is patient-friendly; it can be performed in an outpatient setting and there is usually no need for absence from work and other daily life. When comparing MR-HIFU with the widely used Ultrasound-Guided High-Intensity Focused Ultrasound (US-HIFU), MR-HIFU offers superior image guidance and soft tissue contrast. Another advantage of MR-HIFU is the ability to perform real-time temperature monitoring during the treatment. In contrast, higher costs and poorer availability are the disadvantages of MR-HIFU when compared to US-HIFU.

As a disadvantage, we have observed that there is a significant learning curve associated with this treatment. Since MR-HIFU is not suitable for all patients, we believe that, in order to achieve good results, meticulous patient selection performed by a well-coordinated multidisciplinary team is essential. On the contrary, this makes direct comparison of MR-HIFU with other treatments (e.g., UAE) difficult.<sup>5</sup> Nevertheless, once the learning curve is overcome, MR-HIFU is able to offer a selected group of patients an effective treatment with very low complication and reintervention rates.

The strength of this study is its aim to demonstrate the effect of this relatively novel fibroid treatment on patients' symptoms instead of the pure technical outcome of MR-HIFU. Most of the data available on MR-HIFU consist of technical outcomes of the treatment instead of patient-centered outcomes such as symptom severity or quality of life. Fortunately, there are currently other studies focusing more on the patient-reported outcomes in various fibroid therapies.<sup>25</sup> Symptom relief is evidently the most important outcome parameter for the treating physician as well as the patient herself. Considering that MR-HIFU is a new treatment method in the Nordic countries, it is very important to publish the clinical results from the first 175 women treated with MR-HIFU in Finland. Another strength is that the study population is clearly over 100 women, which can be considered a fairly large group among MR-HIFU studies. The limitation of this study is the relatively short follow-up time of 12 months. It is clear that in the future, a longer follow-up is needed to evaluate the long-term symptom relief as well as to assess the reintervention rate after MR-HIFU. The patients in this study present a carefully selected subgroup of women suffering from fibroid symptoms. This can be seen as a limitation in the interpretation of our results since they may not necessarily correlate with the efficacy of MR-HIFU treatment in a general fibroid population. We do recognize the need for a randomized controlled trial (RCT) comparing different treatments, and it will be interesting to see whether the same kind of results will be provided in the currently running randomized trial studying the efficacy of various fibroid therapies including

MR-HIFU in a more unselected setting.<sup>25</sup> However, currently it is our belief that meticulous patient selection offers the best patient-related outcomes in MR-HIFU as well as other fibroid therapies and that RCTs might not be the best way to study the potential of each therapy since we do not know precisely what the strengths and weaknesses of each therapy are. We believe the results of our study will help shape future trials that will answer these questions.

This is the first report from MR-HIFU treatments in Finland, and our aim was to investigate the effect of this treatment on patients' symptoms in general. Our future goals are to study the effect of MR-HIFU treatment on various symptoms in more detail, as well as to perform a long-term follow-up to address symptom recurrences and reinterventions, as well as the cost-effectiveness of MR-HIFU. We also aim to study more closely correlations of technical success or patient-related factors to the reduction of the symptoms.

## 5 | CONCLUSION

MR-HIFU can offer rapid and sustainable symptom relief for selected symptomatic fibroid patients. In our study, the severity of fibroid-related symptoms had significantly reduced at 3 and 12 months, while quality of life had increased. In addition, the treatment can be offered to women planning future pregnancies, as no negative effect on future fertility or pregnancy has been reported.<sup>11,26</sup> In the future, the sustained nature of the treatment response must be confirmed, and further tools for predicting treatment success need to be developed.

## AUTHOR CONTRIBUTIONS

Saara Otonkoski was the main author, participated in recruiting the patients, and collecting and analyzing the data. Antti Viitala was responsible for statistical analysis, revised the paper, and approved the version to be published. Gaber Komar was the radiologist responsible for conducting the MR-HIFU treatments, collected the data, revised the paper, and approved the version to be published. Teija Saino was the physicist conducting the MR-HIFU treatments and participating in collecting and analyzing the data. Anna Yanovskiy was the radiologist participating in collecting and analyzing the data. Roberto Blanco Sequieros contributed to the design of the research and approved the version to be published. Antti Perheentupa contributed to the design of the research, revised the paper, and approved the version to be published. Kirsi Joronen contributed to the design of the research, recruited the patients, participated in the interpretation of the data, revised the paper, and approved the final version to be published.

## FUNDING INFORMATION

Funding was received from the Government Research Foundation of Finland.

## CONFLICT OF INTEREST STATEMENT

The authors report that there are no competing interests to declare.

## ETHICS STATEMENT

This study was registered at [clinicaltrials.gov](https://clinicaltrials.gov) (NCT03937401) and was performed in accordance with the ethical regulations of the Ethics Committee of the Hospital District of Southwest Finland and the National Committee on Medical Research Ethics (T366/2017; January 25, 2018).

## ORCID

Saara Otonkoski  <https://orcid.org/0000-0002-7873-1204>

Antti Perheentupa  <https://orcid.org/0000-0002-1413-6414>

Kirsi Joronen  <https://orcid.org/0000-0002-5527-8371>

## REFERENCES

- Havryliuk Y, Setton R, Carlow JJ, Shaktman BD. Symptomatic fibroid management: systematic review of the literature. *JLS*. 2017;21:e2017.00041.
- Stewart E, Cookson C, Gandolfo R, Schulze-Rath R. Epidemiology of uterine fibroids: a systematic review. *BJOG*. 2017;124:1501-1512.
- Yang Q, Ciebiera M, Bariani MV, et al. Comprehensive review of uterine fibroids: developmental origin, pathogenesis, and treatment. *Endocr Rev*. 2022;43:678-719.
- Giuliani E, As-Sanie S, Marsh EE. Epidemiology and management of uterine fibroids. *Int J Gynecol Obstet*. 2020;149:3-9.
- Laughlin-Tommaso S, Barnard EP, Abdelmagied AM, et al. FIRSTT study: randomized controlled trial of uterine artery embolization vs focused ultrasound surgery. *Am J Obstet Gynecol*. 2019;220:174.e1-174.e13.
- Gizzo S, Saccardi C, Patrelli TS, et al. Magnetic resonance-guided focused ultrasound myomectomy. *Reprod Sci*. 2014;21:465-476.
- Laughlin-Tommaso SK. Non-surgical management of myomas. *J Minim Invasive Gynecol*. 2018;25:229-236.
- Mailli L, Patel S, Das R, et al. Uterine artery embolisation: fertility, adenomyosis and size—what is the evidence? *CVIR Endovasc*. 2023;6:8.
- Yan L, Huang H, Lin J, Yu R. High-intensity focused ultrasound treatment for symptomatic uterine fibroids: a systematic review and meta-analysis. *Int J Hyperth*. 2022;39:230-238.
- Otonkoski S, Sainio T, Mattila S, et al. Magnetic resonance guided high intensity focused ultrasound for uterine fibroids and adenomyosis has no effect on ovarian reserve. *Int J Hyperth*. 2023;40:2154575.
- Anneveldt KJ, Van't Oever HJ, Nijholt IM, et al. Systematic review of reproductive outcomes after high intensity focused ultrasound treatment of uterine fibroids. *Eur J Radiol*. 2021;141:109801.
- Mindjuk I, Trumm CG, Herzog P, Stahl R, Matzko M. MRI predictors of clinical success in MR-guided focused ultrasound (MRgFUS) treatments of uterine fibroids: results from a single centre. *Eur Radiol*. 2015;25:1317-1328.
- Sainio T, Saunavaara J, Komar G, et al. Feasibility of apparent diffusion coefficient in predicting the technical outcome of MR-guided high-intensity focused ultrasound treatment of uterine fibroids—a comparison with the Funaki classification. *Int J Hyperth*. 2021;38:85-94.
- Spies JB, Coyne K, Guaou G, Boyle D, Skyrnarz-Murphy K, Gonzalves SM. The UFS-QOL, a new disease-specific symptom and health-related quality of life questionnaire for leiomyomata. *Obstet Gynecol*. 2002;99:290-300.

- Otonkoski S, Sainio T, Komar G, et al. Oxytocin selectively reduces blood flow in uterine fibroids without an effect on myometrial blood flow: a dynamic contrast enhanced MRI evaluation. *Int J Hyperth*. 2020;37:1293-1300.
- Turku-HIFU-Research-Centre. *Turku University Hospital HIFU Research Center Treatment Outcome Analysis Scripts—12 Month Follow-Up*. <https://github.com/Turku-HIFU-Research-Centre/Turku-HIFU-data-analysis-12-month-follow-up-publication>
- Al-Hendy A, Myers ER, Stewart E. Uterine fibroids: burden and unmet medical need. *Semin Reprod Med*. 2017;35:473-480.
- Hakkarainen J, Nevala A, Tomás E, et al. Decreasing trend and changing indications of hysterectomy in Finland. *Acta Obstet Gynecol Scand*. 2021;100:1722-1729.
- Liu L, Wang T, Lei B. High-intensity focused ultrasound (HIFU) ablation versus surgical interventions for the treatment of symptomatic uterine fibroids: a meta-analysis. *Eur Radiol*. 2022;32:1195-1204.
- Maclean JA, Hayashi K. Progesterone actions and resistance in gynecological disorders. *Cells*. 2022;11:647.
- Sandberg EM, Tummers FHMP, Cohen SL, van den Haak L, Dekkers OM, Jansen FW. Reintervention risk and quality of life outcomes after uterine-sparing interventions for fibroids: a systematic review and meta-analysis. *Fertil Steril*. 2018;109:698-707.e1.
- Verpalen IM, Anneveldt KJ, Nijholt IM, et al. Magnetic resonance-high intensity focused ultrasound (MR-HIFU) therapy of symptomatic uterine fibroids with unrestricted treatment protocols: a systematic review and meta-analysis. *Eur J Radiol*. 2019;120:108700.
- Qin S, Lin Z, Liu N, Zheng Y, Jia Q, Huang X. Prediction of postoperative reintervention risk for uterine fibroids using clinical-imaging features and T2WI radiomics before high-intensity focused ultrasound ablation. *Int J Hyperth*. 2023;40:2226847.
- Verpalen IM, de Boer JP, Linstra M, et al. The Focused Ultrasound Myoma Outcome Study (FUMOS); a retrospective cohort study on long-term outcomes of MR-HIFU therapy. *Eur Radiol*. 2020;30:2473-2482.
- Anneveldt KJ, Nijholt IM, Schutte JM, et al. Comparison of (cost-) effectiveness of magnetic resonance image-guided high-intensity-focused ultrasound with standard (minimally) invasive fibroid treatments: protocol for a multicenter randomized controlled trial (MYCHOICE). *JMIR Res Protoc*. 2021;10:e29467.
- Ji J, Liu J, Chen Y, Liu X, Hao L. Analysis of high intensity focused ultrasound in treatment of uterine fibroids on ovarian function and pregnancy outcome. *J Clin Ultrasound*. 2022;50:202-208.

## SUPPORTING INFORMATION

Additional supporting information can be found online in the Supporting Information section at the end of this article.

**How to cite this article:** Otonkoski S, Viitala A, Komar G, et al. Magnetic resonance guided high intensity focused ultrasound (MR-HIFU) effectively reduces fibroid-related symptoms and improves quality of life—A prospective single-centre 12-month follow-up study. *Acta Obstet Gynecol Scand*. 2025;104:1172-1180. doi:[10.1111/aogs.15086](https://doi.org/10.1111/aogs.15086)