



## RESEARCH ARTICLE

WILEY

# Brain lesion locations associated with secondary seizure generalization in tumors and strokes

Janne Nordberg<sup>1,2</sup>  | Frederic L. W. V. J. Schaper<sup>3</sup> | Marco Bucci<sup>4,5</sup> |  
Lauri Nummenmaa<sup>6</sup> | Juho Joutsa<sup>1,2,6,7</sup> 

<sup>1</sup>Department of Clinical Neurophysiology, Turku University Hospital and University of Turku, Turku, Finland

<sup>2</sup>Turku Brain and Mind Center, Clinical Neurosciences, University of Turku, Turku, Finland

<sup>3</sup>Center for brain circuit therapeutics, Brigham and Women's Hospital and Harvard Medical School, Boston, Massachusetts, USA

<sup>4</sup>Theme Inflammation and Aging, Karolinska University Hospital, Stockholm, Sweden

<sup>5</sup>Division of Clinical Geriatrics, Center for Alzheimer Research, Department of Neurobiology, Care Sciences and Society, Karolinska Institutet, Stockholm, Sweden

<sup>6</sup>Turku PET Centre, Turku University Hospital, Turku, Finland

<sup>7</sup>Neurocenter, Turku University Hospital, Turku, Finland

## Correspondence

Juho Joutsa, Turku Brain and Mind Center, Medisiina A1, 20014 University of Turku, Email: [jjout@utu.fi](mailto:jjout@utu.fi)

## Funding information

Finnish Medical Foundation; Turku University Hospital

## Abstract

Structural brain lesions are the most common cause of adult-onset epilepsy. The lesion location may contribute to the risk for epileptogenesis, but whether specific lesion locations are associated with a risk for secondary seizure generalization from focal to bilateral tonic-clonic seizures, is unknown. We identified patients with a diagnosis of adult-onset epilepsy caused by an ischemic stroke or a tumor diagnosed at the Turku University Hospital in 2004–2017. Lesion locations were segmented on patient-specific MR imaging and transformed to a common brain atlas (MNI space). Both region-of-interest analyses (intersection with the cortex, hemisphere, and lobes) and voxel-wise analyses were conducted to identify the lesion locations associated with focal to bilateral tonic-clonic compared to focal seizures. We included 170 patients with lesion-induced epilepsy (94 tumors, 76 strokes). Lesions predominantly localized in the cerebral cortex (OR 2.50, 95% C.I. 1.21–5.15,  $p = .01$ ) and right hemisphere (OR 2.22, 95% C.I. 1.17–4.20,  $p = .01$ ) were independently associated with focal to bilateral tonic-clonic seizures. At the lobar-level, focal to bilateral tonic-clonic seizures were associated with lesions in the right frontal cortex (OR 4.41, 95% C.I. 1.44–13.5,  $p = .009$ ). No single voxels were significantly associated with seizure type. These effects were independent of lesion etiology. Our results demonstrate that lesion location is associated with the risk for secondary generalization of epileptic seizures. These findings may contribute to identifying patients at risk for focal to bilateral tonic-clonic seizures.

## KEYWORDS

astrocytoma, epilepsy, infarction, seizure generalization, seizures

## 1 | INTRODUCTION

Epilepsy is the fourth most common neurological disease, affecting over 40 million people of all ages worldwide (Collaborators GE, 2019; Fiest et al., 2017). Brain lesions are the most common cause of adult-onset epilepsy (Thurman et al., 2019). Although almost all brain lesions

can cause epilepsy, some types of lesions, such as infiltrating tumors, are more prone to cause epilepsy than other types, such as stroke (Kerkhof & Vecht, 2013; Thurman et al., 2019). Clinical risk factors for lesion-induced epilepsy vary depending on the lesion etiology but on a patient level it is challenging to predict which lesions are likely to

This is an open access article under the terms of the [Creative Commons Attribution-NonCommercial-NoDerivs](https://creativecommons.org/licenses/by-nc-nd/4.0/) License, which permits use and distribution in any medium, provided the original work is properly cited, the use is non-commercial and no modifications or adaptations are made.

© 2023 The Authors. *Human Brain Mapping* published by Wiley Periodicals LLC.

cause epilepsy and which are not (Chang et al., 2008; Pitkänen et al., 2016).

Lesion location has been suggested to play a role in the development of lesional epilepsy (Chang et al., 2008; Kerkhof & Vecht, 2013; Pitkänen et al., 2016). In general, lesions in the cerebral cortex are associated with a higher risk for epilepsy than lesions in other parts of the brain (Kerkhof & Vecht, 2013; Pitkänen et al., 2016; Wang, Qian, et al., 2015; Zhang et al., 2014). In stroke, lesions in the anterior circulation area are associated with an increased risk for late seizures and epilepsy compared to strokes in the posterior circulation (Pitkänen et al., 2016; Zhang et al., 2014). In gliomas, tumor locations in the temporal and frontal lobe have been linked to an increased risk of seizures. However, there is no clear consensus between studies (Cayuela et al., 2018; Kerkhof & Vecht, 2013; Lee et al., 2010; Wang, Qian, et al., 2015). Given that focal seizures can theoretically arise from any brain region, the fact that we cannot pinpoint to a single brain region associated with seizures across lesion etiologies is not surprising.

Lesion-induced epilepsy is considered to cause focal epileptic activity, which in some patients spreads to other brain regions outside the focus and may eventually lead to bilateral tonic-clonic seizures (focal to bilateral tonic-clonic seizure, FBTCS) (Brodovskaya & Kapur, 2019). Secondary seizure generalization in FBTCS involves cortical spreading of epileptic activity to both hemispheres and is hypothesized to include spread to subcortical brain regions including the thalamus, basal ganglia and cerebellum (Blumenfeld et al., 2009). Disturbances in the thalamo-cortical loops and basal ganglia have been shown to be the underlying mechanism for generalization of focal seizures (Caciagli et al., 2020; He et al., 2020; Yang et al., 2017) and there is evidence that seizure onset region is associated with risk for seizure generalization (e.g., seizures originating from the frontal lobe seem to generalize more often compared to seizures originating from the medial temporal lobes [Kaufmann et al., 2020]), and gliomas affecting the corpus callosum are associated with seizure spread (Wiesmann et al., 2015). However, data-driven voxel-based lesion-symptom mapping studies investigating the brain regions most strongly associated with FBTCSs across the whole brain are scarce (Wiesmann et al., 2015). FBTCSs are associated with a loss in quality of life (Collaborators GE, 2019), a high risk of injury (Lawn et al., 2004), and an increased risk for sudden unexpected death in epilepsy (SUDEP) (Devinsky et al., 2016; Hesdorffer et al., 2011; Langan et al., 2005). Identifying lesion locations associated with increased risk for FBTCSs may help to identify these patients at an early stage in treatment and benefit patient-specific epilepsy management. Moreover, characterizing lesion locations associated with FBTCSs may provide valuable information about the brain regions involved in secondary seizure generalization (Brodovskaya & Kapur, 2019).

The aim of this study was to investigate if lesion locations are associated with FBTCSs across stroke and astrocytoma, two common lesion etiologies associated with epilepsy. Using both a-priori-region of interest analyses and data-driven voxel-wise analyses, we compared lesion locations of patients with FBTCSs to patients with focal seizures only.

## 2 | MATERIALS AND METHODS

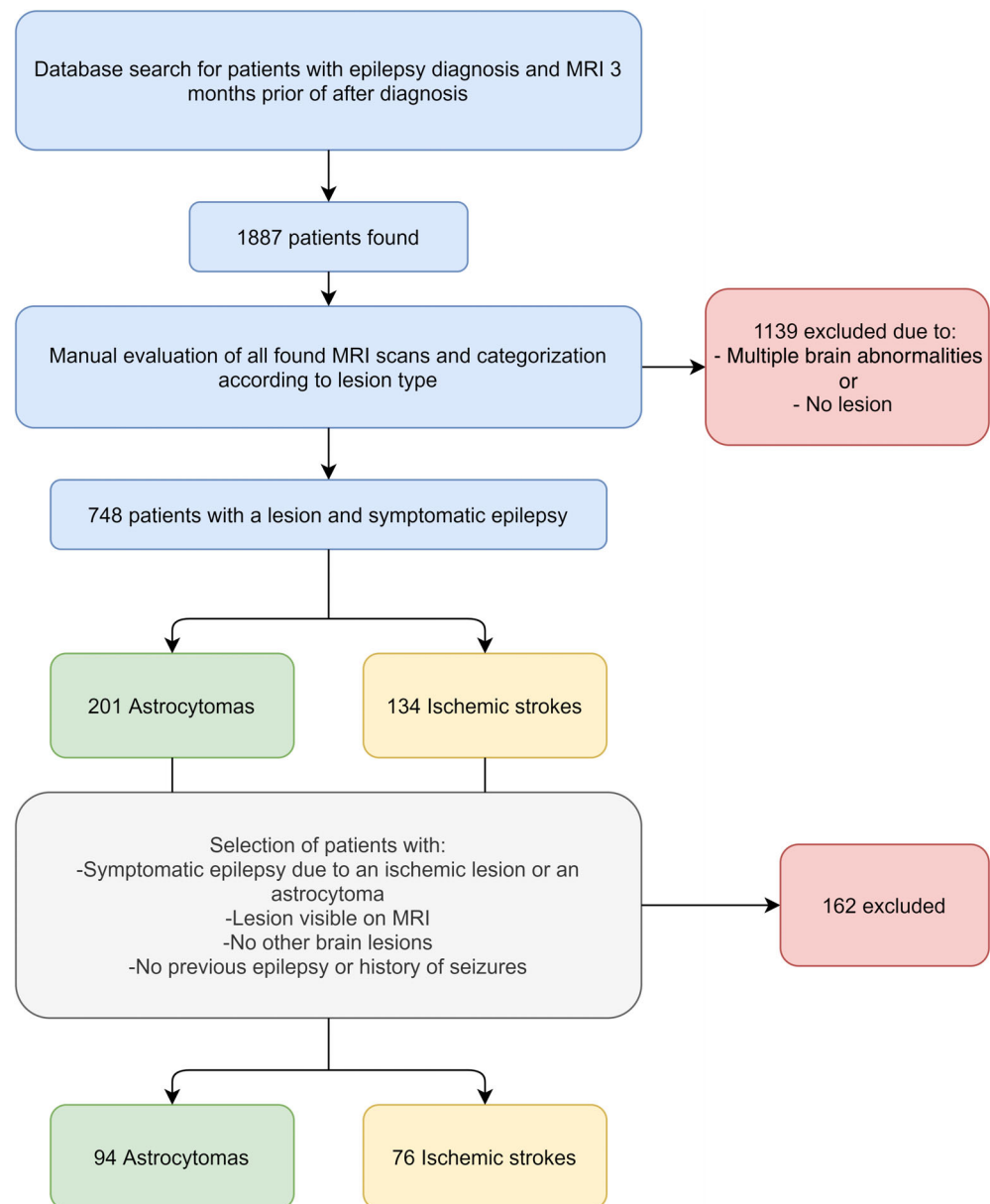
### 2.1 | Patient selection

Patients with lesion-induced epilepsy were identified from clinical records between 2004 and 2017 at Turku University Hospital, Turku, Finland. A systematic database search for patients with age  $>/-18$  years (adult-onset) with diagnosis of symptomatic epilepsy (International Classification of Diseases 10, ICD-10 codes: G40.00, G40.01, G40.09, G40.10, G40.11, G40.12, G40.19, G40.20, G40.21, G40.22 and G40.29) and brain MRI obtained up to  $+/-3$  months from the diagnosis of epilepsy was conducted. A relatively short interval between the epilepsy diagnosis and brain MRI was chosen to minimize the possibility of additional brain lesions or other confounding factors after the occurrence of the lesion. This initial search identified 1887 patients who were selected for a detailed clinical record review to identify cases with new-onset epilepsy, as detailed below.

The case selection is illustrated in Figure 1. The clinical diagnoses and seizure types were retrieved from the hospital records. All epilepsy diagnoses were established at the department of neurology at the Turku University Hospital, which is the tertiary care hospital of the Southwest Finland. All relevant clinical records including neuroimaging and clinical neurophysiology examination results and clinical follow up were evaluated by the investigators. Out of 1887 cases evaluated, 748 were confirmed to have focal brain lesions and epilepsy according to the current International League Against Epilepsy (ILAE) definitions (Fisher et al., 2017). To ensure we did not include any patients without lesion-induced epilepsy, patients who did have enough information in the hospital records to confirm the diagnosis were excluded. To be able to investigate generalizability of the findings across lesion etiologies, we selected the two most common etiologies in our dataset into this study (astrocytoma [ $n = 201$ ] and ischemic stroke [ $n = 134$ ]). These cases were selected for a detailed review of the clinical records, including brain imaging and neurophysiological data, to identify patients to the present study. All astrocytomas were pathologically confirmed by neuropathologists at the Turku University Hospital as part of the clinical routine.

Stroke sample: The inclusion criteria were: (i) age at least 18 years old at the time of first seizure (ii) late seizures consistent with symptomatic epilepsy caused by an ischemic stroke, (iii) one or more ischemic focal stroke lesions in the MRI, (iv) no other brain lesions or structural abnormalities, (v) no history of epileptic seizures prior to the stroke. Cases with diagnostic uncertainty whether they had focal-onset epilepsy or unclear etiology of epilepsy were excluded. In total, 76 patients fulfilled all criteria and were included in the study (Figure 1).

Tumor sample: The inclusion criteria were: (i) age at least 18 years old at the time of first seizure (ii) symptomatic epilepsy caused by an astrocytoma, (iii) one or more tumors with identifiable borders in the MRI, (iv) no other brain lesions or structural abnormalities, (v) no history of epileptic seizures prior to the astrocytoma diagnosis. Cases with diagnostic uncertainty whether they had focal-onset epilepsy,

**FIGURE 1** Case selection

unclear etiology of epilepsy or evidence of metastases were excluded. In total, 94 patients fulfilled the inclusion criteria (Figure 1).

## 2.2 | Clinical phenotyping

Demographical and clinical data from the selected patients were obtained based on a detailed review of the medical records. Lesion etiology, sex, age at diagnosis, age at first seizure, age at discovery of the lesion, seizure semiology, EEG findings, number of antiepileptic drugs (AEDs), presence of seizures at best AED therapy (in tumors before any surgery) and status epilepticus episodes were retrieved from the clinical records. In addition, tumor grade (I-IV) was extracted for patients with astrocytomas.

Time of occurrence of the lesion was defined as the time of first symptoms for stroke in the stroke sample and first brain scan showing

the lesion in the tumor sample. The epilepsy types were classified to focal only (focal aware or focal impaired awareness [at least one seizure with impaired awareness]), and FBTCS (at least one generalized seizure) in accordance with the current ILAE classification (Fisher et al., 2017; Scheffer et al., 2017).

## 2.3 | Lesions

Brain lesions were manually drawn on the high-field (1.5 T or 3 T) MR images obtained as part of the clinical work up in the subjects' native space using FSLeves software [version 0.31.2, (Jenkinson et al., 2001)]. All slices in the T1 or T2w sequence were examined, and the lesion was approximated on each slice in all three planes. Nonlesioned voxels were assigned value 0 and lesioned voxels value 1, producing a three-dimensional binary lesion mask. The individual

MRI was then transformed to the MNI152 standard space using FMRIB's linear image registration tool (FLIRT) implemented in FSL (Greve & Fischl, 2009; Jenkinson et al., 2002; Jenkinson & Smith, 2001). Nonlinear registration was not used because structural lesions may affect the gross brain anatomy, leading to bias when using other commonly used nonlinear transformations. Nearest-neighbor interpolation was used to preserve dichotomous voxel classification (lesioned vs. not lesioned voxels). The manually drawn lesion mask was registered to MNI152 standard space using the registration matrix obtained from the transformation of the anatomical image to MNI space. The alignment of the transformed images and resulting localization of the lesion in MNI space were visually inspected and manually edited to ensure accurate anatomical localization of the lesion. Lesion masks were used in both the region-of-interest analyses and voxel-wise analyses.

## 2.4 | Regions-of-interest

A cerebral cortex mask was defined by combining all cortical regions in the Harvard-Oxford Cortical Structural Atlas with 0.25 threshold (Desikan et al., 2006). Cortical versus subcortical involvement was evaluated by quantifying the number of lesion voxels intersecting with the cerebral cortex mask and dividing the number of cortical voxels with the total lesion volume. Lesions with at least half of the voxels located in the cerebral cortex were defined as predominantly cortical lesions. Lesion laterality was evaluated visually using the lesion masks. With bilaterally extending lesions, the hemisphere with the majority of voxels was defined as the predominant side of the lesion.

Lobar regions-of-interest (ROIs) were defined in the right and left hemisphere separately to the frontal, parietal, occipital and temporal lobe using the Harvard-Oxford Cortical Structural Atlas by combining all cortical subregions within each lobe. Lesioned voxels in each ROI were calculated and predominantly involved lobe was defined as the lobe with highest number of lesioned voxels.

## 2.5 | Statistical analyses

Differences in demographical and clinical characteristics between samples and epilepsy types were compared using independent samples *t*-test or Mann-Whitney U-test (continuous variables) and Chi-Square or Fisher Exact test (categorical variables), as appropriate.

Differences in lesion location (laterality and cortical involvement) between cases with focal versus FBTCs in the whole sample were investigated using Chi-Square or Fisher Exact test, as appropriate. In addition, the degree of cortical involvement (percentage of the voxels located in the cerebral cortex) was compared between the groups using independent samples *t*-test. Finally, a binary logistic regression analysis with seizure type as the dependent variable, and predominant side, cortical involvement and lesion type as independent variables was conducted to study if these factors were independently associated with seizure generalization.

To localize the findings within the hemisphere at lobar-level, ROI analyses were conducted by comparing the number of voxels in each lobe between patients with focal only and FBTCs using Mann-Whitney U tests because the highly skewed distribution of the numbers of voxels in each lobe. Bonferroni correction was used to control for increased type I error due to four lobes included in the analysis. The other hemisphere was used as a negative control to verify the hemispheric specificity of the findings. Independence of the total lesion size was investigated by repeating the analysis with percentages of voxels in an ROI of total number of lesion voxels, and independence of etiology by repeating the analysis in strokes and tumors separately. Finally, the proportions of patients with FBTCs in patients with lesions predominantly involving the identified lobe versus other brain regions were compared using Fisher's Exact test, and the clinical relevance of the significant findings was quantified by calculating odds ratio for FBTCs for the identified lobe compared to all other lesions using binary logistic regression controlling for lesion type.

## 2.6 | Voxel-based lesion symptom mapping

Voxelwise lesion locations in patients with focal versus FBTCs were compared using voxel-based lesion symptom mapping (VLSM) in both datasets combined. VLSM was conducted using NiiStat software (<https://github.com/neurolabusc/NiiStat>) according to the published recommendations (Karnath et al., 2017). Lesion etiology and lesion size were used as nuisance covariates. The analyses were conducted across the whole brain in voxels affected in at least 5% ( $n \geq 9$ ) of the cases and confirmed with thresholds of at least 10% ( $n \geq 17$ ) and  $n \geq 1$ . Statistical significance was set at  $p < .05$  corrected for family-wise error (FWE) using Freedman-Lane permutation with 2000 permutations. The main analysis was repeated in strokes and tumors separately to identify any etiology-dependent effects.

## 2.7 | Ethics statement

The study protocol was approved by Turku University Hospital Clinical Research Services Board, and the study was conducted according to the principles of the Declaration of Helsinki. Due to the retrospective register-based nature of the clinical data collection and large sample size, the need for separate ethical board review and obtaining written consent from the patients was waived.

# 3 | RESULTS

## 3.1 | Demographics and lesions

The demographical and clinical data of the lesion samples are presented in Table 1. There were no differences in the proportion of patients with FBTCs between etiologies (Table 1). In patients with

**TABLE 1** Demographical and clinical data

	Total (n = 170)	Tumors (n = 94)	Strokes (n = 76)	p-value
Sex (Male: Female)	89:81	50:44	39:37	.88
Age at Diagnosis (y)	55.9 (17.0)	47.8 (15.9)	65.9 (13.1)	<.001
Age at First seizure (y)	54.4 (17.0)	47.1 (16.0)	63.3 (13.7)	<.001
Age at Lesion discovery (y)	53.0 (17.0)	47.1 (16.1)	61.0 (14.6)	<.001
Delay from Lesion to seizure (days)	462 (1490)	127 (612)	978 (2162)	<.001
Follow-up period (y)	8.2 (2.8)	9.4 (2.8)	6.7 (2.0)	<.001
(range)	3.3–14.8	4.0–14.8	3.3–13.7	
Seizure type				
FBTCSs	102 (60.0%)	57 (60.6%)	45 (59.2%)	.88
Focal seizures only	68 (40.0%)	37 (39.4%)	31 (40.8%)	
Focal aware	41 (24.1%)	30 (31.9%)	11 (14.5%)	<.001
Focal impaired awareness	27 (15.9%)	7 (7.4%)	20 (26.3%)	
EEG finding				
Normal	52 (30.6%)	29 (30.9%)	23 (30.3%)	.01
Epileptiform	35 (20.6%)	10 (10.6%)	25 (32.9%)	
Focal slowing	49 (28.8%)	29 (30.9%)	20 (26.3%)	
NA	34 (20.0%)	26 (27.7%)	8 (10.5%)	
Status epilepticus at any time				
No	145 (85.3%)	84 (89.4%)	61 (80.3%)	.10
Yes	25 (14.7%)	10 (10.6%)	15 (19.7%)	
Seizures on best AED therapy				
None	45 (26.5%)	30 (31.9%)	15 (19.7%)	.10
Yes	122 (71.8%)	64 (68.1%)	58 (76.3%)	
NA	3 (1.8%)	0 (0.0%)	3 (3.9%)	
Number of AEDs in use				
None	2 (1.2%)	0 (0.0%)	2 (2.6%)	.43
1	152 (89.4%)	86 (91.5%)	66 (86.8%)	
2	14 (8.2%)	7 (7.4%)	7 (9.2%)	
3	2 (1.2%)	1 (1.1%)	1 (1.3%)	

Note: As the delay from lesion to seizure in tumors is calculated based on the discovery the lesion, the true delay is likely to be longer. Mean (SD) or number of subjects (proportion of the respective sample) are shown in the table.

Abbreviations: AED, antiepileptic drug; FBTCS, focal to bilateral tonic-clonic seizure; NA, not available.

focal seizures only, seizures with impaired awareness were more common in strokes compared to tumors (Table 1). Focal slowing in EEG was more common in strokes compared to tumors (Table 1). The groups with or without EEG did not differ in seizure type ( $p = .85$ ), lesion laterality ( $p = .34$ ), or proportion of cortical lesions ( $p = .17$ ) or right frontal lesions ( $p = .43$ ). Stroke patients were older and had a longer delay between the discovery of the lesion and onset of seizures compared to tumor patients (Table 1).

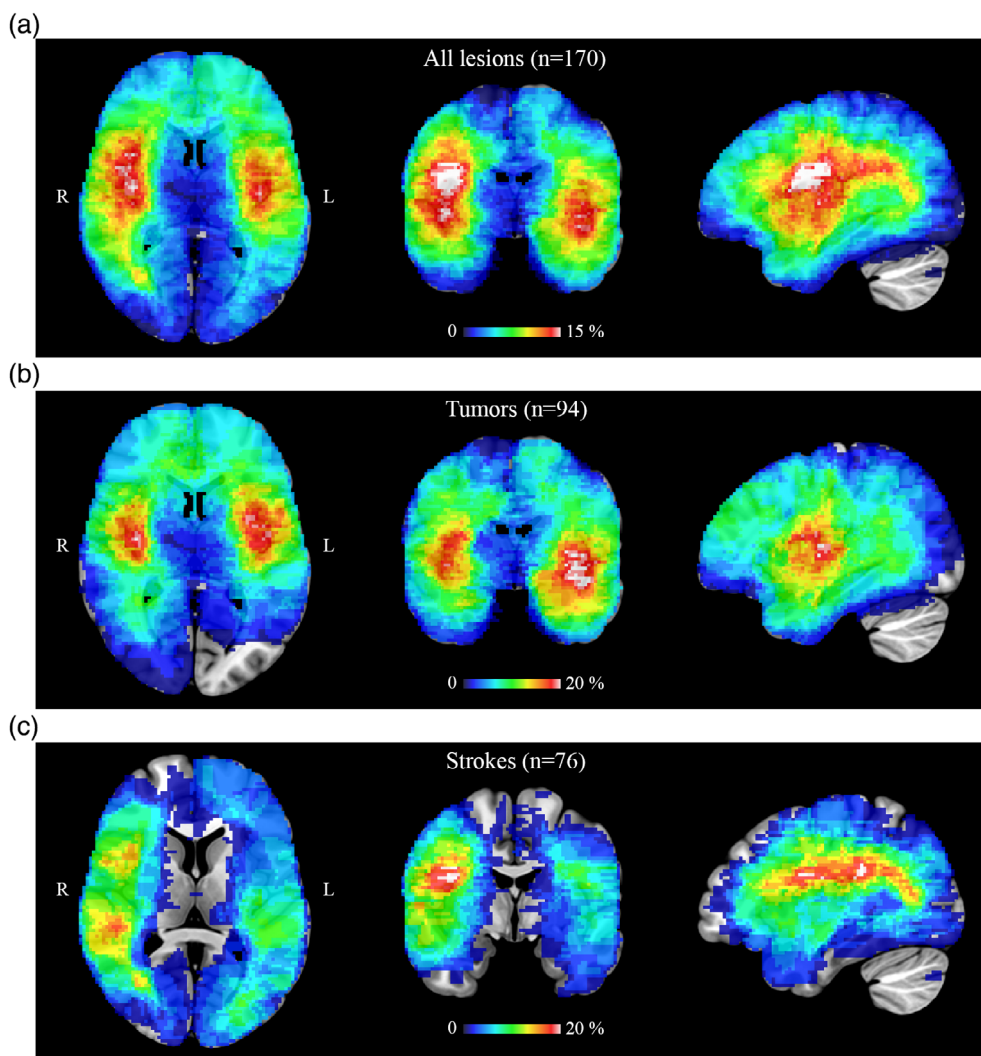
Lesion locations were heterogeneously distributed across the brain (Figure 2a) with tumors preferentially localizing to the basal ganglia, insula, temporal lobes and frontal lobes (Figure 2b), and strokes to the regions supplied by the middle cerebral artery (Figure 2c).

Patients with FBTCSs were slightly younger compared to patients with focal seizures only but there were no other significant

differences between the groups in demographic or clinical characteristics (Table 2). Demographic data according to the seizure type for the stroke and tumor samples separately are available in the supplementary material (Table S1 and S2, respectively).

### 3.2 | Regions-of-interest analyses

FBTCSs were more common in patients with lesions predominantly localized to the cerebral cortex compared to subcortical lesions (65.3% vs. 44.2%,  $p = .01$ , Figure 3a), and the right hemisphere compared to the left (68.5% vs. 50.6%,  $p = .02$ , Figure 3b). The mean (SD) proportion of voxels of the lesion in the cerebral cortex was 62.0% (19.8) in lesions associated with FBTCSs and 54.9% (22.7) in lesions associated with focal seizures only ( $p = .03$ ). The laterality



**FIGURE 2** Lesion overlap. Lesion overlap in (a) the whole sample ( $n = 170$ ), (b) tumor sample ( $n = 94$ ) and (c) stroke sample ( $n = 76$ ). The maximum overlap of lesions at any voxel was 18.8%, 28.7% and 23.6% of the sample, respectively.

effect remained significant when excluding 21 patients with bilateral lesions from the analysis (68.3% vs. 51.4%,  $p = .04$ ). In the logistic regression analysis, both predominantly cortical (OR 2.50, 95% C.I. 1.21–5.15,  $p = .01$ ) and right-sided lesions (OR 2.22, 95% C.I. 1.17–4.20,  $p = .01$ ) were independently associated with FBTCs, while lesion etiology was not ( $p = 1.0$ ). There were no significant interaction effects between predominantly cortical lesion location, lesion laterality and cortical involvement. Adding age at lesion discovery to the regression model did not change the significance of the effects. There were also no differences in the proportion of predominantly cortical (79.6% vs. 69.7%,  $p = .14$ ) or right-sided lesions (51.1% vs. 53.9%,  $p = .71$ ) between tumors and strokes.

In the lobar ROI analyses, lesions associated with FBTCs involved the right frontal cortex more than lesions associated with focal seizures only (corrected  $p = .02$ , Table S3). There were no significant differences between the seizure types in other lobes in the right or in any of the lobes in the left hemisphere (Table S3). The involvement of the right frontal lobe was also significant when accounting for age at lesion discovery ( $p = .01$ ), age at epilepsy diagnosis ( $p = .01$ ) or lesion size ( $p = .006$ ), and when analyzing strokes ( $p = .048$ ) and tumors ( $p = .03$ ) separately. Lesions predominantly located in the

right frontal cortex were associated with FBTCs (OR 4.41, 95% C.I. 1.44–13.5,  $p = .009$ ) compared to lesions located in other regions independent of lesion etiology ( $p = .96$ ) (Figure 3c). There also was no significant interaction effect between lesion type and location in the right frontal cortex ( $p = .46$ ). The numbers of predominantly involved ROIs are shown in Table S4.

### 3.3 | Voxel-based lesion symptom mapping

The results from the voxelwise VLSM analyses showed clear right-lateralization of lesion locations associated with FBTCs (Figure 3d, Figure S1). However, the VLSM analysis did not identify any single voxels significantly associated with FBTCs (Figure 3d).

## 4 | DISCUSSION

Our findings confirm and extend the previous observations of the association between lesion location and secondary generalization of focal seizures (FBTCs) by precisely delineating the lesion location and

**TABLE 2** Demographic and clinical data according to the seizure type

	Focal (n = 68)	FBTCS (n = 102)	p-value
Sex (Male: Female)	37:31	57:45	.49
Age at Diagnosis (y)	58.5 (16.2)	54.1 (17.8)	.10
Age at First seizure (y)	57.0 (16.1)	52.5 (17.4)	.08
Age at Lesion discovery (y)	58.5 (16.1)	54.1 (17.8)	.10
Delay from Lesion to seizure (days)	245 (773)	595 (1785)	.73
Follow-up period (y)	8.4 (2.8)	8.0 (2.8)	.31
(range)	4.1–14.8	3.3–14.8	
<b>Lesion type</b>			
Tumor	37 (54.4%)	57 (55.9%)	.87
Stroke	31 (45.6%)	45 (44.1%)	
<b>Lesion characteristics</b>			
Size (cm <sup>3</sup> )	72.1 (73.9)	79.8 (85.2)	.54
Laterality (right-sided)	28 (41.2%)	61 (59.8%)	.02
Cortical	44 (65.7%)	83 (81.4%)	.02
<b>EEG finding</b>			
Normal	21 (30.9%)	31 (30.4%)	.44
Epileptiform	17 (25.0%)	18 (17.6%)	
Focal slowing	17 (25.0%)	32 (31.4%)	
NA	13 (19.1%)	21 (20.6%)	
<b>Status epilepticus at any time</b>			
No	61 (89.7%)	84 (82.4%)	.27
Yes	7 (10.3%)	18 (17.6%)	
<b>Seizures on best AED therapy</b>			
None	19 (27.9%)	26 (25.5%)	.86
Yes	48 (70.6%)	74 (72.5%)	
NA	1 (1.5%)	2 (2.0%)	
<b>Number of AEDs in use</b>			
None	2 (2.9%)	0 (0.0%)	.25
1	60 (88.2%)	92 (90.2%)	
2	6 (8.8%)	8 (7.8%)	
3	0 (0.0%)	2 (2.0%)	

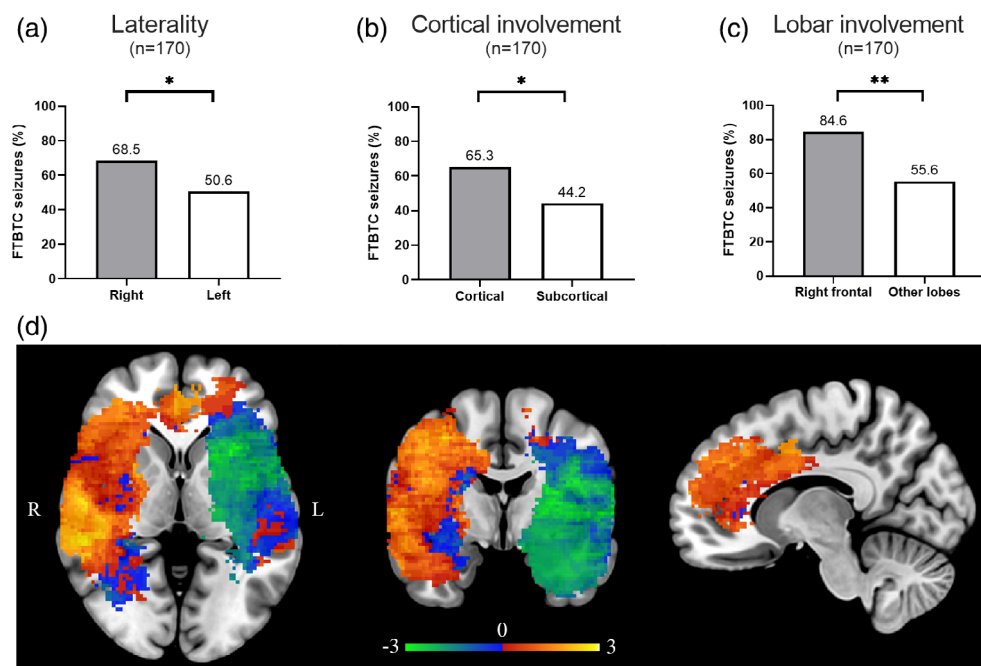
Note: As the delay from lesion to seizure in tumors is calculated based on the discovery the lesion, the true delay is likely to be longer. Mean (SD) or number of subjects (proportion of the respective sample) are shown in the table.

Abbreviations: AED, antiepileptic drug; FBTCS, focal to bilateral tonic-clonic seizure; NA, not available.

using data-driven methods such as voxel-based lesion-symptom mapping (Caciagli et al., 2020; He et al., 2020; Kaufmann et al., 2020; Yang et al., 2017). Lesions in the cerebral cortex and right hemisphere, specifically in the right frontal cortex, are associated with an increased risk for FBTCSs. These effects were independent of lesion etiology. However, lesions associated with FBTCSs did not localize to any single anatomical region within the right frontal cortex, which is in agreement with the current views that seizure generalization is a multifactorial process involving widespread brain regions rather than localized to a single hub in the brain (Blumenfeld et al., 2009; Brodovskaya & Kapur, 2019).

Previous lesion mapping studies in epilepsy have mainly focused on identification of clinical risk factors for epilepsy and crude

anatomical localization of brain regions associated with seizures and epilepsy (Camilo & Goldstein, 2004; Pitkänen et al., 2016; Zhang et al., 2014). Across etiologies, lesions in the cerebral cortex are associated with a higher risk for epileptic seizures compared to subcortical lesions, for example, basal ganglia and cerebellum (Kerkhof & Vecht, 2013; Pitkänen et al., 2016; Wang, Qian, et al., 2015; Zhang et al., 2014). In stroke, lesions in the anterior circulation are associated with increased late seizure risk but result of more detailed localization into which lobes are associated with an increased risk for late seizure have been negative or inconsistent between studies (Bladin et al., 2000; Galovic et al., 2018; Heuts-van Raak et al., 1996; Lamy et al., 2003; Leone et al., 2009). Studies investigating seizure risk in brain tumors have linked increased seizure risk to varying brain



**FIGURE 3** Lesion locations associated with focal to bilateral tonic-clonic seizures (FBTCS). Proportion of patients with FBTCSs according to the predominant side of the lesion (a), predominantly cortical/subcortical lesion location, and involvement of the right frontal lobe (c). Voxel-lesion symptom mapping (VLSM) z map showing brain regions associated with FBTCSs (red-yellow scale) and focal seizures (blue-green scale) (d). The sagittal section is from the right hemisphere. There were no voxels significantly associated with the seizure type when corrected for multiple comparisons in the whole search volume.

regions, including the medial temporal and frontal lobes (Cayuela et al., 2018; Chang et al., 2008; Lee et al., 2010; Wang, Qian, et al., 2015). However, there is no consensus on which brain regions are most susceptible for the development of lesion-induced epileptic seizures across etiologies.

Subcortical structures such as the thalamus, basal ganglia and cerebellum have been linked to seizure control, propagation, and secondary generalization in FBTCS. For example, depth recordings of both the thalamus and striatum have shown seizure activity during focal to bilateral tonic clonic seizures (Aupy et al., 2019). Functional neuroimaging studies have also shown changes in activity in the basal ganglia and cerebellum (Blumenfeld et al., 2009). The epilepsy network may thus include both cortical and subcortical structures that could function as initiators, propagators and modulators of seizure activity (Aupy et al., 2019; He et al., 2020).

The present study focused on identifying lesion locations associated with secondary seizure generalization rather than epileptic seizures per se. In line with clinical observations, our results show that cortical lesions increase the risk for FBTCSs, adding to the current knowledge that cortical lesions are more prone to cause any type of seizures (Camilo & Goldstein, 2004; Pitkänen et al., 2016; Zhang et al., 2014). Cortical lesions could contribute to the risk of seizure generalization in multiple ways. Greater lesion burden in the cerebral cortex may increase the amount of brain tissue with reduced seizure threshold, causing more widespread or multifocal discharges, or making it easier for epileptic activity to spread from cortical region to another, eventually leading to secondary generalization to FBTCSs (Blumenfeld et al., 2009; Schindler et al., 2007). Cortical lesions may also lead to a disconnection and loss of cortical control over spontaneous oscillations of subcortical hubs, such as the thalamus, which is known to generate synchronous abnormal neuronal activity in generalized seizures (Blumenfeld et al., 2009; Brodovskaya & Kapur, 2019; Fogerson & Huguenard, 2016; Paz et al., 2013).

Surprisingly, lesion laterality to the right hemisphere was an independent risk factor for FBTCSs in the present study. This finding is consistent with an increased risk of epilepsy with right-sided strokes (Galovic et al., 2018) and tumors (Lee et al., 2010), but the mechanism is unclear. One possibility may be that the left hemisphere is more epileptogenic and may have a lower seizure threshold (Holmes et al., 2001). A seizure focus in the right hemisphere may therefore more easily generalize to the left, resulting in secondary seizure generalization. A different possibility may be that, due to the involvement of eloquent areas, a seizure focus in the left hemisphere is likely to be detected and treated earlier, resulting in a suppression of secondary seizure generalization in the left hemispheric lesion group. However, with the methods of the current study, we are unable to distinguish ‘why’ right sided lesions are more likely to lead to secondary generalization and further mechanistic studies are needed.

The results of our ROI analysis indicated that lesions specifically in the right frontal cortex carry a particularly high risk for secondary generalization. This finding is in line with clinical observations that frontal lobe epilepsy is associated with a high prevalence of secondary generalized seizures (Baud et al., 2015; Laskowitz et al., 1995). However, similarly to many other studies (Bladin et al., 2000; Chang et al., 2008; Galovic et al., 2018; Heuts-van Raak et al., 1996; Lamy et al., 2003; Lee et al., 2010; Leone et al., 2009; Wang, Yu, et al., 2015), we did not identify any single common hub within the frontal cortex that, when lesioned, would be significantly associated with epileptic seizures. There are only very few previous studies analyzing the lesion location in a voxel-wise manner and comparing patients with FBTCSs to focal seizures. The results from these studies indicate that gliomas involving the corpus callosum (Wiesmann et al., 2015) or premotor cortex (Wang, Qian, et al., 2015) could increase risk for FBTCSs, but these findings have not been replicated or confirmed in other studies including the present study.

Patients with FBTCs were slightly younger compared to patients with focal seizures only. This is in line with previous observations that younger age is associated with increased risk for late-onset seizures (Fernandez-Baca Vaca et al., 2018; Pitkänen et al., 2016), and could be explained by slow neuroplastic changes, which are known to be more pronounced in younger individuals (Wolpaw, 2012). However, age was not independently associated with seizure generalization in the present study and adding age to the regression model did not change the significance of the lesion laterality or cortical location effects. Future studies are needed to investigate potential differences in lesion locations with early- and late-onset lesion-induced epilepsy.

The strengths of the present study include a focus on seizure generalization and detailed lesion localization by only including patients with high-quality, modern brain MRI with a clearly identifiable focal lesions without mass effects. The analyses were conducted by using several approaches, including a region of interest analyses of crude lesion localization (cortical-subcortical, right-left hemisphere, lobes) and a whole brain voxelwise analysis to identify specific brain regions. Our study was also not restricted to single lesion etiology but included two clinically different lesion types to identify brain regions, which could be important for secondary generalization across etiologies.

There are however some limitations that should be considered when interpreting the results of the present study. First, although our findings indicate that lesion-based localization of FBTCs are independent on lesion etiology, our analyses were limited to only two but clearly different types of lesions (ischemic strokes, astrocytomas). To what extent these findings generalize to across all etiologies, remains to be investigated in subsequent studies. Second, this was a retrospective study and may thus be subject to detection bias since information was retrieved from medical records and may have potentially been based on heterogeneous examinations performed by multiple academic neurologists. We have attempted to minimize this bias by carefully re-evaluating case histories, and all imaging and electrophysiological data. Nevertheless, detection bias may still be present. For example, patients may not report FBTCs because of fearing losing a job or driver's license or FBTCs could have occurred late after the follow up. However, incorrect characterization of seizures is unlikely to lead to systematic bias in lesion locations between the groups. Third, it is possible that our sample size may not have been sufficient to identify associations between lesions to individual brain regions and seizure generalization. Future studies including a larger collection of post-stroke and tumor-related epilepsy or more advanced lesion mapping techniques may find an association between seizure generalization and a specific lesion location. However, if present, such weak associations are likely to have only limited significance in clinical practice. Finally, delineation of lesions is inherently associated with some degree of uncertainty which can lead to errors in lesion locations. However, any inaccuracy in lesion definition would lead to increased noise in the data, biasing us against the present findings.

In conclusion, brain lesions localizing to the right frontal cortex are associated with increased risk for secondary seizure generalization in patients with lesion-induced epilepsy. Our findings can help to better identify patients at risk for FBTCs.

## ACKNOWLEDGMENTS

None.

## FUNDING INFORMATION

This study was funded by the Finnish Medical Foundation and Turku University Hospital (ERVA funds). In addition, Juho Joutsa has received research funding from the Finnish Foundation for Alcohol Studies, Finnish Parkinson Foundation, Sigrid Juselius Foundation, and University of Turku.

## CONFLICT OF INTEREST STATEMENT

The authors report no relevant conflicts of interest. Janne Nordberg, Marco Bucci and Lauri Nummenmaa have nothing to report. Juho Joutsa has received conference travel support from Abbvie and Abbott, and lecturer honoraria from Lundbeck.

## DATA AVAILABILITY STATEMENT

Voxelwise maps are available upon reasonable request. The original data cannot be made publicly available.

## ORCID

Janne Nordberg  <https://orcid.org/0000-0002-2917-4341>

Juho Joutsa  <https://orcid.org/0000-0002-3457-9415>

## REFERENCES

- Aupy, J., Wendling, F., Taylor, K., Bulacio, J., Gonzalez-Martinez, J., & Chauvel, P. (2019). Cortico-striatal synchronization in human focal seizures. *Brain*, 142(5), 1282–1295. <https://doi.org/10.1093/brain/awz062>
- Baud, M. O., Vulliemoz, S., & Seeck, M. (2015). Recurrent secondary generalization in frontal lobe epilepsy: Predictors and a potential link to surgical outcome? *Epilepsia*, 56(9), 1454–1462. <https://doi.org/10.1111/epi.13086>
- Bladin, C. F., Alexandrov, A. V., Bellavance, A., et al. (2000). Seizures after stroke: A prospective multicenter study. *Archives of Neurology*, 57(11), 1617–1622. <https://doi.org/10.1001/archneur.57.11.1617>
- Blumenfeld, H., Varghese, G. I., Purcaro, M. J., Motelow, J. E., Enev, M., McNally, K. A., Levin, A. R., Hirsch, L. J., Tikofsky, R., Zubal, I. G., Paige, A. L., & Spencer, S. S. (2009). Cortical and subcortical networks in human secondarily generalized tonic-clonic seizures. *Brain*, 132(Pt 4), 999–1012. <https://doi.org/10.1093/brain/awp028>
- Brodovskaya, A., & Kapur, J. (2019). Circuits generating secondarily generalized seizures. *Epilepsy & Behavior*, 101(12), 106474. <https://doi.org/10.1016/j.yebeh.2019.106474>
- Caciagli, L., Allen, L. A., He, X., et al. (2020). Thalamus and focal to bilateral seizures: A multiscale cognitive imaging study. *Neurology*, 95(17), e2427–e2441. <https://doi.org/10.1212/WNL.0000000000010645>
- Camilo, O., & Goldstein, L. B. (2004). Seizures and epilepsy after ischemic stroke. *Stroke*, 35(7), 1769–1775. <https://doi.org/10.1161/01.STR.0000130989.17100.96>
- Cayuela, N., Simó, M., Majós, C., et al. (2018). Seizure-susceptible brain regions in glioblastoma: Identification of patients at risk. *European Journal of Neurology*, 25(2), 387–394. <https://doi.org/10.1111/ene.13518>
- Chang, E. F., Potts, M. B., Keles, G. E., Lamborn, K. R., Chang, S. M., Barbaro, N. M., & Berger, M. S. (2008). Seizure characteristics and control following resection in 332 patients with low-grade gliomas. *Journal of Neurosurgery*, 108(2), 227–235. <https://doi.org/10.3171/JNS/2008/108/2/0227>

- Collaborators GE. (2019). Global, regional, and national burden of epilepsy, 1990–2016: A systematic analysis for the global burden of disease study 2016. *Lancet Neurology*, 18(4), 357–375. [https://doi.org/10.1016/S1474-4422\(18\)30454-X](https://doi.org/10.1016/S1474-4422(18)30454-X)
- Desikan, R. S., Ségonne, F., Fischl, B., Quinn, B. T., Dickerson, B. C., Blacker, D., Buckner, R. L., Dale, A. M., Maguire, R. P., Hyman, B. T., Albert, M. S., & Killiany, R. J. (2006). An automated labeling system for subdividing the human cerebral cortex on MRI scans into gyral based regions of interest. *NeuroImage*, 31(3), 968–980. <https://doi.org/10.1016/j.neuroimage.2006.01.021>
- Devinsky, O., Hesdorffer, D. C., Thurman, D. J., Lhatoo, S., & Richerson, G. (2016). Sudden unexpected death in epilepsy: Epidemiology, mechanisms, and prevention. *Lancet Neurology*, 15(10), 1075–1088. [https://doi.org/10.1016/S1474-4422\(16\)30158-2](https://doi.org/10.1016/S1474-4422(16)30158-2)
- Fernandez-Baca Vaca, G., Mayor, C. L., Losarcos, N. G., Park, J. T., & Lüders, H. O. (2018). Epileptic seizure semiology in different age groups. *Epileptic Disorders*, 20(3), 179–188. <https://doi.org/10.1684/epd.2018.0970>
- Fiest, K. M., Sauro, K. M., Wiebe, S., Patten, S. B., Kwon, C. S., Dykeman, J., Pringsheim, T., Lorenzetti, D. L., & Jetté, N. (2017). Prevalence and incidence of epilepsy: A systematic review and meta-analysis of international studies. *Neurology*, 88(3), 296–303. <https://doi.org/10.1212/WNL.0000000000003509>
- Fisher, R. S., Cross, J. H., French, J. A., et al. (2017). Operational classification of seizure types by the international league against epilepsy: Position paper of the ILAE Commission for Classification and Terminology. *Epilepsia*, 58(4), 522–530. <https://doi.org/10.1111/epi.13670>
- Fogerson, P. M., & Huguenard, J. R. (2016). Tapping the brakes: Cellular and synaptic mechanisms that regulate thalamic oscillations. *Neuron*, 92(4), 687–704. <https://doi.org/10.1016/j.neuron.2016.10.024>
- Galovic, M., Döhler, N., Erdélyi-Canavese, B., et al. (2018). Prediction of late seizures after ischaemic stroke with a novel prognostic model (the SeLECT score): A multivariable prediction model development and validation study. *Lancet Neurology*, 17(2), 143–152. [https://doi.org/10.1016/S1474-4422\(17\)30404-0](https://doi.org/10.1016/S1474-4422(17)30404-0)
- Greve, D. N., & Fischl, B. (2009). Accurate and robust brain image alignment using boundary-based registration. *NeuroImage*, 48(1), 63–72. <https://doi.org/10.1016/j.neuroimage.2009.06.060>
- He, X., Chaitanya, G., Asma, B., et al. (2020). Disrupted basal ganglia-thalamocortical loops in focal to bilateral tonic-clonic seizures. *Brain*, 143(1), 175–190. <https://doi.org/10.1093/brain/awz361>
- Hesdorffer, D. C., Tomson, T., Benn, E., Sander, J. W., Nilsson, L., Langan, Y., Walczak, T. S., Beghi, E., Brodie, M. J., Hauser, A., & for the ILAE Commission on Epidemiology; Subcommittee on Mortality. (2011). Combined analysis of risk factors for SUDEP. *Epilepsia*, 52(6), 1150–1159. <https://doi.org/10.1111/j.1528-1167.2010.02952.x>
- Heuts-van Raak, L., Lodder, J., & Kessels, F. (1996). Late seizures following a first symptomatic brain infarct are related to large infarcts involving the posterior area around the lateral sulcus. *Seizure*, 5(3), 185–194. [https://doi.org/10.1016/s1059-1311\(96\)80034-3](https://doi.org/10.1016/s1059-1311(96)80034-3)
- Holmes, M. D., Dodrill, C. B., Kutsy, R. L., Ojemann, G. A., & Miller, J. W. (2001). Is the left cerebral hemisphere more prone to epileptogenesis than the right? *Epileptic Disorders*, 3(3), 137–141.
- Jenkinson, M., Bannister, P., Brady, M., & Smith, S. (2002). Improved optimization for the robust and accurate linear registration and motion correction of brain images. *NeuroImage*, 17(2), 825–841. [https://doi.org/10.1016/s1053-8119\(02\)91132-8](https://doi.org/10.1016/s1053-8119(02)91132-8)
- Jenkinson, M., & Smith, S. (2001). A global optimisation method for robust affine registration of brain images. *Medical Image Analysis*, 5(2), 143–156. [https://doi.org/10.1016/s1361-8415\(01\)00036-6](https://doi.org/10.1016/s1361-8415(01)00036-6)
- Karnath, H. O., Sperber, C., & Rorden, C. (2017). Mapping human brain lesions and their functional consequences. *NeuroImage*, 165, 180–189. <https://doi.org/10.1016/j.neuroimage.2017.10.028>
- Kaufmann, E., Seethaler, M., Lauseker, M., Fan, M., Vollmar, C., Noachtar, S., & Rémi, J. (2020). Who seizes longest? Impact of clinical and demographic factors. *Epilepsia*, 61(7), 1376–1385. <https://doi.org/10.1111/epi.16577>
- Kerckhof, M., & Vecht, C. J. (2013). Seizure characteristics and prognostic factors of gliomas. *Epilepsia*, 54(Suppl 9), 12–17. <https://doi.org/10.1111/epi.12437>
- Lamy, C., Domigo, V., Semah, F., Arquizan, C., Trystram, D., Coste, J., Mas, J. L., & Patent Foramen Ovale and Atrial Septal Aneurysm Study Group. (2003). Early and late seizures after cryptogenic ischemic stroke in young adults. *Neurology*, 60(3), 400–404. <https://doi.org/10.1212/wnl.60.3.400>
- Langan, Y., Nashef, L., & Sander, J. W. (2005). Case-control study of SUDEP. *Neurology*, 64(7), 1131–1133. <https://doi.org/10.1212/01.WNL.0000156352.61328.CB>
- Laskowitz, D. T., Sperling, M. R., French, J. A., & O'Connor, M. J. (1995). The syndrome of frontal lobe epilepsy: Characteristics and surgical management. *Neurology*, 45(4), 780–787. <https://doi.org/10.1212/wnl.45.4.780>
- Lawn, N. D., Bamlet, W. R., Radhakrishnan, K., O'Brien, P. C., & So, E. L. (2004). Injuries due to seizures in persons with epilepsy: A population-based study. *Neurology*, 63(9), 1565–1570. <https://doi.org/10.1212/01.wnl.0000142991.14507.b5>
- Lee, J. W., Wen, P. Y., Hurwitz, S., Black, P., Kesari, S., Drappatz, J., Golby, A. J., Wells, W. M., Warfield, S. K., Kikinis, R., & Bromfield, E. B. (2010). Morphological characteristics of brain tumors causing seizures. *Archives of Neurology*, 67(3), 336–342. <https://doi.org/10.1001/archneurol.2010.2>
- Leone, M. A., Tonini, M. C., Bogliun, G., Gionco, M., Tassinari, T., Bottacchi, E., & Beghi, E. (2009). Risk factors for a first epileptic seizure after stroke: A case control study. *Journal of the Neurological Sciences*, 277(1–2), 138–142. <https://doi.org/10.1016/j.jns.2008.11.004>
- Paz, J. T., Davidson, T. J., Frechette, E. S., Delord, B., Parada, I., Peng, K., Deisseroth, K., & Huguenard, J. R. (2013). Closed-loop optogenetic control of thalamus as a tool for interrupting seizures after cortical injury. *Nature Neuroscience*, 16(1), 64–70. <https://doi.org/10.1038/nn.3269>
- Pitkänen, A., Roivainen, R., & Lukasiuk, K. (2016). Development of epilepsy after ischaemic stroke. *Lancet Neurology*, 15(2), 185–197. [https://doi.org/10.1016/S1474-4422\(15\)00248-3](https://doi.org/10.1016/S1474-4422(15)00248-3)
- Scheffer, I. E., Berkovic, S., Capovilla, G., et al. (2017). ILAE classification of the epilepsies: Position paper of the ILAE Commission for Classification and Terminology. *Epilepsia*, 58(4), 512–521. <https://doi.org/10.1111/epi.13709>
- Schindler, K., Leung, H., Lehnertz, K., & Elger, C. E. (2007). How generalised are secondarily "generalised" tonic clonic seizures? *Journal of Neurology, Neurosurgery, and Psychiatry*, 78(9), 993–996. <https://doi.org/10.1136/jnnp.2006.108753>
- Thurman, D. J., Faught, E., Helmers, S., Kim, H., & Kalilani, L. (2019). New-onset lesional and nonlesional epilepsy in the US population: Patient characteristics and patterns of antiepileptic drug use. *Epilepsy Research*, 157, 106210. <https://doi.org/10.1016/j.eplepsyres.2019.106210>
- Wang, W., Yu, J., Liu, Y., et al. (2015). Voxel-based meta-analysis of grey matter changes in Alzheimer's disease. *Translational Neurodegeneration*, 4, 6. <https://doi.org/10.1186/s40035-015-0027-z>
- Wang, Y., Qian, T., You, G., Peng, X., Chen, C., You, Y., Yao, K., Wu, C., Ma, J., Sha, Z., Wang, S., & Jiang, T. (2015a). Localizing seizure-susceptible brain regions associated with low-grade gliomas using voxel-based lesion-symptom mapping. *Neuro-Oncology*, 17(2), 282–288. <https://doi.org/10.1093/neuonc/nou130>
- Wieshmann, U. C., Milinis, K., Paniker, J., das, K., Jenkinson, M. D., Brodbelt, A., Crooks, D., & Keller, S. S. (2015). The role of the corpus

- callosum in seizure spread: MRI lesion mapping in oligodendrogliomas. *Epilepsy Research*, 109, 126–133. <https://doi.org/10.1016/j.eplepsyres.2014.10.023>
- Wolpaw, J. R. (2012). Harnessing neuroplasticity for clinical applications. *Brain*, 135(4), e215. <https://doi.org/10.1093/brain/aws017>
- Yang, L., Li, H., Zhu, L., et al. (2017). Localized shape abnormalities in the thalamus and pallidum are associated with secondarily generalized seizures in mesial temporal lobe epilepsy. *Epilepsy & Behavior*, 70, 259–264. <https://doi.org/10.1016/j.yebeh.2017.02.011>
- Zhang, C., Wang, X., Wang, Y., Zhang, J. G., Hu, W., Ge, M., Zhang, K., & Shao, X. (2014). Risk factors for post-stroke seizures: A systematic review and meta-analysis. *Epilepsy Research*, 108(10), 1806–1816. <https://doi.org/10.1016/j.eplepsyres.2014.09.030>

## SUPPORTING INFORMATION

Additional supporting information can be found online in the Supporting Information section at the end of this article.

**How to cite this article:** Nordberg, J., Schaper, F. L. W. V. J., Bucci, M., Nummenmaa, L., & Joutsa, J. (2023). Brain lesion locations associated with secondary seizure generalization in tumors and strokes. *Human Brain Mapping*, 1–11. <https://doi.org/10.1002/hbm.26268>